

Mucormycosis in a Diabetic Ketoacidosis Patient: A Case Report

SIDDANAGOUDA BIRADAR¹, SHIVRAJ N PATIL², DEEPAK KADELI³

ABSTRACT

Mucormycosis is the name given to several different diseases caused by fungi of the order mucorales. It is commonly seen in patients with decreased immunity like patients with chronic renal failure, organ transplantation, neutropenia and most commonly in those with poorly controlled diabetes. We present a case of 55-year-old diabetic man who presented with headache and fever diagnosed with pulmonary and maxillary sinus mucormycosis presenting as diabetic ketoacidosis.

Keywords: Mucoraceae, Opportunistic infection, Pulmonary cavity

CASE REPORT

A 55-year-old male presented to the hospital with fever and cough since the past one week. The fever was on and off with intermittent headache. He had been diagnosed with diabetes mellitus (DM) five years back for which he had taken oral hypoglycaemic which he discontinued after four months and has been on herbal therapy since.

On admission the patient was afebrile (36.4degree), his pulse rate was 100 beats per minute and BP of 120/70 mmHg. Physical examination was normal, on auscultation of chest occasional coarse crepitations were found and rest of the systems was normal. Laboratory investigations revealed haemoglobin of 16.8 g/dL, total white blood cell of 28000 cells per cumm (80% neutrophil) and ESR of 50mm in first hour. Serum biochemistry showed creatinine 2.3mg/dL, blood glucose level was 374 mg/dL, sodium 131 mmol/L, potassium 4.7 mmol/L. Urine analysis revealed a 1.5% glucose, ketone bodies, and albumin 2+. Chest radiograph showed left upper lobe homogenous opacity suggesting consolidation [Table/Fig-1]. He was empirically started on ceftriaxone.

His sputum was sent for analysis which showed fungal elements on KOH mount. Diagnostic nasal endoscopy showed extensive crusts filling left nasal cavity and maxillary sinus which was suggestive of mucormycosis.

The patient was started on insulin therapy and amphotericin B intravenously at 1.5mg/kg body weight for 21 days with oral fluconazole of 150mg daily for six weeks. Renal profile was

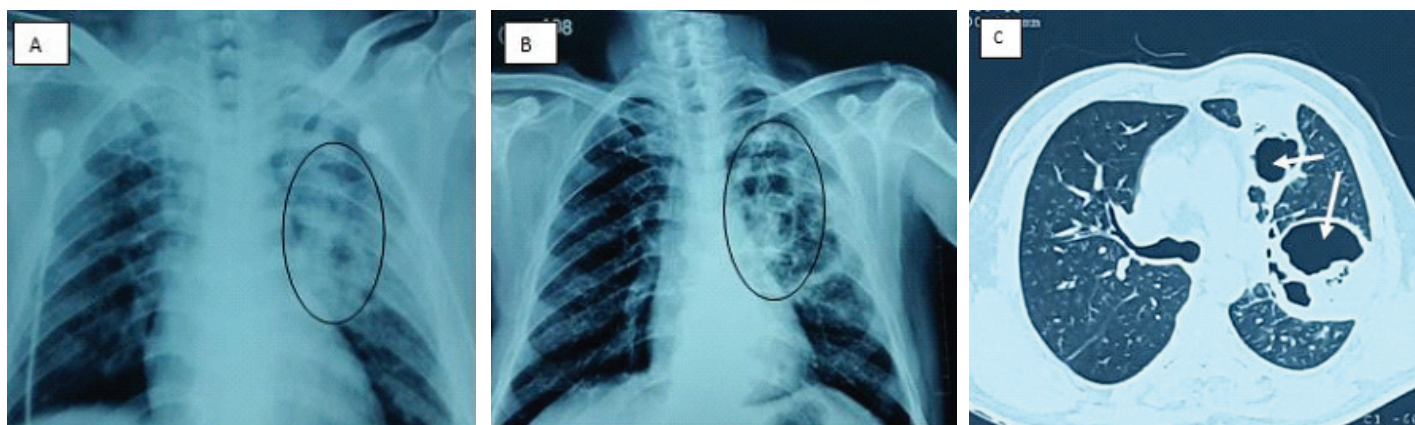
monitored every three days to check for nephrotoxicity from amphotericin. During the treatment the patient's symptoms subsided and serial chest x rays showed clearing of the left upper lobe infiltrates [Table/Fig-2]. A CT chest was done to check the extent of damage left by the cavitation [Table/Fig-3].

The patient was discharged after four weeks. The patient was asymptomatic on follow up after 45 days with normal chest X ray.

DISCUSSION

Mucormycosis is an opportunistic fungal infection caused by saprophytic fungal elements commonly found in soil, decaying materials and food. Respiratory route is the most common mode of entry to the body. The fungi have filamentous non septate hyphae, with right-angled branching [1].

These fungal elements are widely distributed in nature and are commonly found in decaying matter. Though mucormycosis can affect any part of the body it has predilection for certain organ systems. It can present as follows: disseminated, cutaneous, rhino-cerebral, pulmonary, gastrointestinal or central nervous system involvement. The predisposing disease condition determines the predilection for one of these presentations. Patients with haematological malignancies mostly develop pulmonary mucormycosis. Diabetics most often develop rhino-cerebral mucormycosis. The host response to mucorales is predominantly by neutrophils [2]. Fungal growth and proliferation is promoted by certain metabolic states like hyperglycaemia and acidosis [3]. The increased release of iron from ferritin which occurs because of acidosis causes enhanced fungal and hyphal growth [4].



[Table/Fig-1]: Chest X ray before onset of treatment shows homogenous opacities in the left upper lobe. **[Table/Fig-2]:** Chest X Ray after 20 days of treatment with amphotericin B showing clearing of opacities with remnant cavities. **[Table/Fig-3]:** Computed Tomography of chest with arrows showing multiple cavities.

The rhino-cerebral form of mucormycosis mainly occurs in patients with diabetes, particularly with the complication of DM such as ketoacidosis where the acid base balance is altered. The usual presentation includes local manifestations like facial pain which later progress to systemic manifestations like headache, fever, and mental obtundation [4]. The typical presentation of pulmonary mucormycosis is the presence of blood tinged sputum or frank haemoptysis.

As seen in case report of Vijaybala GS et al., fatal cases are encountered rarely caused by massive haemoptysis [5]. The mucorales cause necrosis of the bronchial wall from where they invade the pulmonary vessel wall causing rupture of these vessels into the necrotic bronchi causing asphyxiation [6]. Pulmonary mucormycosis commonly involves the upper lobes, which have a better aeration providing apt environment for the proliferation of mucorales.

Mucormycosis is usually not encountered commonly in day to day practice hence a high index of suspicion is needed to avoid delay in diagnosis and treatment. Diagnosis of pulmonary mucormycosis is usually missed and in fatal cases it is usually encountered on post mortem after pulmonary tissue sampling [7]. The diagnosis of disease is mainly based on history, high index of suspicion, diagnostic imaging and biopsy. Most of the sputum cultures turn negative, but a positive culture is highly suggestive. Diagnosis can be definitively confirmed after demonstrating tissue invasion and necrosis with characteristic hyphae which are septate with right angle branching [4].

Mucormycosis does not have a specific pattern of radiological examination and presents with non specific features like; consolidation, cavitary lung lesion and pleural effusion. The most common radiologic findings on chest imaging is consolidation (66%), cavitation occurs in about 40% and usually after resolution of neutrophil function and their number like in our patient, radiologic manifestation primarily presented with pleural effusion followed by cavitation after treatment of ketoacidosis [8]. Then mucormycosis can also be in a differential diagnosis of other cavitary pulmonary lesion [9].

Over the years intravenous amphotericin B and surgical debridement has been the mainstay of treatment. Most of patients with endobronchial form of mucormycosis are diabetic and may benefit from early aggressive surgical resection of involved lung tissue [1]. Teder et al., showed that isolated pulmonary mucormycosis has 65% mortality, but in disseminated form mortality is up to 96% [6].

CONCLUSION

In our case the patient was not on any hypoglycaemic drugs leading to development of mucormycosis. The presentation was atypical with chest X ray suggesting consolidation. This case presses the need for high degree of suspicion for pulmonary mucormycosis in case of immunocompromised patients with nonresolving pneumonia inspite of no rhinocerebral involvement. The condition being completely curable, early diagnosis and aggressive treatment is the key between life and death.

REFERENCES

- [1] Hopkins MA, Treloar DM. Mucormycosis in diabetes. *Am J Crit Care*. 1997;6:363-67.
- [2] Lewejohann J, Muhl E, Birth M, Kujath P, Bruch HP. Pulmonary zygomycosis--a rare angioinvasive fungal infection. *Mycoses*. 2005;48(Suppl 1):99-107.
- [3] Martin-Moro JG, Calleja JM, Garcia MB, Carretero JL, Rodriguez JG. Rhinorbitocerebralmucormycosis: a case report and literature review. *Med Oral Patol Oral Cir Bucal*. 2008;13:792-95.
- [4] Mandell GL, Dolin R. Principles and Practice of Infectious Disease. 6th ed. Philadelphia: Churchill Livingstone, 2005; 125-28.
- [5] Vijayabala GS, Annigeri RG, Sudarshan R. Mucormycosis in a diabetic ketoacidosis patient. *Asian Pacific Journal of Tropical Biomedicine*. 2013;3(10):830-33. doi:10.1016/S2221-1691(13)60164-1
- [6] Mohammadi A, Mehdizadeh A, Ghasemi-Rad M, Habibpour H, Esmaeli A. Pulmonary mucormycosis in patients with diabetic ketoacidosis: a case report and review of literature. *Tuberk Toraks*. 2012;60(1):66-69.
- [7] Eucker J, Sezer O, Graf B, Possinger K. Mucormycoses. *Mycoses*. 2001;44:253-60.
- [8] McAdams HP, Rosado de Christenson M, Strollo DC, Patz EF. Pulmonary mucormycosis: radiologic findings in 32 cases. *AJR Am J Roentgenol*. 1997;168:1541-48.
- [9] Rahimi-Rad MH, Mohammadi A. Multiple bilateral traumatic pulmonary pseudocysts in a 53 year-old male diagnosed retrospectively. *Pneumologia*. 2010;59:84-86.

PARTICULARS OF CONTRIBUTORS:

1. Associate Professor, Department of General Medicine, Shri B.M. Patil Medical College, Vijayapur, Karnataka, India.
2. Post Graduate, Department of General Medicine, Shri B.M. Patil Medical College, Vijayapur, Karnataka, India.
3. Cardiology Resident, Department of Cardiology, Fortis Hospital, Cunningham Road, Bangalore, India.

NAME, ADDRESS, E-MAIL ID OF THE CORRESPONDING AUTHOR:

Dr. Siddanagouda Biradar,
Associate Professor, Department of Medicine, Shri B.M. Patil Medical College, BLDE University,
Vijayapur, Karnataka-586108, India.
E-mail: drsm_biradar@yahoo.co.in

FINANCIAL OR OTHER COMPETING INTERESTS: None.

Date of Submission: **Aug 26, 2015**

Date of Peer Review: **Sep 19, 2015**

Date of Acceptance: **Feb 09, 2016**

Date of Publishing: **May 01, 2016**