

Second Trimester Uterine Rupture: A Rare Case Report

Keval A Patil¹, Aruna S Nemagouda²

¹Postgraduate, Department of Obstetrics and Gynaecology, Shri B.M. Patil Medical College and Hospital, Bijapur, Karnataka, India,

²Assistant Professor, Department of Obstetrics and Gynaecology, Shri B.M. Patil Medical College and Hospital, Bijapur, Karnataka, India

Second trimester abortions constitute 10-15% of all induced abortions worldwide but are responsible for two-thirds of major abortion-related complications. Although spontaneous fundal rupture is very rare in the early second trimester of pregnancy, it should be taken into consideration in the differential diagnosis of per vaginal bleeding with acute abdominal pain in pregnancy if there are predisposing factors. Uterine rupture in pregnancy is rare with a high incidence of fetal and maternal morbidity. Here, we report one of the rare cases of 32-year-old women presenting with per vaginal bleeding and acute abdominal pain with second trimester uterine rupture.

Keywords: Per vaginal bleeding, Second trimester abortion, Uterine rupture

INTRODUCTION

Uterine rupture in pregnancy is rare with a high incidence of fetal and maternal morbidity. The overall incidence is low, i.e., 0.087%.¹ Second trimester abortions constitute 10-15% of all induced abortions worldwide and are responsible for two-thirds of major abortion-related complications. Although spontaneous fundal rupture is very rare in the early second trimester of pregnancy, it should be taken into consideration in the differential diagnosis of per vaginal bleeding with acute abdominal pain in pregnancy if there is a predisposing factor. It can either occur in the unscarred uterus as well as uterus with the previous scar.² Due to the non-specific signs and symptoms of uterine rupture diagnosis is difficult and sometimes delays the treatment, which increases maternal and fetal mortality and morbidity.³ Hence, a still uterine rupture in pregnancy is a feared event for medical practitioners.

CASE REPORT

A 32-year-old women Para 2, Living 2, Abortion 2 on immediate postabortal day with previous two cesarean sections and last childbirth being 7 months back reported

to labor room with history of 4 months of amenorrhea complaining of per vaginal bleeding and acute abdominal pain following medical termination of pregnancy and dilatation and evacuation showing clinical signs of shock with severe pallor and vitals were not recordable. On abdominal examination, the uterus was 16-18 weeks size and tenderness over the abdomen. Per speculum revealed active bleeding and products of conception in piece. On per vaginal examination, the anterior scar was felt and which was given away. Emergency ultrasound revealed hemoperitoneum with retained products of conception in the abdominal cavity and anteriorly fundal myometrium irregular suggestive of rupture. Routine investigations were done.

Emergency laparotomy was carried out, and it revealed hemoperitoneum due to spontaneous rupture of uterine fundus through which retained products of conception were extruded into the peritoneal cavity. About 2.5 L of blood with clots was evacuated from the abdominal cavity. Both the tubes and ovaries were normal, and peripartum subtotal hysterectomy was done. Postoperatively four packed cells were given, and the patient recovered well and discharged (Figures 1 and 2).

DISCUSSION

Medical termination is increasing and is more popular for unwanted pregnancies. Bujold *et al.*⁴ reported 4 times increase in scar rupture in subsequent pregnancy in single layer uterine closure during cesarean section compared to double layer closure. Nita *et al.*⁵ report a case of first trimester

Access this article online



www.ijsscr.com

Month of Submission : 02-2016
Month of Peer Review : 03-2016
Month of Acceptance : 03-2016
Month of Publishing : 04-2016

Corresponding Author:

Dr. Keval Patil, Department of Obstetrics and Gynaecology, Shri B.M. Patil Medical College and Hospital, Bijapur, Karnataka, India.

Phone: +91-7259135552. E-mail: patilkeval1989@yahoo.com

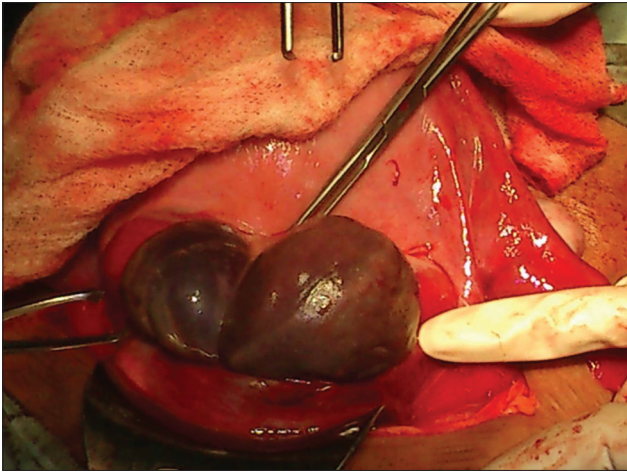


Figure 1: Intraoperative uterine rupture with blood clots

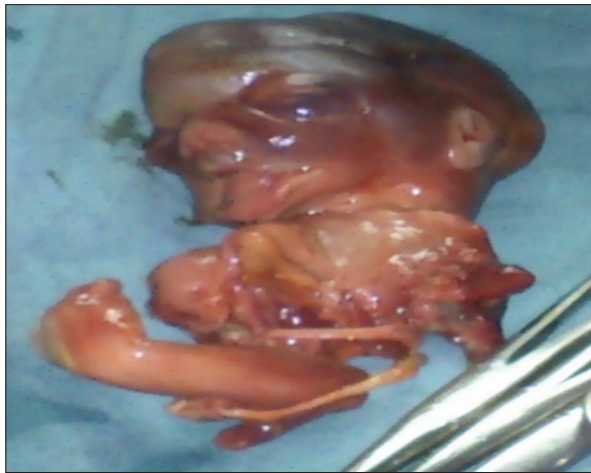

Figure 2: A 4 months abortus

spontaneous uterine rupture, so thought should be given on medical termination in women with previous cesarean

section. Although spontaneous fundal rupture is very rare in the early second trimester of pregnancy, it should be taken into consideration as differential diagnosis of per vaginal bleeding with acute abdominal pain in pregnancy if there are predisposing factors. Vigilant approach with prompt management in such cases is needed by a skilled obstetrician.

CONCLUSION

Uterine rupture is rare but poses worst obstetric complications. Efforts to reduce morbidity and mortality from uterine rupture should be focused and optimizing care for women with previous cesarean section, and also, one has to be vigilant in medical termination in women with previous cesarean section.

REFERENCES

1. Martínez-Garza PA, Robles-Landa LP, Roca-Cabrera M, Visag-Castillo VJ, Reyes-Espejel L, García-Vivanco D. Spontaneous uterine rupture: Report of two cases. *Cir Cir* 2012;80:81-5.
2. Xia X, Fan L, Xia Y, Fang Y. Uterine rupture during pregnancy. *Clin Exp Obstet Gynecol* 2011;38:286-7.
3. Fofie C, Baffoe P. A two-year review of uterine rupture in a regional hospital. *Ghana Med J* 2010;44:98-102.
4. Bujold E, Bujold C, Hamilton EF, Harel F, Gauthier RJ. The impact of a single-layer or double-layer closure on uterine rupture. *Am J Obstet Gynecol* 2002;186:1326-30.
5. Nita V, Purandare CN, Vidya B, Nikhil P. First trimester uterine rupture in previous lower segment caesarean scar. *J Obstet Gynecol India* 2011;61:88-9.

How to cite this article: Patil KA, Nemagouda AS. Second Trimester Uterine Rupture: A Rare Case Report. *IJSS Case Reports & Reviews* 2016;2(11):24-25.

Source of Support: Nil, **Conflict of Interest:** None declared.