

## Case Report

Access this article online

Quick Response Code:



Website:

[www.bldeujournalhs.in](http://www.bldeujournalhs.in)

DOI:

10.4103/2468-838X.196109

# Double profunda brachii artery

Gavishiddappa A. Hadimani, Jyoti V. Hadimani<sup>1</sup>, Ishwar B. Bagoji, Shardha Bai Rathod<sup>2</sup>, Balappa M. Bannur

### Abstract:

Brachial artery (BA) is a continuation of the axillary artery at the lower border of teres major. In the cubital fossa, BA divides into radial artery and ulnar artery as terminal branches. Large branch given from the BA in the upper part is profunda brachii artery. In the present case, we noticed double profunda brachii that arises from the BA. They are profunda brachii artery 1 and profunda brachii artery 2. Profunda brachii artery 1 arises in the proximal part of the BA and profunda brachii artery 2 arises distal to the profunda brachii artery 1. Both the arteries run inferolaterally in the spiral groove along with radial nerve. Variations of profunda brachii artery are important during harvesting of the lateral arm flaps and may lead to inadvertent injury during percutaneous arterial catheterization or injection of drugs.

### Key words:

Axillary artery, brachial artery, profunda brachii artery, triceps brachii

Axillary artery continues to brachial artery (BA) at the lower border of teres major muscle. In the cubital fossa, BA divides into radial artery and ulnar artery as terminal branches. Profunda brachii artery is the largest branch of the BA given off in the arm from the posteromedial aspect. It runs posteriorly to join the radial nerve in the radial groove where it gives rise to its deltoid branch, nutrient artery, and terminates by bifurcating into middle and radial collateral arteries.<sup>[1]</sup>

Variant origins and branching patterns have been described by Charles *et al.* in 1931.<sup>[2]</sup> Variations of profunda brachii artery are important during harvesting of the lateral arm flaps and may lead to inadvertent injury during percutaneous arterial catheterization or injection of drugs. There are case reports on the variations from different populations. The frequency and patterns of these variations display ethnic differences. Many of the cases report duplication of the profunda brachii artery from common trunk. In the present study, we have noticed double profunda brachii artery, both arises from the BA.<sup>[3-7]</sup>

artery as terminal branches. Large branch given from the BA in the upper part is profunda brachii artery. In the present case, we noticed double profunda brachii arises from the BA. They can be named as profunda brachii artery 1 and profunda brachii artery 2. Profunda brachii artery 1 arises in the proximal part of the BA and profunda brachii artery 2 arises distal to the profunda brachii artery 1. Both the arteries run inferolaterally in the spiral groove along with radial nerve [Figure 1].

Profunda brachii 1 artery gives muscular branches to medial head of triceps and continues as the radial collateral artery; small branches given from the profunda brachii artery 1 also supply the deltoid muscles. Radial collateral artery later in the middle of the arm pierces the lateral intermuscular septum and enters the anterior compartment of arm and anastomosis with radial recurrent artery in front of the lateral epicondyle.

Profunda brachii 2 artery after origin from the BA runs parallel to profunda brachii artery 1 and radial nerve; it runs in the posterior compartment of the arm that gives muscular branches to lateral

## Case Report

During the dissection classes for medical, undergraduate students, we noticed a variation in the branching pattern of BA. The variation was unilateral and observed in the spiral groove of left upper limb of a cadaver; age and gender of the cadaver were unknown.

BA as normal continues from the axillary artery at the lower border of teres major. In the cubital fossa, BA divides into radial artery and ulnar

This is an open access article distributed under the terms of the Creative Commons Attribution-NonCommercial-ShareAlike 3.0 License, which allows others to remix, tweak, and build upon the work non-commercially, as long as the author is credited and the new creations are licensed under the identical terms.

For reprints contact: [reprints@medknow.com](mailto:reprints@medknow.com)

**How to cite this article:** Hadimani GA, Hadimani JV, Bagoji IB, Rathod SB, Bannur BM. Double profunda brachii artery. BLDE Univ J Health Sci 2016;1:143-4.

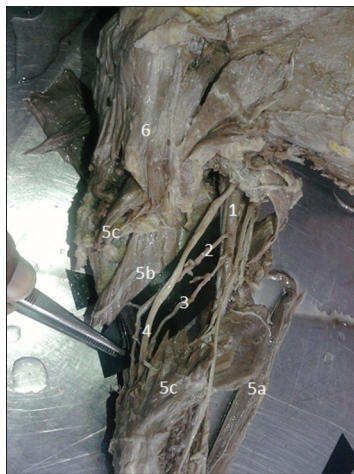
Departments of  
Anatomy and  
<sup>2</sup>Dentistry, BLDE  
University's Shri B M  
Patil Medical College,  
Hospital and Research  
Centre, Vijayapur,  
<sup>1</sup>S. S. Institute of  
Medical Sciences,  
Davangere, Karnataka,  
India

### Address for correspondence:

Dr. Gavishiddappa A.  
Hadimani,  
Department of Anatomy,  
BLDE University's Shri B  
M Patil Medical College,  
Hospital and Research  
Centre, Vijayapur,  
Karnataka, India.  
E-mail: [gavish.hadimani@yahoo.com](mailto:gavish.hadimani@yahoo.com)

Submission: 07-11-2016

Accepted: 21-11-2016



**Figure 1:** Double profunda brachii artery in the spiral groove.  
1 - Brachial artery, 2 - Profunda brachii artery 1, 3 - Profunda brachii artery 2, 4 - Radial nerve, 5a - Long head of triceps brachii muscles, 5b - Medial head of triceps brachii muscles, 5c - Cut ends of lateral head of triceps brachii muscles, 6 - Deltoid muscles

and long head of triceps and also nutrient artery to humerus; finally, it anastomosis with interosseous recurrent artery behind the lateral epicondyle.

Variations in the origin and branching pattern of the profunda brachii artery are rarely described in literature. These variations are important during harvesting of the lateral arm flaps. The incidence of duplication and early branching makes it vulnerable to inadvertent injury during fractures of the humerus, BA catheterization, and may complicate lateral arm flaps. Preoperative angiographic evaluation is therefore recommended.

## Discussion

The profunda brachii artery is the largest branch of the BA, and it shows considerable variation in its origin. As per the study by Tountans and Bergman on 55% of the cases, profunda brachii artery arises as a single trunk at the level of the tendon of the teres major muscle. It may arise from the axillary artery (in 22% cases), as a common trunk with the superior ulnar collateral artery (in 22% cases) or as a branch of the circumflex humeral artery (in 7% cases), but none of the case reported having double profunda brachii artery.<sup>[8]</sup>

Shetty *et al.* have reported the two branches of the profunda brachii; the radial collateral and the middle collateral arteries originating from a common trunk, which also gave origin to the superior ulnar collateral artery.<sup>[9]</sup> In the present study, both the profunda brachii artery arises from the BA one at proximal part of BA and second one at a point distal to the level of profunda brachii artery 1; both of them finally terminate by

supplying blood to the posterior compartment of the arm. Both the profunda brachii arteries accompany the radial nerve into the spiral groove of the humerus. In the present study, radial collateral and middle collateral arteries were the continuation of profunda brachii artery 1 and 2, respectively.

In another case report, it has been reported trifurcation of axillary artery into superficial BA, deep BA, and common subscapular arterial trunk. It was highlighted the double BA in the arm, in which profunda brachii artery was arising from the superficial BA.<sup>[10]</sup> Likewise, in the present study, we highlight double profunda brachii artery. Branches of the upper limb arteries have been used for coronary bypass and flaps in reconstructive surgery. Accurate knowledge of the normal and variant arterial pattern of the human upper extremities is important both for reparative surgery and for angiography.<sup>[11]</sup>

## Financial support and sponsorship

Nil.

## Conflicts of interest

There are no conflicts of interest.

## References

1. Standring S, Johnson D, Ellis H, Collins P. Gray's Anatomy. 39<sup>th</sup> ed. London: Churchill Livingstone; 2005. p. 356.
2. Charles CM, Pen L, Holden HF, Miller RA, Elvis EB. The origin of the deep brachial artery in American white and American Negro males. *Anat Rec* 1931;50:299-302.
3. Antohi N, Stingu C, Stan V. The use of free flap transfer in upper extremity reconstruction. *Tim Med J* 2005;1:27-35.
4. Das S, Singh S, Paul S. Double profunda brachii and abnormal branching pattern of the brachial artery. *Tim Med J* 2005;2:159-61.
5. Celik HH, Aldur MM, Tunali S, Ozdemir MB, Aktekin M. Multiple variations of the deep artery of arm: Double deep artery of arm and deep artery of arm with the superior ulnar collateral artery. A case report. *Morphologie* 2004;88:188-90.
6. Hadimani GA, Desai SD, Bagoji IB, Patil BS. Fenestration of axillary vein by a variant axillary artery. *Kathmandu Univ Med J (KUMJ)* 2013;11:162-4.
7. Madhyastha S, Nayak SR, Krishnamurthy A, D'costa S, Jose AA, Bhat KM. Case report of high origin of radial, ulnar and profunda brachii arteries, its clinical implications and review of literature. *J Vasc Bras* 2009;8:374-8.
8. Tountans CP, Bergman RA. Anatomical Variations of the Upper Extremities. New York: Churchill Livingstone; 1993. p. 197-10.
9. Shetty SD, Nayak BS, Madhav NV, Sirasanagandla SR, Abhinitha P. The abnormal origin, course and the distribution of the arteries of the upper limb: A case report. *J Clin Diagn Res* 2012;6:1414-6.
10. Bagoji IB, Hadimani GA, Bannur BM, Patil BG, Bharatha A. A unique branching pattern of the axillary artery: A case report. *J Clin Diagn Res* 2013;7:2939-40.
11. Samuel VP, Vollala VR, Nayak S, Rao M, Bolla SR, Pammidi N. A rare variation in the branching pattern of the axillary artery. *Indian J Plast Surg* 2006;39:222-3.