

Laparoscopic Management of a Renal Hydatid Cyst Masquerading as Simple Renal Cyst

Siddangouda B Patil¹, Nikhil A Patil², Vinay S Kundargi³, Ashok N Biradar⁴, Kshitij Ranka²

¹Professor and Head, Department of Urology, Shri BM Patil Medical College and Hospital, Bijapur, Karnataka, India, ²Post-graduate, Department of Urology, Shri BM Patil Medical College and Hospital, Bijapur, Karnataka, India, ³Professor, Department of Urology, Shri BM Patil Medical College and Hospital, Bijapur, Karnataka, India, ⁴Assistant Professor, Department of Urology, Shri BM Patil Medical College and Hospital, Bijapur, Karnataka, India

Hydatid cyst is a parasitic disease caused by the tapeworm *Echinococcus granulosus*. Hydatid cyst disease mostly involves the liver and the lung, while renal involvement is rare. Hydatid disease may present in unusual ways and lead to diagnostic difficulty and management problems. A high index of suspicion for hydatid disease should be maintained while evaluating complex cystic renal masses. Herein we present an interesting case who was diagnosed to have a simple renal cyst on contrast-enhanced computed tomogram, which turned out to be a renal hydatid cyst. Despite modern imaging methods, isolated renal hydatid disease might still cause diagnostic dilemma and hydatid cysts can be found in unusual localization. This case was managed laparoscopically.

Keywords: Cystic renal mass, *Echinococcus granulosus*, Hydatid cyst

INTRODUCTION

Hydatid disease is a parasitic infestation caused by *Echinococcus granulosus* that is endemic in Africa, Latin America, Mediterranean, and Turkey.¹ Humans are accidental intermediate hosts that become infected by handling of soil, dirt, or animal hair contaminated with eggs.² Kidney involvement in echinococcosis is extremely rare (2-3%), being third most common organ involved after the liver and the lungs.³ Herein we report a 28-year-old male patient who was diagnosed to have a simple renal cyst and turned out to be renal hydatid cyst which was managed laparoscopically.

routine examination was in normal limits. An ultrasound abdomen showed large well defined exophytic cyst arising from mid and lower posterolateral aspect displacing left kidney suggestive of the cortical cyst. A contrast-enhanced computed tomogram was done which showed a large cystic lesion measuring 20 cm × 16 cm in size arising from mid and lower pole of the left kidney (Figure 1). In view of patient's recurrent symptoms, he was planned for laparoscopic deroofing of the simple renal cyst. The patient was given general anesthesia with the left side elevated at 60° (Figure 2). Pneumoperitoneum was established using a veres needle and CO₂ insufflation. The cyst was demonstrated and exposed all around by blunt dissection.

CASE REPORT

A 28-year-old male patient presented with pain in the left flank region, dull aching type non-radiating since 6 months. Patients had complaints of on and off fever of moderate degree. No urinary complaints. Abdominal examination showed a bimanually palpable left flank mass, cystic in consistency. Complete hemogram and urine

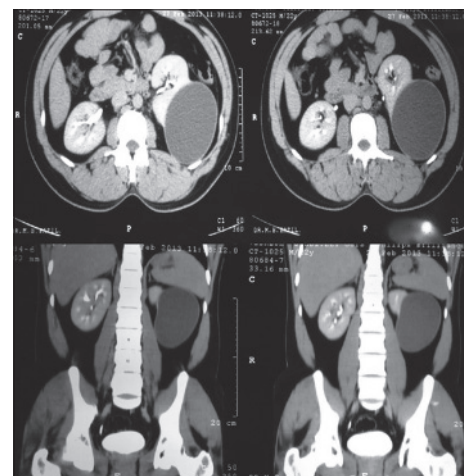


Figure 1: A contrast enhanced computed tomogram showing a large cystic lesion measuring 20 cm × 16 cm in size arising from mid to lower pole of left kidney

Access this article online



www.ijsscr.com

Month of Submission : 03-2015
 Month of Peer Review : 04-2015
 Month of Acceptance : 04-2015
 Month of Publishing : 05-2015

Corresponding Author:

Dr. Nikhil A Patil, Department of Urology, Shri BM Patil Medical College and Hospital, Bijapur, Karnataka, India. Phone: +91-9632523434. E-mail: drpatilnikhil@yahoo.com

To our surprise, there was a whitish covering over the germinal epithelium which was suggestive of hydatid cyst. To avoid contamination of the peritoneal cavity, the cyst was then isolated on all sides by packing it off using betadine-soaked gauze pieces (10% povidone iodine). The contents of the cyst were aspirated and hypertonic saline was instilled for 10 min. This was followed by cystotomy, and the endocyst was removed completely. The drain was kept in the cyst cavity. The procedure lasted for 110 min. Drain was removed on post-operative day 3 and patient discharged on day 4. The histopathological examination confirmed the diagnosis of hydatid cyst (Figure 3). Oral albendazole was given for 6 weeks. Follow-up scan at 3 and 6 months was normal.

DISCUSSION

Isolated primary renal hydatidosis is extremely rare. Renal hydatid disease mimicks other diseases.⁴ Echinococcosis is worldwide zoonoses produced by the larval stage of *E. granulosus*. Hematogenous dissemination may lead to secondary involvement of almost any anatomical

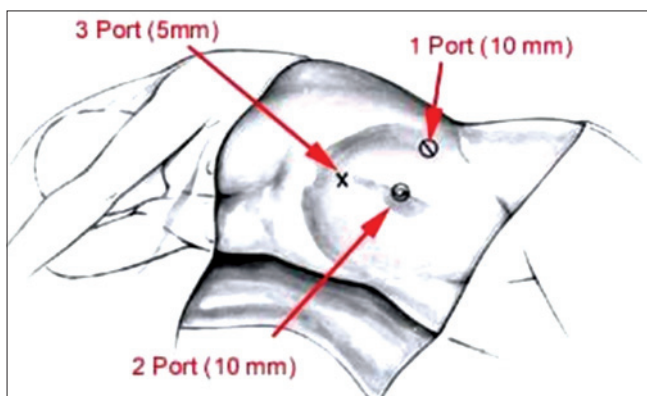


Figure 2: Image showing favorable port site and patient position. The arms are flexed and hips slightly posterior

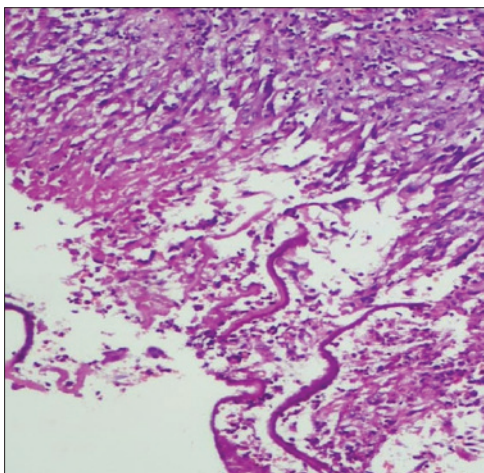


Figure 3: Histopathological image of renal parenchyma with hydatid cyst wall (H and E, ×100)

location.⁵ The combination of clinical history, imaging studies, and serological and urine investigation yielded a reliable pre-treatment diagnosis in only 50% of cases and a presumptive diagnosis in 71%. There are no classical clinical signs and symptoms except cyst rupture in the collecting system which leads to acute renal colic and hydatiduria.⁶ Radiological studies have an important place in the pre-operative diagnosis of renal hydatid disease. Imaging findings in hydatid disease depend on the stage of cyst growth. Plain films are usually non-specific and mostly non-revealing.⁷ A thin rim of calcification delineating a cyst is suggestive of an echinococcal cyst. Radiography may identify an occasional calcified cyst. Calyceal distortion is the predominant finding on intravenous pyelogram, followed by caliectasis and non-functioning kidney, possibly caused by the mass effect of cystic lesions. Computed tomogram scan is more accurate than an ultrasound.⁸

Surgery is the treatment of choice in renal hydatid cyst. Kidney-sparing surgery (cystectomy with pericystectomy) is possible in most cases (75%).⁹ Nephrectomy (25% of cases) must be reserved for destroyed kidneys. Various techniques have been advocated, which include closed total cystectomy, partial peri-cystectomy, marsupialization, capitonnage with or without omentoplasty.¹⁰ With the advent of minimal invasive techniques, laparoscopic procedures have been successfully used.¹¹ For management of renal hydatid cyst, the main concern is spillage and hence prevention of anaphylaxis. The minimal invasive techniques like Palanivelu's hydatid trocar cannula system are successfully used.¹²

Percutaneous aspiration of renal hydatid cyst under ultrasound guidance has been tried in few centres.¹³

CONCLUSION

The hydatid cyst should be a differential diagnosis for any cystic mass in the abdomen. Very few cases of laparoscopic removal of renal hydatid cyst are reported. Laparoscopic treatment can be an alternative treatment technique for renal hydatidosis therapy because of its advantages to conventional surgery if expertise is available. Prognosis is good with early diagnosis and appropriate treatment in patients with a single lesion.

REFERENCES

1. Afşar H, Yağcı F, Aybastı N, Meto S. Hydatid disease of the kidney. *Br J Urol* 1994;73:17-22.
2. Eckert J, Deplazes P. Biological, epidemiological, and clinical aspects of Echinococcosis, a zoonosis of increasing concern. *Clin Microbiol Rev* 2004;17:107-35.
3. Sarah JM, Christopher WJ, Warren DJ. Parasitic diseases of the genitourinary system. In: Wein AJ, Kavoussi LR, Novick AC,

- Partin AW, Peters CA, editors. Campbell-Walsh Urology. 9th ed. Philadelphia: Saunders; 2007. p. 458-9.
- Choi H, Park JY, Kim JH, Moon du G, Lee JG, Bae JH. Primary renal hydatid cyst: Mis-interpretation as a renal malignancy. Korean J Parasitol 2014;52:295-8.
 - Horchani A, Nouira Y, Kbaier I, Attyaoui F, Zribi AS. Hydatid cyst of the kidney. A report of 147 controlled cases. Eur Urol 2000;38:461-7.
 - Unsal A, Cimentepe E, Dilmen G, Yenidünya S, Saglam R. An unusual cause of renal colic: Hydatiduria. Int J Urol 2001;8:319-21.
 - Vargas-Serrano B, Ferreiro-Argüelles C, Rodríguez-Romero R, Marcos del Río N. Imaging findings in renal hydatid disease. Eur Radiol 1997;7:548-51.
 - Mongha R, Narayan S, Kundu AK. Primary hydatid cyst of kidney and ureter with gross hydatiduria: A case report and evaluation of radiological features. Indian J Urol 2008;24:116-7.
 - Bishoff JJ, Kavoussi LR. Laparoscopic surgery of the kidney. In: Walsh PC, Retik AB, Vaughan ED, Wein AJ, editors. Campbells Urology. 8th ed. Philadelphia: W B Saunders; 2002. p. 3645.
 - Rabii R, Mezzour MH, Essaki H, Fekak H, Joual A, Meziane F. Laparoscopic treatment for renal hydatid cyst. J Endourol 2006;20:199-201.
 - Kahriman G, Ozcan N, Donmez H. Hydatid cysts of the liver in children: Percutaneous treatment with ultrasound follow-up. Pediatr Radiol 2011;41:890-4.
 - Chipde SS, Yadav A, Ranjan P, Prakash A, Kapoor R. Total laparoscopic management of a large renal hydatid cyst by using hydatid trocar cannula system. J Surg Tech Case Rep 2012;4:32-5.
 - Goel MC, Agarwal MR, Misra A. Percutaneous drainage of renal hydatid cyst: Early results and follow-up. Br J Urol 1995;75:724-8.

How to cite this article: Patil SB, Patil NA, Kundargi VS, Biradar AN, Ranka K. Laparoscopic Management of a Renal Hydatid Cyst Masquerading as Simple Renal Cyst. IJSS Case Reports & Reviews 2015;1(12):19-21.

Source of Support: Nil, **Conflict of Interest:** None declared.