



International Journal of Medical Research & Health Sciences

www.ijmrhs.com

Volume 2 Issue 2 April - June

Codon: IJMRHS

Copyright @2013

ISSN: 2319-5886

Received: 8th Jan 2013Revised: 30th Jan 2013Accepted: 15th Feb 2013

Case report

BILATERAL ELONGATED STYLOID PROCESS: ITS ANATOMICAL EMBRYOLOGICAL AND CLINICAL IMPLICATIONS.

*Bagoji Ishwar B¹, Hadimani Gavishiddappa A¹, Patil Balasaheb G², Bannur Balappa M², Bharatha Ambadasu³.

¹Lecturer, ²Professor, Dept. of Anatomy, ³Lecturer, Dept. of Pharmacology, Sri B M Patil Medical College Hospital & Research Center, BLDE University, Bijapur, Karnataka, India.

*Corresponding author email: ishwarbagoji@gmail.com

ABSTRACT

The styloid process is a slender, elongated, cylindrical bony projection from temporal bone. It normally varies in length from 2 cm to 3 cm. During a routine demonstration of skull for MBBS students we found the bilateral elongated styloid process in dry human skull. The length of elongation measured on the right and left side was 6.0 & 5.9 cms respectively. Such abnormal elongation of the styloid process may cause compression on a number of vital vessels and nerves related to it, producing inflammatory changes that include continuous chronic pain in the pharyngeal region. Mechanical stresses stretching the second brachial arch during fetal development probably induce variable involvement of Reichert's cartilage in morphogenesis of the styloid process. It is important that clinicians especially dentists and otolaryngologists are aware of the natural variations of the styloid process and do not consider the styloid process with a length of 30 mm as an abnormality or as an anomaly.

Keywords: Styloid process, Reichert's cartilage, Eagle's syndrome

INTRODUCTION

The styloid process is a thin and sharp bone structure, protruding downward and forward from the underside of the temporal bone. It is situated between the carotid internal and external arteries, posterior to the pharynx, which cover stylohyoid, styloglossus and stylopharyngeal muscles (Gray, 1977). The normal length of styloid process is 20-25mm, between the apex of the process and lesser Cornu of hyoid bone there is attachment called as stylohyoid ligament. The tip of the process is situated laterally from the pharyngeal wall and immediately behind the

tonsillar fossa and critically between the internal and external carotid arteries and has attachment of three muscles and two ligaments. Rarely stylohyoid ligament ossifies and increase the length of the styloid process and called as the elongated styloid process when it is longer than 30mm (Monsour). The apex of the styloid process is clinically important, because it is located between internal and external carotid arteries. The facial nerve runs anterior and medial to the styloid process. The glossopharyngeal nerve exists through the

jugular foramen and curves, in close proximity under the styloid process. The accessory and vagus nerves also run medial to the styloid process. The approximation of the glossopharyngeal nerve with the stylohyoid ligament is the basis for the glossopharyngeal neurological symptoms seen in Eagle's syndrome (Eagle WW).

The elongation of styloid process is considered an anomaly which can be accompanied by calcification of the stylohyoid and stylomandibular ligaments, which can trigger a series of symptoms such as dysphasia, odynophagia, facial pain, ear pain, headache, tinnitus and trismus. This set of symptoms associated with the elongated styloid process is called Eagle's syndrome (Lages et al., 2006). Several other symptoms are attributed to the

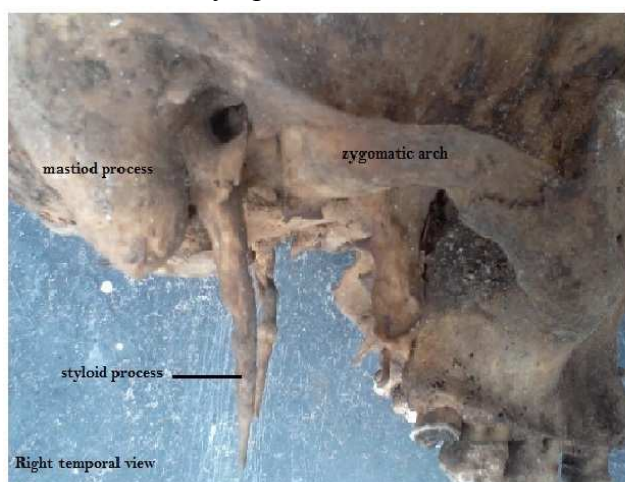


Fig:1. Showing right styloid process

DISCUSSION

Styloid process length ranges from 5 mm to 50 mm (Standring et al). The normal length of the styloid process ranges from 25 mm to 30 mm (Eagle WW). Other studies accept that a length of over 30 mm is considered elongated (Murtagh R. et al). The elongation of the SP and structural changes in stylohyoid ligament with its clinical symptoms and signs were first described by Eagle. Therefore, it is also called as the Eagle's syndrome (Eagle WW). Eagle described fully about the elongated styloid process or eagle

syndrome, including: neck pain, foreign body sensation in the throat, pain on the rotation of the head, and pain when swallowing (Guimaraes et al., 2006, Rosa et al., 2008). However none of these signs and symptoms are pathognomonic for the Eagle's syndrome (Lages et al.).

CASE REPORT

During the routine osteological study of the skull the lengths of the styloid process of both sides were measured in centimetres from the base of the skull to its tip. The lengths of both right and left styloid processes were almost the same, measuring 6.0 cm on the right side and 5.9 cm on the left side. (Figure 1&2) This length is about 150% longer than the length of a normal-sized styloid process.




Fig:2. Showing left styloid process

syndrome, in his study in ear nose throat patient and dento maxillofacial cases. Eagle studied that elongated styloid process term use only when the length of styloid process more than 30 mm or when there is stylohyoid ligament ossification. It has been suspected that an elongated styloid process could be caused by: congenital elongation of the styloid process due to the persistence of the cartilaginous analog of the Styloid (Murtagh R).

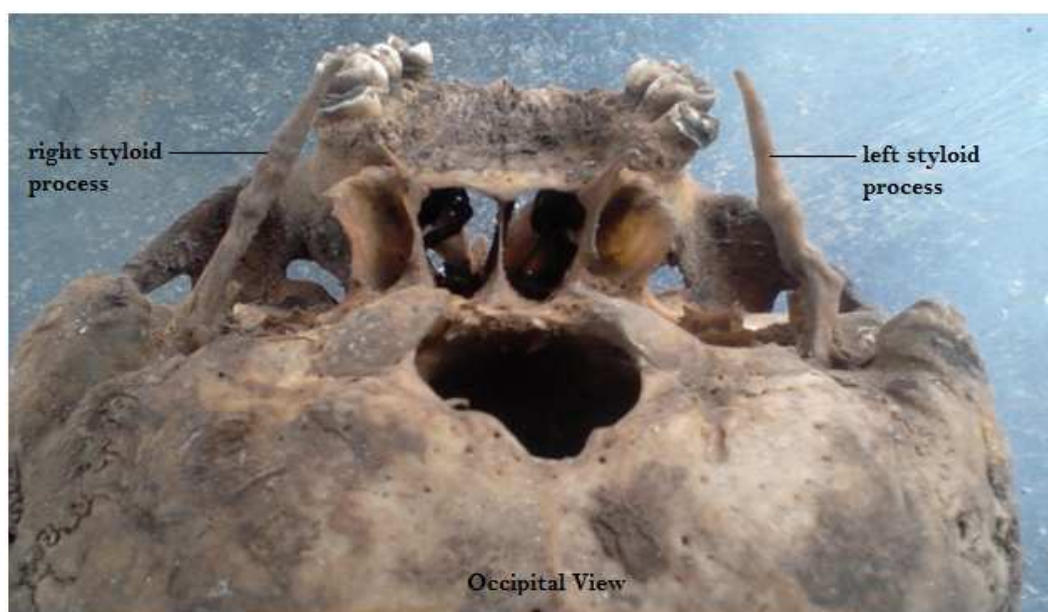

Fig 3: Occipital view showing of both right & left styloid processes.

Kouladouros et al. (2009) reported that the etiology can be explained by a genetic alteration or according to three different theories. The first theory, the hyperplastic reaction, suggests that the styloid process had been stimulated by a pharyngeal trauma leading to the ossification of the styloid ligament. The second theory, metaplastic reaction, also includes a traumatic stimulus causing multiples metaplastic alterations in the cells of the styloid ligament, which results in its total or partial ossification. The third theory, anatomic variation, suggests that the styloid process and the styloid ligament are not usually ossified, but rather, an anatomic variation.

The stylohyoid chain components are derived embryologically from the first and second branchial arches in four distinct segments: tympanohyal, stylohyal, ceratohyal and hypohyal segments. These segments are derived from Reichert's cartilages that ossify in two parts. The styloid process develops from the tympanohyal and stylohyal segments that usually fuse at puberty. The lesser horn of the hyoid bone arises from the hypohyal segment. Connecting these two structures, the stylohyoid ligament originates from the ceratohyal segment (Rodriguez et al).

CONCLUSION

The elongated styloid process is a diagnosis that should be considered in the evaluation of recurrent neck, throat or facial pain and dysphasia with or without radiation of pain to the ipsilateral ear. Eagle's syndrome is an uncommon but important cause of chronic head and neck pain. The elongated styloid process can cause craniofacial and cervical pain, difficulties in swallowing, secondary glossopharyngeal neuralgia, radiating pain into the orbit and maxillary region. Abnormal elongation of the styloid process may cause compression on a number of vital vessels and nerves related to it, producing inflammatory changes that include continuous chronic pain in the pharyngeal region, radiating otalgia, phantom foreign body sensation (Globus hystericus), pain in the pharyngeal region, and dysphasia. Awareness of the elongated styloid process is immensely important in the field of Dentistry, Otolaryngology, surgery & radiology.

ACKNOWLEDGEMENT

We thank Mr. Ekanath P Jadhav, Asst. Hospital Administrator, Sri BM Patil Medical College Hospital & Research Center, Bijapur for his constant guidance.

REFERENCES

1. Gray H. Anatomy descriptive and applied. London. Longmans, Green and Company, 1977. Pigno;
2. Monsour PA, Young WG. Variability of the styloid process & stylohyoid ligament in panoramic radiographs oral surg. Oral pathol.1986;61: 522-26
3. Eagle WW. The symptoms, diagnosis and treatment of the elongated styloid process. Am Surg. 1962;28:1-5
4. Lages LPD, Monte TL, Freitas SAP, Falcao CAM. Alongamento do processo estiloidee síndrome de Eagle: consideracoes anatomicas, clinicas, diagnosticoe prevalencia. Odontologia. Clín Científ. 2006;5:183-88
5. Guimaraes SMR, Carvalho ACPC, Guimaraes JP, Gomes MBG, Cardoso MMM. & Reis HN. Prevalencia de alteracao morfologica do processoestiloide em pacientes com desordem temporomandibular. Radiologia Brasileira. 2006;39:407-11
6. Rosa RR, Kohatsu LI, Moraes LC, Medici FE, Moraes MEL, Castilho JCM. Síndrome de Eagle:revisao da literatura sobre variacoes, diagnostico e tratamento. Revista de Odontologia da Universidade Cidade de Sao Paulo. 2008; 20:288-94.
7. Standing S. Skull and Mandible. In Gray's Anatomy. The Anatomical basis of clinical practice. Elsevier, Edinburg.2005: 39th edition; 470
8. Murtagh R, Caracciolo J, Fernandez G. CT Findings associated with Eagle syndrome. AJNR. 2001, 22:1401-02.
9. Piagkou M, Anagnostopoulou S, Kouladouros K, Piagkos G. Eagle's syndrome: a review of the literature. Clinical Anatomy. 2009; 22: 545-58.
10. Rodriguez Vazquez JF, MeridaVelasco JR, Verdugo LS, Sanchez-Montesinos I, Merida-Velasco JA. Morphogenesis of the second pharyngeal arch cartilage (Reichert's cartilage) in human embryos. J Anat. 2006; 208: 179–89.