

International Journal of Biomedical and Advance Research

ISSN: 2229-3809 (Online); 2455-0558 (Print)

Journal DOI: [10.7439/ijbar](https://doi.org/10.7439/ijbar)

CODEN: IJBABN

Case Report

Post partum ovarian vein thrombosis presenting with left loin pain – A case report

Masudi Sheetal*, Praveen M. Mundaganur, Jonna Uday. B, Puneet Shirbur and
Shivendra Choudhary

Department of Radiology, Shri B M Patil Medical College, Bijapur Karnataka, India

***Correspondence Info:**

Dr. Masudi Sheetal

Department of Radiology,

Shri B M Patil Medical College, Bijapur Karnataka, India

E-mail: masudi.heetal74@gmail.com**Abstract**

Postpartum ovarian vein thrombosis (POVT) is an uncommon but serious complication. Clinically it is a difficultly diagnosed entity, must be thought of as differential diagnosis in cases of postpartum acute abdomen. POVT may cause serious complications like sepsis, pulmonary embolism, thrombosis of the inferior vena cava and renal veins, and may cause death. It is often clinically indistinguishable from other causes of post partum acute pain. Most of the cases present as right loin and right iliac fossa pain, within initial 10 days of the puerperal period. This report presents a case of left ovarian vein thrombosis complicated by renal vein thrombosis presenting as left ureteric colic. The imaging findings illustrate the difficulty in clinical and radiological diagnosis of post-partum ovarian vein thrombosis, and thus highlight the need to include it as one of the differential diagnosis in such cases of post partum acute abdomen. Anti-coagulants and intravenous antibiotics remain the mainstay of treatment. Non-invasive investigations help in accurate diagnosis of POVT and a surgery can be avoided.

Keywords: Ovarian vein thrombosis, postpartum, left loin pain

1. Introduction

Post-partum ovarian vein thrombosis (POVT) is an uncommon clinical presentation. The true incidence is not known. Clinical findings of OVT are usually nonspecific and symptoms may mimic appendicitis, ovarian torsion, tuboovarian abscess, puerperal endometritis and pyelonephritis. Abdominal pain in lower quadrants, flank pain, fever, and leucocytosis are major findings. In 90 % of cases right ovarian vein is commonly involved. It presents with a variety of pelvic conditions —most notably, recent childbirth. It could also be associated with pelvic inflammatory disease, malignancies, and pelvic surgery.[1] A high suspicion is required in order to diagnose this unusual cause of abdominal pain, which can mimic acute abdomen.[2] Immediate diagnosis and treatment of this condition is required to avoid the morbidity and mortality that are related both to the thrombosis and to any associated infection/sepsis.[1]

2. Case Report

A 30-year-old young woman on postpartum day 5 was admitted to our hospital because of severe left lower quadrant abdominal pain. She had vaginal delivery of a live born-term baby, and the immediate postpartum period was uneventful. The pain started on postpartum day four and was accompanied with fever, nausea and vomiting; with no evidence of vaginal bleeding. Physical examination showed a severely ill patient with left lower quadrant and loin tenderness; there was no evidence of deep vein thrombosis in the lower extremities. A pelvic examination revealed a non-tender bulky uterus.

USG abdomen and pelvis did not reveal any abnormality. Further evaluation with a CT - KUB was obtained to rule out ureteric calculi. It demonstrated a dilated left ovarian vein with non-enhancing filling defect (figure 1) extending into left renal vein and the inferior vena cava (figure 2). There

was also evidence of enlarged left kidney with altered poor parenchymal enhancement in early phases and delayed persistent nephrogram (figure 3). Effacement of left pelvicalyceal system is noted due to renal edema. No contrast is seen in left ureter, proximal part of left ureter appears normal, distal part could not be delineated. Evidence of wedge shaped poorly enhancing hypodense lesion is seen in anterior cortex of mid pole of left kidney. No evidence of hydronephrosis/calculi was noted.

Figure 1: Dilated left ovarian vein with non-enhancing filling defect (Arrow).

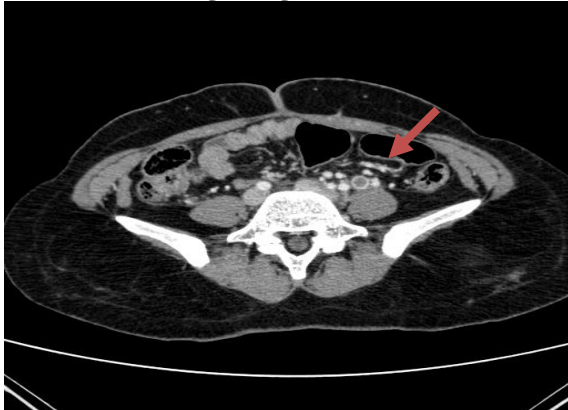


Figure 2a): Thrombus extending into left renal vein (Arrow head), small shaped hypodensity in anterior cortex of left kidney (Arrow)

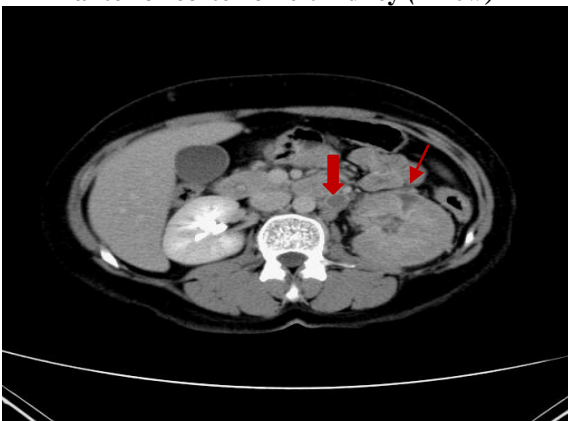

Figure 2b: Dilated left renal vein with hypodense filling vein within and enlarged left kidney with no excretion of contrast in early phase (Arrow).

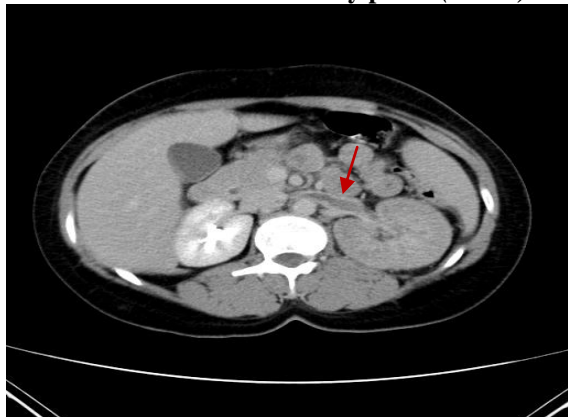

Figure 3a: Absent nephrogram in early phase (Arrow), minimal fluid in endometrial cavity (Block arrow).

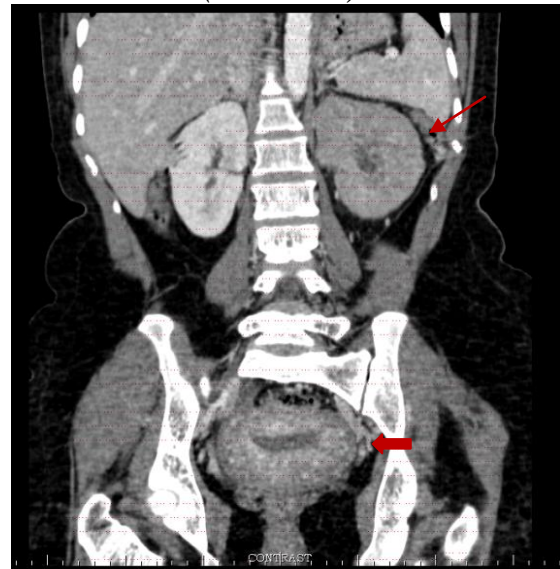
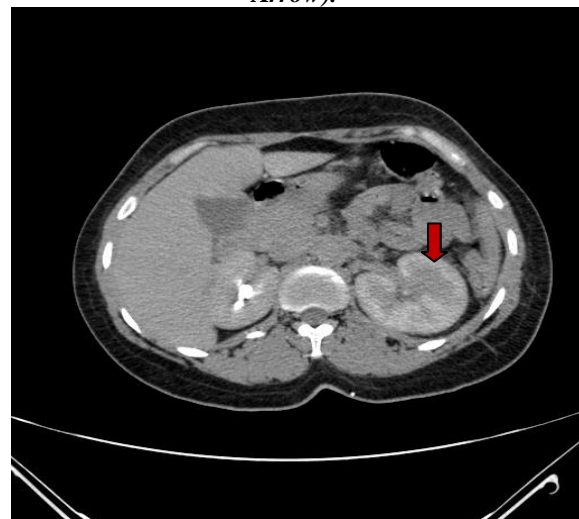


Figure 3b: Delayed persistent nephrogram (Block Arrow).



3. Discussion

The first case of postpartum ovarian vein thrombosis was described by Austin in 1956.[2] The incidence of post-partum ovarian vein thrombosis is 1:2000 deliveries.[3] Ovarian vein thrombosis occurs in post partum women due to venous stasis and hypercoagulability.[3] Pregnancy is associated with a hypercoagulable state, venous stasis due to compression of the inferior vena cava by the uterus and endothelial trauma during delivery or from local inflammation which leads to OVT, and is explained by Virchow's triad.[4] Right ovarian vein is the one commonly affected in 80-90% of the cases following delivery.[5] The risk of thrombosis of about 1-2% is associated with caesarean delivery, multiparity,

pelvic inflammatory disease, malignancies, Crohn's disease and pelvic surgical procedures.[6] Other risk factors reported for OVT are hypercoagulation conditions as systemic lupus erythematosus, antiphospholipid syndrome, presence of factor V Leiden, paroxysmal nocturnal haemoglobinuria, hyperhomocysteinaemia, protein C and S deficiency and heparin induced thrombocytopenia.[2] The signs and symptoms of OVT include lower abdomen or flank pain, fever and leukocytosis usually within the initial ten days after delivery.[2] The condition is often clinically not distinguishable from endometritis, appendicitis or pyelonephritis.[7] Ultrasonography, Magnetic resonance imaging (MRI) or MDCT scan can diagnose POVT with a sensitivity of 52%, 92% and 100%, respectively. Doppler Study of inferior vena cava (IVC) and ovarian veins is also a useful tool for follow up. Magnetic resonance angiography can provide a better and more reliable visualization in evaluating the extent of thrombus of the vascular systems. Contrast enhanced CT study and a conventional venography are also reliable methods for diagnosing POVT.[3]

Dilated, thick-walled ovarian veins with peripheral enhancement and a central hypodensity are considered to be the main CT findings of POVT as seen in the reported cases.[3] Anticoagulation therapy with heparin along with intravenous antibiotics for systemic sepsis resulting from the left ovarian vein thrombosis remains mainstay of management.

4. Conclusion

Ovarian vein thrombosis (OVT) (often called as thrombophlebitis) is an uncommon postpartum complication. Clinical and laboratory parameters are non-specific and misleading; hence the diagnosis of ovarian vein thrombosis remains difficult. CT-scan is the investigation of choice in diagnosis. Treatment consists of a combination of anticoagulation and antibiotics.

References

- [1] Amos A, Akinbiyi, Nguyen R, Katz M. Postpartum Ovarian Vein Thrombosis: Two Cases and Review of Literature. *Case Reports in Medicine* 2009 (101367): doi: 10.1155/2009/101367
- [2] Arkadopoulos N, Dellaportas D, Yiallourou A, et al. Ovarian vein thrombosis mimicking acute abdomen: a case report and literature review. *World J of Emerg Surg.* 2011; 6:45
- [3] Dhinakar et al. Puerperal Ovarian Vein Thrombosis. *Oman Medical Journal* 2010 Oct; 25(4): 299-302.
- [4] S O Hagan, S Andronikou, R Truter, C J van Rensburg. Ovarian vein thrombosis – a rare but important complication of hysterectomy and oophorectomy. *S Afr J OG* 2013; 19 (3):86-87.
- [5] Slam K, Duckett S, Thirumoorthi A S, Clark P. Ovarian vein thrombosis in two postpartum women. *Hospital Physician* 2008; 31-35.
- [6] Royo P, Alonso-Burgos A, Garcia-Manero M, Lecumberri R, Alcazar JL. Postpartum ovarian vein thrombosis after cesarean delivery: a case report. *Journal of Medical Case Reports* 2008; 2:105.
- [7] Hippach M, Meyberg R, Villena-Heinsen C, Mink D, Ertan AK, Schmidt W, Friedrich. Post partum ovarian vein thrombosis. *M Clin Exp Obstet Gynecol.* 2000; 27(1):24-6.