

## Pitfalls in diagnosis of diaphragmatic tear

**Abhilash Gautham Ramesh\***, Vijaya L Patil, Sanjay Namadar, Mallikarjun C, Harsh Patel and Krishna Sai Karlapudi

*B.L.D.E.Us Sri B M Patil Medical College, Bijapur, India*

### \*Correspondence Info:

Dr. Abhilash Gautham Ramesh

B.L.D.E.Us Sri B M Patil Medical College, Bijapur, India

E-mail: [abhilash.gautham@yahoo.com](mailto:abhilash.gautham@yahoo.com)

### Abstract

Traumatic diaphragmatic injury is a life threatening and an occult clinical entity which can be easily missed in diagnosis. Diaphragmatic ruptures are usually associated with abdominal trauma however, it can occur in isolation.

Here we report a case of young adult male with poly trauma, whose initial diagnosis revealed multiple rib fractures on right side and right haemothorax and normal left pneumothorax. After intercostal drainage was placed on right side, left diaphragmatic tear with bowel contents in left lung cavity was revealed. He was successfully managed surgically.

**Keywords:** Diaphragmatic ruptures, trauma, fractures.

### 1. Introduction

Traumatic diaphragmatic injury is a life threatening and an occult clinical entity which can be easily missed in diagnosis. Diaphragmatic ruptures are usually associated with abdominal trauma however, it can occur in isolation. Their delayed presentation can be due to the delayed rupture of the diaphragm or delayed detection of diaphragmatic rupture, making the accurate diagnosis of Diaphragmatic Injury is challenging to the surgeons. Here we report a case of young adult male with poly trauma, whose initial diagnosis revealed multiple rib fractures on right side and right haemothorax and normal left pneumothorax. After intercostal drainage was placed on right side, left diaphragmatic tear with bowel contents in left lung cavity was revealed. He was successfully managed surgically. Hence we report this case to emphasize that a high clinical index of suspicion is needed to diagnose, effectively manage diaphragmatic rupture even with a remote history of high-velocity injury.

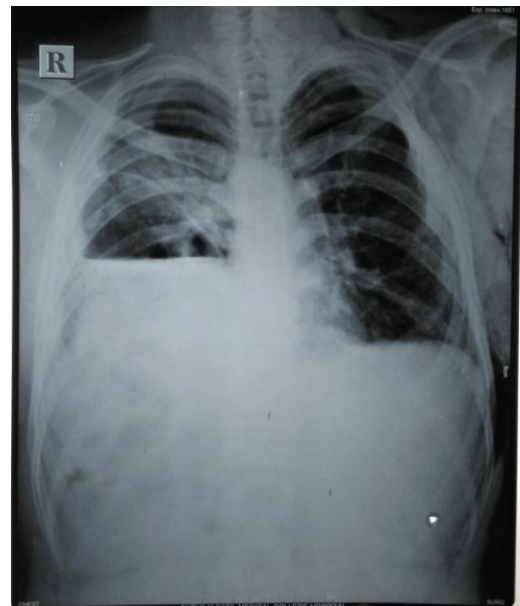
### 2. Case Report

A 33Yr old gentleman was brought to casualty after 2hours of alleged history of road traffic accident with cut lacerated wound on right axillary area of 20 x 8 cms who was well oriented and conscious.

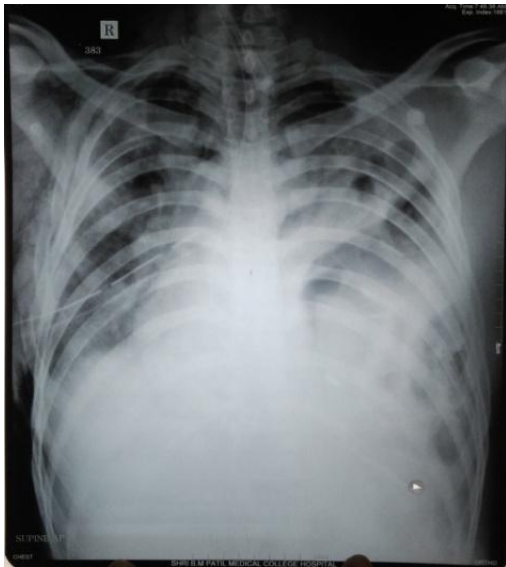
On examination: Pulse rate was 114 bpm, Blood Pressure 96/70 mm, Respiratory rate was 22 cpm.

He had tenderness and decreased sounds, dull percussion note with subcutaneous emphysema on the right side. Chest compression test positive. On chest x ray PA view features are suggestive of right sided hydropneumothorax and

fracture of 4<sup>th</sup> and 6<sup>th</sup> ribs. For this ICD has been inserted on right side and after stabilising patient repeat x-ray chest was done on following day which revealed completely resolved haemothorax on right side and bowel loops shadows in left hemithorax.



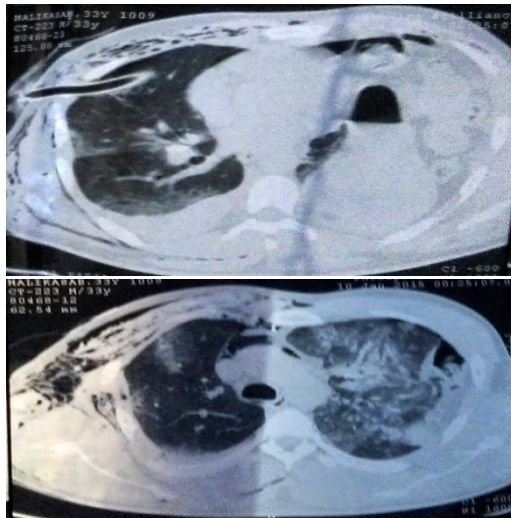
**Figure 1: Chest X ray PA view at the time of admission showing Right sided hydropneumothorax and fracture of 4<sup>th</sup> and 6<sup>th</sup> ribs**



**Figure 2: Repeat Chest X ray PA view after inserting ICD on the following day revealed completely resolved Haemothorax with bowel loops shadows in left hemithorax**

CT scan of the chest revealed,

- 1) Large bowel and small bowel loops, stomach, mesenteric vessels and mesentery in the left thoracic cavity mostly due to herniation through diaphragmatic rupture.
- 2) Right hemothorax.
- 3) Pneumomediastinum with soft tissue surgical emphysema of the chest wall.
- 4) Multiple ribs fractures and diffuse contusions in bilateral lung fields.



### 3. Discussion

True incidence of Diaphragmatic injury is not known.[1] Diaphragmatic rupture with abdominal organ herniation was first described by Sennertus in 1541.[2] Diaphragmatic injury is a recognize consequence of high velocity blunt and penetrating trauma to the abdomen and chest rather than from a trivial fall.[3] These patients usually

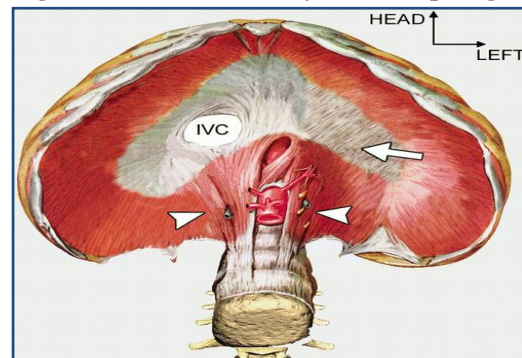
have multi system injuries because of the large force required to rupture the diaphragm.[4]

Diaphragm is the musculotendinous structure that seals the inferior thoracic aperture. Diaphragm is not flat, rather it balloons superiorly on both the sides to form domes, the right dome is higher than left, reaching as far as rib V.[5]

There are three openings permitting the passage of three large structures.

- 1) The inferior vena cava and the right phrenic nerves pass through an opening at the level of T8.
- 2) The oesophagus and vagus nerves pass through an opening at the level of T10.
- 3) The abdominal aorta, thoracic duct and azygous vein pass through an opening at T12.

**Figure 3: Normal anatomy of the diaphragm.**



Drawing shows the central tendon (arrow) and the crura (arrowheads).

IVC = aperture for the inferior vena cava.

### Clinical presentation

Physical findings can be either thoracic or abdominal. Thoracic signs include decreased breath sounds, fractured ribs, flail chest and signs of haemothorax or pneumothorax. Auscultation of bowel sounds in the chest is pathognomonic of diaphragmatic rupture, occurring due to herniation of bowel contents.

Abdominal signs include abdominal pain, guarding, absence of bowel sounds, and abdominal swelling, depending on the extent of injuries. Occasionally physical examination can be relatively normal.

### Diagnosis and investigations

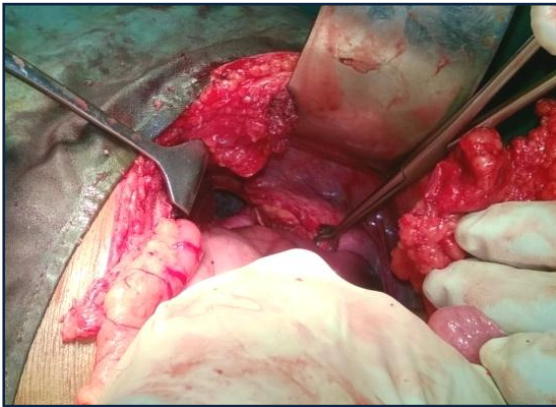
There is no "gold standard" investigations for early diagnosis of traumatic diaphragmatic rupture. While audible bowel sounds on the chest auscultation suggests displaced bowel loops.

- 1) Chest x ray is the first line of investigation, repeated imaging increases sensitivity.[4]
- 2) CT scan is the second choice of imaging technique after X-ray chest.
- 3) When CT results remain equivocal, T1-weighted sagittal and coronal magnetic resonance imaging has proven very useful for both right- and left-sided injury.[6]
- 4) Other techniques used include Focused Abdominal Sonography for Trauma (FAST) and Diagnostic Peritoneal Lavage (DPL), intraperitoneal injection of technetium sulphur colloid.[7]

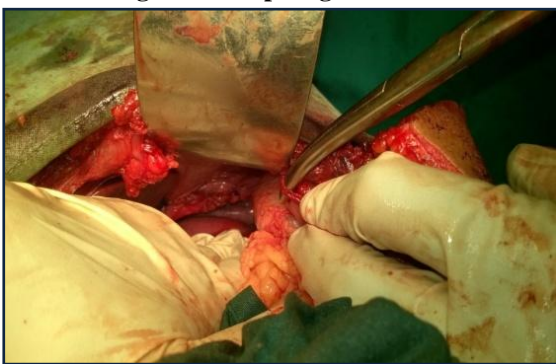5) With the increasing utilisation of laparoscopy and thoracoscopy more diaphragmatic injuries are being correctly diagnosed and in some cases repaired without the need for a laparotomy.

**Treatment:** A linear midline incision is taken and abdominal layers are divided.

A horizontal tear measuring 8×2cm is seen in the left dome of diaphragm. Herniating contents stomach, spleen, part of small intestine and large intestine are reduced back to intestinal cavity and patency and viability of bowels are checked. Diaphragmatic tear is sutured with nonabsorbable suture in continuous manner and abdominal layers are closed after achieving complete hemostasis. An ICD No.30 is introduced in the left 5<sup>th</sup> intercostal space.



**Figure 7: Diaphragmatic tear**



**Figure 8: Repair of tear with nonabsorbable suture**

#### 4. Conclusion

Blunt diaphragmatic injuries are easily missed in the absence of other indications for immediate surgery, since radiologic abnormalities of the diaphragm—particularly those involving the right hemidiaphragm—are often interpreted as thoracic trauma. In this setting, a high index of suspicion coupled with selective use of radionuclide scanning, ultrasound, and CT or magnetic resonance imaging is necessary for early detection of this uncommon injury.

Careful clinical examination and close monitoring of the patient in blunt abdominal trauma injury is essential for diagnosis of uncommon injuries like diaphragmatic tear.

#### References

- [1] Yilmaz M, Isik B, Ara C, Yilmaz S, Kutlu R, Kocak O, et al. Gastric perforation during chest tube placement for acute diaphragmatic rupture and review of the literature. *Injury Extra* 2006; 37:71–5.
- [2] Christie DB 3rd, Chapman J, Wynne JL, Ashley DW: Delayed right-sided diaphragmatic rupture and chronic herniation of unusual abdominal contents. *Journal of the American College of Surgeons* 2007; 204(1):176.
- [3] Goh BK, Wong AS, Tay KH, Hoe MN: Delayed presentation of a patient with a ruptured diaphragm complicated by gastric incarceration and perforation after apparently minor blunt trauma. *Canadian Journal of Emergency Medicine* 2004; 6(4):277-280.
- [4] Meyers BF, McCabe CJ: Traumatic diaphragmatic hernia. Occult marker of serious injury. *Ann Surg.* 1993; 218(6):783-790.
- [5] Stern Jr Jack T. The abdomino – pelvic cavity and wall. *Core concepts in anatomy* 2004 [accessed 22.10.08]
- [6] Mirvis SE, Shanmuganagthan K. Imaging hemidiaphragmatic injury. *Eur Radiol.* 2007; 17:1411–21.
- [7] May AK, Moore MM: Diagnosis of blunt rupture of the right hemidiaphragm by technetium scan. *Am Surg.* 1999; 65(8):761-765.