

Original  
Article

# Clinicopathological study of itchy folliculitis in HIV-infected patients

Vamseedhar Annam, B. R. Yelikar<sup>1</sup>, Arun C. Inamadar<sup>2</sup>, Aparna Palit<sup>2</sup>, P. Arathi<sup>3</sup>

Department of Pathology, Sree Siddhartha Medical College, Hospital and Research Centre, Tumkur, Karnataka, Departments of <sup>1</sup>Pathology, <sup>2</sup>Dermatology, Venereology and Leprosy, BLDEA's SBM Patil Medical College, Hospital and Research Centre, Bijapur, Karnataka, <sup>3</sup>Ashirwad Dermatology Clinic, Bangalore, India

**Address for correspondence:**

Dr. Vamseedhar Annam, Department of Pathology, Sree Siddhartha Medical College, Hospital and Research Centre, Tumkur, Karnataka, India. E-mail: vamseedhar\_a@yahoo.com

## ABSTRACT

**Background:** Itchy folliculitis are pruritic, folliculo-papular lesions seen in human immunodeficiency virus (HIV)-infected patients. Previous studies have shown that it was impossible to clinically differentiate between eosinophilic folliculitis (EF) and infective folliculitis (IF). Also, attempts to suppress the intense itch of EF were ineffective. **Aims:** The present study is aimed at correlating clinical, histopathological and immunological features of itchy folliculitis in HIV patients along with their treatment. **Methods:** The present prospective study lasted for 36 months (September, 2005 to August, 2008) after informed consent, data on skin disorders, HIV status and CD4 count were obtained by physical examination, histopathological examination and laboratory methods. **Results:** Of 51 HIV-positive patients with itchy folliculitis, the predominant lesion was EF in 23 (45.1%) followed by bacterial folliculitis in 21 (41.2%), *Pityrosporum* folliculitis in five (9.8%) and Demodex folliculitis in two (3.9%) patients. The diagnosis was based on characteristic histopathological features and was also associated with microbiology confirmation wherever required. EF was associated with a lower mean CD4 count ( $180.58 \pm 48.07$  cells/mm<sup>3</sup>,  $P$ -value < 0.05), higher mean CD8 count ( $1675.42 \pm 407.62$  cells/mm<sup>3</sup>) and CD8/CD4 ratio of 9.27:1. There was significant reduction in lesions following specific treatment for the specific lesion identified. **Conclusion:** Clinically, it is impossible to differentiate itchy folliculitis and therefore it requires histopathological confirmation. Appropriate antimicrobial treatment for IF can be rapidly beneficial. The highly active antiretroviral therapy along with Isotretinoin therapy has shown marked reduction in the lesions of EF. Familiarity with these lesions may help in improving the quality of lives of the patients.

**Key words:** Itchy folliculitis, histopathology, Infective folliculitis, HIV

DOI: 10.4103/0378-6323.62965

## INTRODUCTION

The skin immune system acts as target and effector organ in human immunodeficiency virus (HIV) disease.<sup>[1]</sup> Observations over the last 20 years reveal that various skin diseases occur with an increased clinical severity in HIV-infected individuals.<sup>[2,3]</sup> Cutaneous manifestations appear at different stages of HIV infection and some are prognostic markers for disease contribution.<sup>[4,5]</sup> A paradoxical increase in hypersensitivity accompanies immunosuppression, which is presumed to be due to immunodysregulation.<sup>[6]</sup>

Eosinophilic folliculitis (EF) is the most common

HIV-associated itchy folliculitis and was termed so because of its histopathological similarities to Ofuji's disease (eosinophilic pustular folliculitis)<sup>[7,8]</sup> Other cases of HIV-associated itchy folliculitis are infective in origin either due to bacteria, Demodex, *Pityrosporum* or a combination.<sup>[9]</sup> It is seldom possible to clinically differentiate between the different types of HIV-associated itchy folliculitis; however, histology is usually diagnostic and differentiates patients with HIV-associated infective folliculitis (IF) from those with EF. We herein present the clinicopathological, immunological and treatment aspects of HIV-associated itchy folliculitis.

**How to cite this article:** Annam V, Yelikar BR, Inamadar AC, Palit A, Arathi P. Clinicopathological study of itchy folliculitis in HIV-infected patients. Indian J Dermatol Venereol Leprol 2010;76:259-62.

**Received:** February, 2009. **Accepted:** April, 2009. **Source of Support:** Nil. **Conflict of Interest:** None declared.

## METHODS

The present prospective study was carried out for a period of 36 months (September, 2005 to August, 2008) in the Department of Pathology at two tertiary referral centers. The skin biopsies from HIV-positive patients with clinical diagnosis of itchy folliculitis were received from the Department of Dermatology.

After informed consent, information was obtained through a structured questionnaire from patients on their sociodemographic status and antiretroviral therapy. Patients on antiretroviral therapy were excluded from the study. Antibodies to HIV were demonstrated by three different methods (Tridot, Capillus and Combaids tests). Physical examination was performed to identify folliculitis. Skin biopsies were performed in these patients for identification of characteristic histological features. Multiple 3–5- $\mu$ m-thick serial histological sections were examined using hematoxylin and eosin stain to rule out a folliculocentric pathological process. The measurements of peripheral blood CD4 and CD8 counts were performed by Tricolour Flow Cytometry.

### Data analysis

The one-way ANOVA was used to determine the strength of association between HIV-associated itchy folliculitis and CD4 and CD8 count. *P*-value was considered significant when it was less than or equal to 0.05.

## RESULTS

A total of 51 HIV-positive patients with clinical diagnosis of itchy folliculitis accepted to take part in the study. The risk factors in men and women included heterosexual contact with multiple sexual partners, while in the pediatric group it was vertical transmission. The age ranged from 6 years to 54 years, with the male: female ratio being 2.2:1 (males 35, females 16). Specific histopathological findings in these HIV-associated itchy folliculitis were seen in 100% (51/51) of the cases. The most common type of itchy folliculitis on histopathology was EF followed by bacterial folliculitis, *Pityrosporum* folliculitis and *Demodex* folliculitis.

HIV-associated itchy folliculitis was associated with a lower mean CD4 count of  $148.82 \pm 49.03$  cells/mm<sup>3</sup>. The strength of association between HIV-associated

itchy folliculitis and CD4 counts was carried out by one-way ANOVA (*F*-value 8.26, *P*-value <0.001). The relationship of mean CD4 and CD8 counts and the CD4:CD8 ratio with histopathological spectrum of HIV-associated itchy folliculitis is enlisted in Table 1.

The distribution and morphological features of cutaneous lesions in HIV-EF were itchy papules distributed over the face [Figure 1], upper limbs and trunk, sparing the abdomen, palms and soles. In the early lesions of EF, lymphocytes predominate over the eosinophils [Figure 2], which were distributed perifollicularly and also interstitially while in the late-developed lesions of EF, the eosinophils predominate over the lymphocytes and were confined to the perifollicular and follicular region [Figure 3]. The strength of association between HIV-EF with CD4 counts was assessed by one-way ANOVA (*F*-value 4.12) and the *P*-value was < 0.05. Among the 23 patients with HIV-EF treated with highly active antiretroviral therapy along with Isoretinoin therapy at a dose of 40–80 mg/day (0.5–1.2 mg/kg/day), 16 patients showed complete response while seven patients showed partial response, i.e. symptoms completely subsided but few lesions appeared intact.

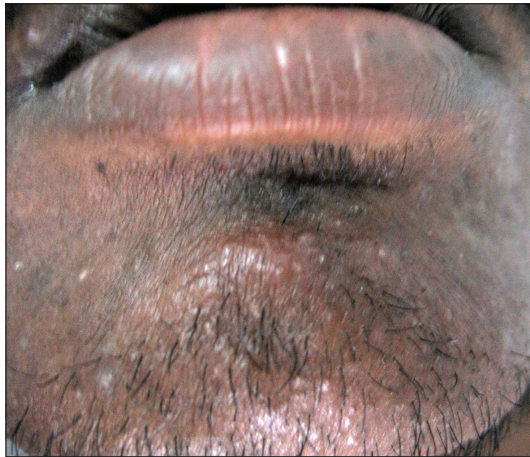Of the HIV-associated IF, the predominant lesion was bacterial folliculitis in 21 (41.2%) followed by *Pityrosporum* folliculitis in five (9.8%) and *Demodex* folliculitis in two (3.9%) patients. The histological pattern was of inflammation associated with readily identifiable organisms but without EF or associated sebaceous cysts. The cellular infiltrate was composed of neutrophils and macrophages occasionally associated with rupture of the involved follicle [Figure 4]. The lesions of infective folliculitis in all the 21 patients started to disappear following appropriate antimicrobial treatment along with highly active antiretroviral therapy.

## DISCUSSION

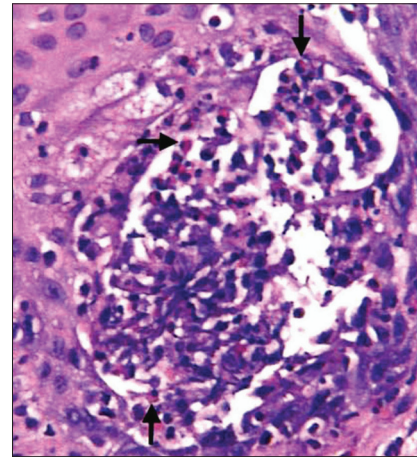
Skin manifestations are hallmarks of HIV infection. Of the spectrum of cutaneous lesions in HIV-infected patients, HIV-associated folliculitis is one of the prevalent dermatological disorders with advanced stage of the disease.<sup>[10]</sup> The HIV-associated itchy folliculitis can be either EF or IF. Clinically, it is impossible to differentiate between EF and IF. Folliculitis has been shown to occur predominantly when CD4 lymphocyte counts fall below 200 cells/

**Table 1: Relationship of HIV-associated itchy folliculitis with mean CD4 and CD8 counts**

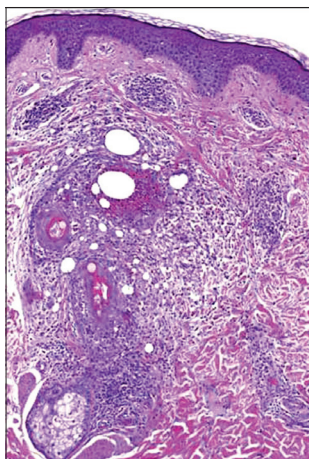
Histopathology diagnosis	No. (%)	CD4 count (cells/mm <sup>3</sup> )	CD8 count (cells/mm <sup>3</sup> )	CD4:CD8 ratio	P-value
Eosinophilic folliculitis	23 (45.1)	180.58	1675.42	1:9.2	0.046
Bacterial folliculitis	21 (41.2)	122.67	380.02	1:3.1	0.086
Endothrix folliculitis	5 (9.8)	141.38	302.93	1:2.1	-
Demodex folliculitis	2 (3.9)	61.73	164.87	1:2.7	-



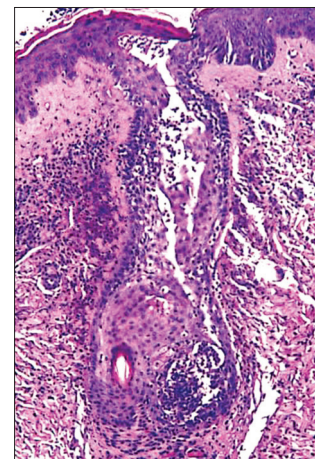

**Figure 1: Itchy papules distributed over the face**



**Figure 2: Early eosinophilic folliculitis: There are seen numerous lymphocytes with some eosinophils (arrow) distributed in the follicular region. (H & E, ×400)**



**Figure 3: Late eosinophilic folliculitis: The dermis shows some lymphocytes with numerous eosinophils infiltrating into the perifollicular, follicular and sebaceous regions. (H & E, ×50)**



**Figure 4: Infective folliculitis: The cellular infiltrate composed of neutrophils and macrophages is associated with rupture of the involved follicle. (H & E, ×50)**

mm,<sup>[3,11]</sup> which was consistent with the present study (mean CD4 count 148.82 cells/mm<sup>3</sup>, one-way ANOVA [*F*-value 8.26] and *P*-value <0.001).

Most of the pruritic papular lesions are clinically a diagnostic dilemma. The distribution of cutaneous lesions was all over the body, except the genitalia. Prurigo simplex can lead to prurigo nodularis.<sup>[6]</sup> In patients with prurigo simplex, the common histological

features in the epidermis were parakeratosis, acanthosis and a spongiotic vesicle. Also seen was perivascular infiltration of the lymphocytes in the superficial dermis. The distribution and morphological features of cutaneous lesions in HIV-EF were itchy erythematous papules distributed over the face, upper limbs and trunk. In 9/36 (25%) patients with HIV-EF, we found the histology to be characterized by an inflammatory infiltrate of lymphocytes and eosinophils



focused at the level of the follicular isthmus [Figure 4] and sebaceous gland, with a striking associated patchy sebaceous lysis, which has been corroborated in other studies<sup>[2]</sup> Previous studies on immunophenotypic analysis showed the lymphocytes to be T cells with a marked CD8 predominance (CD8/CD4 ratio of 10:1),<sup>[9,12]</sup> which was observed in the present study (CD8/CD4 ratio of 9.2:1). Eosinophilic folliculitis associated with HIV infection typically affects individuals with advanced HIV and low CD4 cell counts (CD4 count < 250 cells/mm<sup>3</sup>),<sup>[7,13,14]</sup> but in our study the mean CD4 count was 180.58 cells/mm<sup>3</sup> (one-way ANOVA [*F*-value 4.12] and the *P*-value was <0.05). The exact etiology of HIV-EF remains unknown but does not seem to be bacterial, fungal or related to the common skin mite. But, several antimicrobial agents, however, have demonstrated success in treating HIV-EF. They include metronidazole,<sup>[15]</sup> itraconazole<sup>[16]</sup> and permethrin.<sup>[17]</sup> This success has led to postulations that HIV-EF is caused by a pathogen, e.g. *Pityrosporum* or *Demodex* mites. Other successful treatments have included UV-B, psoralen-UV-A<sup>[18]</sup> and cetirizine,<sup>[19]</sup> an antihistamine with anti-eosinophilic properties. In contrast, the success of isotretinoin in treating some cases has led to the hypothesis that HIV-EF could represent an eosinophilic immunedysregulation directed at a lipid-soluble chemotactic factor in the sebum.<sup>[9]</sup> Also, on histopathology, there is sebaceous distribution and sebaceous gland lyses in HIV-EF, which were seen in few of our patients. Most of our patients responded to the combination of HAART with isotretinoin therapy. However, it is not a feature seen in any of the 23 patients with HIV-associated EF. The CD4 count in HIV-associated IF was <54 cells/mm<sup>3</sup> in other studies,<sup>[9]</sup> but in our study the mean CD4 count was 118.37 cells/mm<sup>3</sup> and the CD8 count was 358.88 cells/mm<sup>3</sup>. Both the CD4 and CD8 counts were reduced in IF, indicating advanced HIV infection due to immune dysregulation. There were also some cases of infective folliculitis due to *Pityrosporum* or *Demodex* mites. Further studies and a longer follow-up involving the detection of lesser known fungi and parasites and investigations for rarer causes of itchy folliculitis may eliminate the fraction of undiagnosed conditions.

## REFERENCES

1. Blauvelt A, Katz SI. The skin as a target, vector and effector organ in human immunodeficiency virus disease. *J Invest Dermatol* 1995;105:122-6.
2. Saple DG, Maniar JK. Dermatologic manifestations in HIV/AIDS. *AIDS Res Rev* 1999;2:69-77.
3. Raju PV, Rao GR, Ramani TV, Vandana S. Skin disease: Clinical indicator of immune status in human immunodeficiency virus infection. *Int J Dermatol* 2005;44:646-9.
4. Uthayakumar S, Nandwani R, Drinkwater T, Nayagam AT, Darley CR. The prevalence of skin disease in HIV infection and its relationship to the degree of immunosuppression. *Br J Dermatol* 1997;137:595-8.
5. Duvic M. Human immunodeficiency virus disease and skin: Selected controversies. *J Invest Dermatol* 1995;105:117-21.
6. Sample S, Chernoff DN, Lenahan GA, Serwonska MH, Rangi S, Sherman JW, *et al.* Elevated serum concentrations of IgE antibodies to environment antigens in HIV seropositive male homosexuals. *J Allergy Clin Immunol* 1990;86:876-80.
7. Soeprono FF, Schinella RA. Eosinophilic pustular folliculitis in patients with acquired immunodeficiency syndrome: Report of three cases. *J Am Acad Dermatol* 1986;14:1020-2.
8. Ofuji S, Ogino A, Horio T, Oseko T, Uehara M. Eosinophilic pustular folliculitis. *Acta Derm Venereol* 1970;50:195-203.
9. Fearfield LA, Rowe A, Francis N, Bunker CB, Staughton RC. Itchy folliculitis and human immunodeficiency virus infection: Clinicopathological and immunological features, pathogenesis and treatment. *Br J Dermatol* 1999;141:3-11.
10. Zancanaro PC, McGirt LY, Mamelak AJ, Nguyen RH, Martins CR. Cutaneous manifestations of HIV in the era of highly active antiretroviral therapy: An institutional urban clinic experience. *J Am Acad Dermatol* 2006;54:581-8.
11. Wiwanitkit V. Prevalence of dermatological disorders in Thai HIV-infected patients correlated with different CD4 lymphocyte count statuses: note on 120 cases. *Int J Dermatol* 2004;43:265-8.
12. Fields LL, Toro J, Maurer T. Detection of perifollicular IL-4 and IL-5 in HIV associated eosinophilic folliculitis. *J Invest Dermatol* 1989;92:408.
13. Rosenthal D, LeBoit PE, Klumpp L, Berger TG. Human immunodeficiency virus-associated eosinophilic folliculitis: A unique dermatosis associated with advanced human immunodeficiency virus infection. *Arch Dermatol* 1991;127:206-9.
14. Simpson-Dent S, Fearfield LA, Staughton RC. HIV associated eosinophilic folliculitis: Differential diagnosis and management. *Sex Transm Infect* 1999;75:291-3.
15. Smith KJ, Skelton HG, Yeager J, Ruiz N, Wagner KF. Metronidazole for eosinophilic pustular folliculitis in human immunodeficiency virus type 1-positive patients. *Arch Dermatol* 1995;131:1089-91.
16. Berger TG, Heon V, King C, Schulze K, Conant MA. Itraconazole therapy for human immunodeficiency virus-associated eosinophilic folliculitis. *Arch Dermatol* 1995;131:358-60.
17. Blauvelt A, Plott RT, Spooner K, Stearn B, Davey RT, Turner ML. Eosinophilic folliculitis associated with the acquired immunodeficiency syndrome responds well to permethrin. *Arch Dermatol* 1995;131:360-1.
18. Pardo RJ, Bogaert MA, Penneys NS, Byrne GE Jr, Ruiz P. UVB phototherapy of the pruritic papular eruption of the acquired immunodeficiency syndrome. *J Am Acad Dermatol* 1992;26:423-8.
19. Harris DW, Ostlere L, Buckley C, Johnson M, Rustin MH. Eosinophilic pustular folliculitis in an HIV-positive man: response to cetirizine. *Br J Dermatol* 1992;126:392-4.