

**IJCRR**

Vol 04 issue 18

Section: Anatomy

Category: Case Report

Received on:19/07/12

Revised on:26/07/12

Accepted on:02/08/12

**BILATERAL FORAMEN ARCUALE IN ATLAS VERTEBRA: A RARE CASE**S. D. Desai<sup>1</sup>, Rekha Hiremath<sup>1</sup>, Anand Mugadlimath<sup>2</sup><sup>1</sup>Department of Anatomy, Shri B M Patil Medical College, Bijapur, Karnataka<sup>2</sup>Department of Forensic Medicine and Toxicology, Shri B M Patil Medical College, Bijapur, Karnataka

E-mail of corresponding author: drrekhamugadlimath@gmail.com

**ABSTRACT**

Ponticuli in the atlas vertebra are bony spurs seen frequently from the anterior and posterior margins of the groove for the vertebral artery, which may convert the groove into a foramen.<sup>1</sup> This foramen is known as foramen arcuale. The foramen arcuale is infrequently found and is potentially a clinically/surgically significant anatomical variation of the atlas. When present, the vertebral artery travels through this bony ring after exiting the transverse foramen of the atlas and prior to entering the cranium. We present a case report in which we noted during routine osteology practicals on atlas vertebrae for under graduates, foramen arcuale. The literature regarding these osteological structures is reviewed regarding their presence and potential clinical significance. The occurrence of bilateral fully developed posterior ponticuli resulting in encasement of the third part of the vertebral artery appears to be very rare, hence the case being reported.

**Key words:** foramen arcuale, sulcus arteriae vertebralis, vertebrobasilar insufficiency.

**INTRODUCTION**

A surgery pertaining to atlantoaxial complex has often posed a challenge to surgeons because of complex anatomy and biomechanics of this region of spine. The vertebral artery groove is located on the superior surface of the posterior arch of atlas at its junction with lateral mass lodging the third part of the vertebral artery, vertebral venous plexus and suboccipital nerve.<sup>1</sup>

The groove is also called as the sulcus arteriae vertebralis, sometimes, the distal part of the groove forms a full bone bridge to the upper edge of the Superior articular facet of the atlas, thus forming a foramen called as foramen-arcuale. The foramen arcuale is an anatomical variation that the neurosurgeon should consider when undertaking surgery near the posterior arch of atlas and also should be kept as a differential- diagnosis of patients presenting with symptoms of vertebrobasilar insufficiency.<sup>2</sup>

### Case Report

We report a case of bilateral foramen arcuale in human atlas vertebrae (Figure 2), found during routine osteology class for undergraduate teaching. Normal atlas is shown (Fig.1) for comparison with anomalous atlas vertebra. Complete fusion of the posterior ponticulus was noted forming foramen for 3rd part of vertebral artery instead of groove (sulcus arteriae vertebralis). Vertebral artery represented by red colored wire in the figures below. In Fig.1 arrow represents sulcus arteriae vertebralis and in Fig.2 arrow represents posterior ponticle.

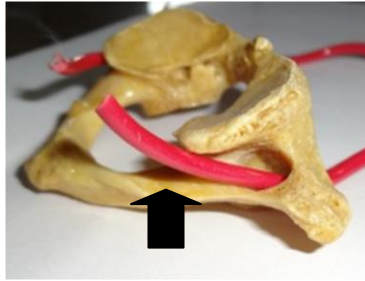


Fig.1: Groove for vertebral artery in Normal atlas vertebrae

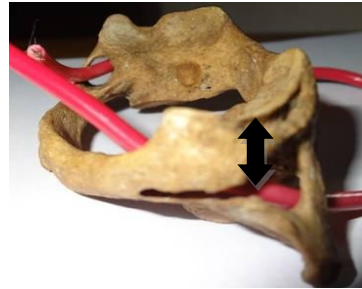


Fig.2 Bilateral foramen arcuale in the anomalous atlas in the present

### DISCUSSION

Many synonyms have been used by different authors from time to time some of them include- 'foramen retroarticulare superior' (Brocher, 1955), 'canalis vertebralis' (Wolff Heidegger, 1961), retroarticular vertebral artery ring (Lamberty & Zivanovic, 1973), 'retroarticular canal' (Mitchell, 1998) and 'retrocondylar vertebral artery ring' (Mitchell 1988).<sup>3</sup> Ponticle formation stated by many authors is a regressive and morphological phenomenon; furthermore this anatomical variation is not related to an increase in degenerative changes synonymous with aging. These characteristics not only serve as anthropological data but may also help in identifying the impact of complete foramen arcuale on the signs and symptoms of vertebrobasilar insufficiency.<sup>4</sup> The sulcus/groove for third part of vertebral artery on the dorsal aspect of the atlas that is completely covered by an abnormal ossification is termed the ponticulus posticus. The resulting foramen contains the vertebral artery referred as foramen arcuale. The

foramen arcuale, an osseous variant of the atlas should be considered during lateral mass screw fixation.<sup>5</sup> Complete ossification of ligamentous free margin of posterior atlanto-occipital membrane can lead to complete foramen arcuale. Clinical complaints such as vertigo, neck pain of discopathy are reported. Foramen arcuale is associated with Barre-Lieou syndrome, which represents symptoms of headache, retro-orbital pain, vasomotor disturbance of the face and recurrent disturbances of vision, swallowing and phonation due to alteration of blood flow within the vertebral arteries and an associated disturbance of periarterial nerve plexus.<sup>6</sup> Foramen arcuale leads to symptomatic entrapment, additional compression of the vertebral artery by a lateral ponticle when present could very likely result in stenosis of the vertebral artery.<sup>7</sup>

In a study Limousin reported good results in patients with this syndrome and an identified foramen arcuale in which the foramen was fractured and a periarterial sympathectomy was performed.<sup>8</sup> In another report Li et al. placed the

foramen arcuale in the differential diagnosis for vertigo and found satisfactory results in eleven patients that underwent decompression of the vertebral artery in foramen arculae.<sup>9</sup> Likewise, Sun found cessation of vertigo in 69 patients undergoing decompression and sympathectomy of the vertebral artery within a foramen arcuale.<sup>10</sup> Cushing et al. noted foramen arcuale in 8 of 11 patients with vertebral artery dissection and occlusion.<sup>11</sup>

From the above discussion it is evident that foramen arcuale is a clinically significant anomaly of atlas vertebra which can present with varied clinical features & syndromes, and hence the case being reported for publication.

### CONCLUSIONS

The knowledge about this present anatomical variation will be of immense help to Neurologists, neurosurgeons and radiologists when dealing with the patients complaining of symptoms of vertebrobasilar insufficiency like headache, vertigo, shoulder and arm pain.

### ACKNOWLEDGEMENT

Authors acknowledge the help received from the scholars whose articles are cited and included in references of this manuscript. The authors are also grateful to authors / editors /publishers of all those articles, journals and books from where the literature for this article has been reviewed and discussed.

### REFERENCES

1. Cakmak O, Gurdal E, Ekinici G, Yildiz E, Cavdar S. Arcuate foramen and its clinical significance. *Saudi Med J* 2005; 26: 1409-1413.
2. Tubbs RS, Johnson PC, Shoja MM, Loukas M. Foramen arcuale: anatomical study and review of the literature. *J Neurosurg Spine*. 2007; 6: 31–34.
3. Hasan M, Shukla S, Siddiqui MS, Singh D. Posterolateral tunnels and ponticuli in human atlas vertebrae. *J Anat*. 2001; 199: 339–43.
4. Unur E, Erdogan N, Ulger H, Ekinici N, Ozturk O. Radiographic incidence of complete arcuate foramen in Turkish population. *Erciyes Medical Journal*. 2004; 26: 50–54.
5. Young JP, Young PH, Ackermann MJ, Anderson PA, Riew KD. The ponticulus posticus: implications for screw insertion into the first cervical lateral mass. *J Bone Joint Surg Am*. 2005; 87: 2495–98.
6. Limousin CA. Foramen arcuale and syndrome of Barre-Lieou. Its surgical treatment. *Int Orthop*. 1980; 4: 19–23.
7. Tubbs S, Shoja MM, Shokouhi G, Farahani RM, Loukas M, Oakes JW. Simultaneous lateral and posterior ponticles resulting in the formation of a vertebral artery tunnel of the atlas: Case report and review of the literature. *Folia Neuropathol*. 2007; 45: 43–46.
8. Limousin CA. Foramen arcuale and syndrome of Barre-Lieou. *Int Orthop* 1980; 4: 19-23.
9. Li S, Li W, Sun J. Operative treatment for cervical vertigo caused by foramen arcuale. *Zhonghua Wai Ke Za Zhi* 1995; 33: 137-139.
10. Sun JY. Foramen arcuale and vertigo. *Zhonghua Wai Ke Za Zhi* 1990; 28: 592-594.
11. Cushing KE, Ramesh V, Gardner-Medwin D, Todd NV, Gholkar A, Baxter P, Griffiths PD. Tethering of the vertebral artery in the congenital arcuate foramen of the atlas vertebra: a possible cause of vertebral artery dissection in children. *Dev Med Child Neurol* 2001; 43: 491-496.