

## Chronic Hyperplastic Polypoid Tonsillitis

Venkatesh Manikrao Patil, Anirud Vasant Kustagi, Rashmi Mallangouda Patil

### ABSTRACT

Chronic tonsillitis is commonly seen in children. Tonsillitis presenting as unilateral pedunculated mass in oral cavity and leading to obstruction of airway is very rare. We report a patient who presented with mass in oropharynx measuring  $5 \times 2 \times 1$  cm and review of literature, management and implication of this benign lesion.

**Keywords:** Tonsil, Polypoidal, Breathing difficulty, Histopathology.

**How to cite this article:** Patil VM, Kustagi AV, Patil RM. Chronic Hyperplastic Polypoid Tonsillitis. *Int J Otorhinolaryngol Clin* 2012;4(3):160-161.

**Source of support:** Nil

**Conflict of interest:** None declared

### INTRODUCTION

Tonsillitis usually present with symptom of throat pain, difficulty in swallowing and neck swelling. Pedunculated polyps of palatine tonsil are relatively rare. Pedunculated polyps are diagnosed as lymphangiectatic fibrous polyp, polypoid lymphangioma, angiofibroma, pedunculated squamous papilloma, hamartomatous tonsillar polyp, lipoma, fibrolipomatous polyp, lymphangiomatous polyp and other.<sup>1,2</sup>

In this case report, we present a young child who was found to have polypoidal lesion of palatine tonsil with review of literature, management and implication of this benign lesion.

### CASE REPORT

A 12 years old girl, otherwise healthy, presented with painless right tonsillar mass that has been increasing in size for approximately 1 year. Patient developed breathing difficulty on sleeping supine and right lateral position. She felt comfortable on sleeping left lateral position. She denied any constitutional symptom.

She had difficulty in swallowing due to mass and change in voice. There was no history of bleeding from oral cavity or foul smelling discharge.

Clinical examination demonstrated a large mass measuring  $5 \times 2 \times 1$  cm with bosselated surface arising from right superior tonsillar pole, mass which is in contact with posterior end of soft palate, uvula extended up to left tonsillar region inferiorly it occupies the right vallecula and touches the epiglottis. Mass moves with deglutition. On palpation, mass is nontender, does not bleeds on touch (Fig. 1).

Neck examination shows bilaterally jugulodigastric nodes measuring  $1 \times 1$  cm in size which were palpable. The rest of her ENT examination was unremarkable.

After discussion with family, a decision was made in favor of surgical excision. Due to large mass in oropharynx, rest of larynx visualization was difficult, hence fiberoptic intubations was done. Uncomplicated complete excision of mass was done. Mass was subjected for histopathological examination (Fig. 2).

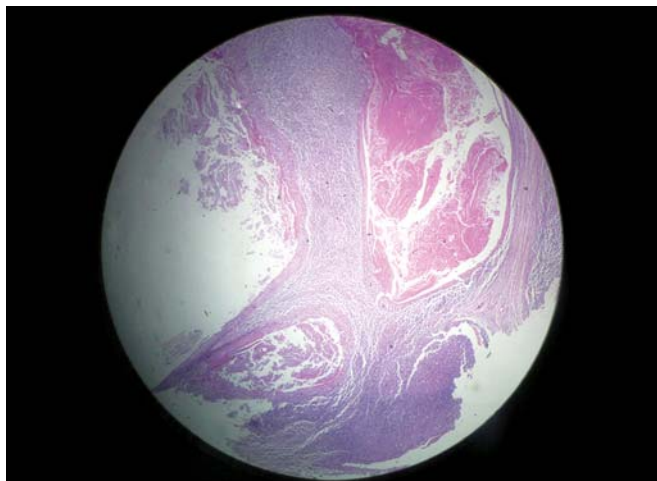
Histopathology report shows, on gross morphology, a single irregular polyp like gray white areas measuring  $5 \times 2 \times 1$  cm. Cut section shows gray to pale white tissue. Microscopy shows tonsil covered by stratified squamous epithelium with papillary pattern and florid lymphoid

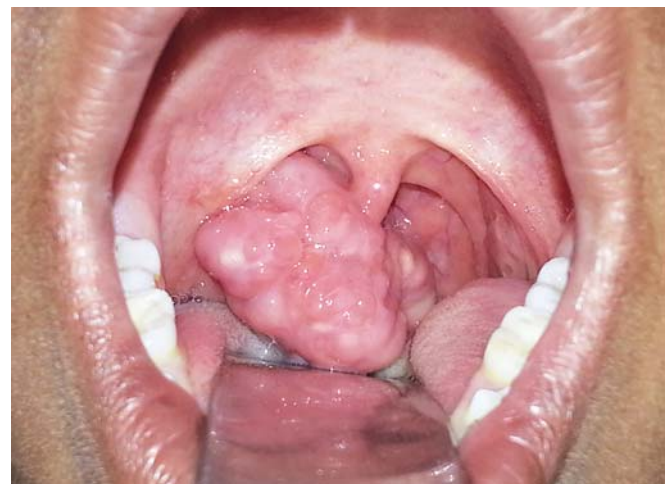

Fig. 1: Polypoidal right tonsil

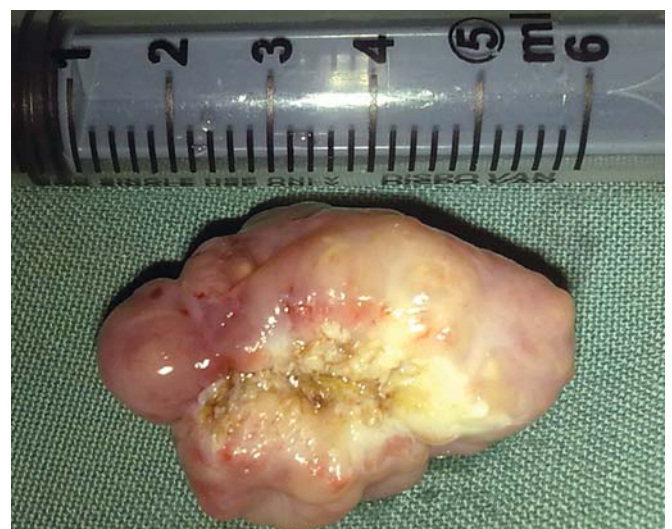

Fig. 2: Surgically excised specimen



**Fig. 3:** Histopathological slide of specimen showing chronic tonsillitis with keratinous cyst

follicular hyperplasia with germinal center. Paracortex shows polymorphous population of lymphoid cells. Areas of keratinous material are seen as cyst at foci. Stalk shows fibrovascular core. Final impression was given as chronic hyperplastic polypoid tonsillitis (Fig. 3).

Follow-up revealed no evidence of recurrence and no new symptoms.

## DISCUSSION

Tonsillar lesion presenting as pedunculated polypoidal mass is relatively rare lesion. Pathophysiologic mechanism underlying large tonsillar polyp is unknown. A small mucosal lesion in tonsillar tissue exposed to pressure change during swallowing and innumerable boluses of swallowed material could cause formation of polyp. Presentations of lesion vary from vague prolonged symptoms to life-threatening episodes of asphyxiation. Patient can present with dysphagia, dysphonia, odynophagia, recurrent episodes of choking sensation.

Polypoid lesions have many different histopathological findings. It is important to consider other neoplastic and non-neoplastic condition that may present as polyp in the differential diagnosis. These include hamartoma, inflammatory polyps, lipomas, hemangiomas, lymphangiomas,<sup>3</sup> schwannomas and other unusual neoplasms, such as carcinoid and chemodectomas.

Histopathology of these lesions show blood vessels, lymphoid cell aggregates, loose fibrous tissues, similar to those in normal tonsil and stalk of polypoidal lesion shows a thick-walled artery with a narrow cavity due to perivascular increase in collagen fiber and smooth muscle hyperplasia. Polyps have poor blood flow and chronic inflammation reflected by dilation of lymph and blood vessels.

Depending on lipomatous, lymphatic, blood vessels detected in lesion polypoid lipoma, lymphangiectatic

fibrolipomatous polyp terminology is used for lesion. Histopathology appears that polyp in original tonsil, such as hamartomatous tonsillar tissues similar to that found in normal tonsil. Based on these findings, these lesions are non-neoplastic rather than truly neoplastic.

Ectopic salivary tissue,<sup>4</sup> meningeal tissue,<sup>5,6</sup> infectious like actinomycosis, heterotopic glial tissue,<sup>7</sup> choristoma with osteocartilaginous,<sup>8</sup> dermoid have been reported in tissues slide.

## CONCLUSION

Once presumptive diagnosis is made, it is crucial to secure the airway and treat the patient as soon as possible to prevent possibility of life-threatening asphyxiation due to airway obstruction. Surgical excision is both curative and diagnostic procedure.

## ACKNOWLEDGMENT

The authors are thankful for all the assistance and support from Dr Sharan Badiger and other staff of BLDEAs Shri BM Patil Medical College, Bijapur, India.

## REFERENCES

- Goldstein A, Tomaski SM. The mouth, pharynx and esophagus. In: Bluestone CD, et al (Eds). Pediatric otolaryngology (4th ed). Philadelphia: WB Saunders 2003:1094-96.
- Seshul MJ, Wiatrak BJ, Galliani CA, Odrezin GT. Pharyngeal fibrovascular polyp in a child. *Ann Otol Rhinol Laryngol* 1988 Sep;107(9):797-800.
- Menarguez J, Mollejo M, Carrion R, et al. Waldeyer's ring lymphomas. A clinicopathological study of 79 cases. *Histopathology* 1994;24:13-22.
- Banerjee AR, Soames JV, Birchall JP, Reikd C, Bray RJ. Ectopic salivary gland tissue in the palatine and lingual tonsil. *Int J Pediatr Otorhinolaryngol* 1993;27:159-62.
- Carrillo-Farga J, Gutierrez-Palomera G, Mandujano M. Neuroglial choristoma of the pharynx. *Ear Nose Throat J* 1988;67:579-80.
- Schulz-Bischof K, Donath K, Hopker WW. Ectopic meningioma of the tonsil. *Pathology* 1994;15:358-60.
- Bhargava D, Raman R, Khalfan-Al-Abri R, Bushnurmah B. Heterotopia of the tonsil. *J Laryngol Otol* 1996;110:611-12.
- Kapoor N, Bhalla J, Pharadwaj VK, Kotgirwar BK. Cartilaginous choristoma of palatine tonsil: A case report. *Indian J Pathol Microbiol* 2003;46:654-55.

## ABOUT THE AUTHORS

### Venkatesh Manikrao Patil (Corresponding Author)

Assistant Professor, Department of ENT, BLDEAs Shri BM Patil Medical College, Bijapur, Karnataka, India, e-mail: venkat27mp@rediffmail.com

### Anirud Vasant Kustagi

Assistant Professor, Department of Pathology, BLDEAs Shri BM Patil Medical College, Bijapur, Karnataka, India

### Rashmi Mallangouda Patil

Senior Resident, Department of Surgery, BLDEAs Shri BM Patil Medical College, Bijapur, Karnataka, India