

Spontaneous Rupture of Pyometra – A Rare Cause of Peritonitis In Elderly Female

VIJAYA PATIL¹, L.S. PATIL², SHOBHA SHIRAGUR³, RAVI ICHALAKARANJI⁴

ABSTRACT

The incidence of spontaneous perforations in pyometra is rare, being 0.01-0.5% in gynaecological patients. However, they are more common in postmenopausal females and their incidence is 13.6%. Here, we are reporting a rare case of peritonitis with a pneumoperitoneum in an elderly female, which was caused by a spontaneous perforation of pyometra. A 74-years old postmenopausal female with uncontrolled diabetes mellitus was admitted to surgical emergency with signs of diffuse peritonitis and she was in shock. After resuscitation, an emergency laparotomy was performed because of suspicion of a hollow viscous perforation with peritonitis. At laparotomy, about 2000ml of purulent fluid was found to be present in peritoneal cavity, while alimentary tract was intact. A rent with a diameter of 0.8 cm was found on fundus of uterus. A total abdominal hysterectomy with a bilateral salpingo oophorectomy was performed. Patient got discharged on 12th post-operative day without major complications. Histopathological studies revealed endometritis and myometritis, with no evidence of malignancy.

Key words: Pyometra, Pneumoperitoneum, Uterine perforation

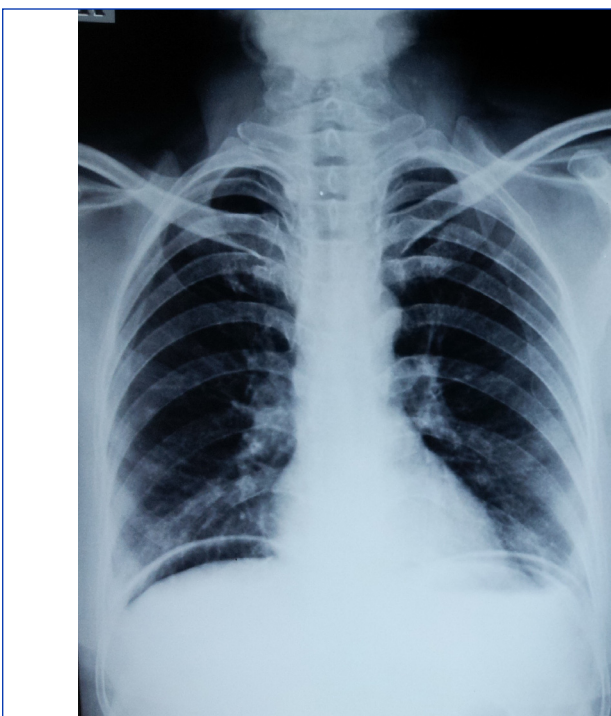
CASE REPORT

A 74-years old postmenopausal female with uncontrolled diabetes mellitus presented with pain in the abdomen, high grade fever which was there since 1 week and distension of abdomen which was there since 3 days, with no vaginal discharge. On systemic examination, she was found to be tachypnoeic, dehydrated and in shock. Diffuse tenderness, guarding and rigidity with an obliterated liver dullness was present on abdominal examination.

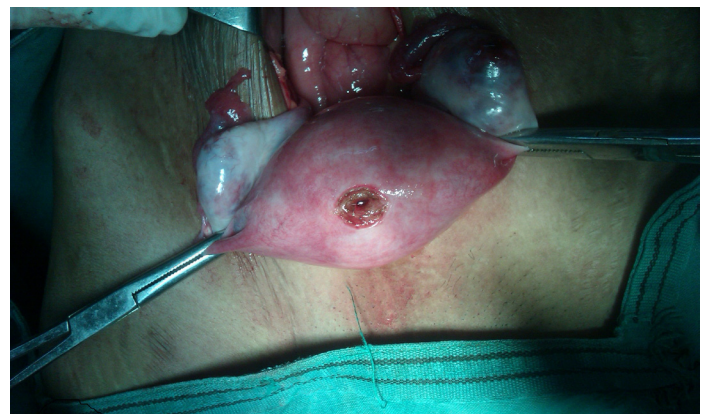Ultrasonography of abdomen revealed free fluid in abdominal cavity and on abdomen radiography, free gas was found under domes of diaphragm [Table/Fig-1]. Based on this picture, a provisional diagnosis of a hollow viscous was made.

After resuscitation, an emergency exploratory laparotomy was done. On laparotomy, 2000 ml of purulent fluid was found to be present in peritoneal cavity. Rest of alimentary tract, gall bladder and liver were normal. During peritoneal lavage, we found a perforation with a diameter of 0.8 cm over fundus of the uterus [Table/Fig-2].

After taking consent of patient's attender, an abdominal hysterectomy with a bilateral salpingo-oophorectomy was done. Cut-section of uterus revealed a necrotic patch at fundus, with no evidence of a mass or cervical stenosis. Post-operative recovery was uneventful and patient got discharged on 12th post-operative day. Histopathological studies revealed suppurative endometritis and myometritis, with no evidence of malignancy.



[Table/Fig-1]: Clinical X-ray



[Table/Fig-2]: Per Operative

DISCUSSION

Pyometra is defined as an accumulation of pus in uterine cavity. Spontaneous perforation of uterus is a rare complication of pyometra, its incidence being 0.01-0.5% [1]. The most common cause of pyometra is malignancy of genital tract and sequelae of radiotherapy [2]. Other benign causes are cervical polyps, senile cervicitis, leiomyoma and congenital anomalies of cervix.

Spontaneous perforation of uterus is a rare complication of pyometra. Only less than 25 cases have been reported in English

literature [3-4] since 1985. The causes of a pneumoperitoneum with peritonitis without a gastrointestinal tract perforation, are a perforated pyometra, a perforated liver abscess and a ruptured necrotic liver metastasis [5]. Pneumoperitoneum which was associated with a perforated pyometra was recognized only in 56% of cases. In most of the cases, a diagnosis of a perforated pyometra was made intra-operatively, where suspected diagnosis was a gastrointestinal perforation [6]. The cases of perforated pyometra which are not associated with malignancies have better prognoses than those which are associated with malignancies [7] as in our case. Mortality from spontaneously perforated pyometra exceeds 40%. It highlights the importance of a multidisciplinary involvement in treating sepsis [8].

CONCLUSION

A diagnosis of a perforated pyometra should always be kept in mind as a possible cause of peritonitis with a pneumoperitoneum in elderly women who present with acute abdomens, although it is a rare entity. A ruptured pyometra which presents as diffuse peritonitis, carries a high risk of mortality and morbidity due to lack of specific diagnostic modalities. This makes the management difficult.

Abdominal hysterectomy with bilateral salpingo-oophorectomy with copious peritoneal lavage, may be the procedure of choice in these patients.

REFERENCES

- [1] Iwase F, Shimizu H, Koike H, Yasutomi T. Spontaneously perforated pyometra presenting as diffuse peritonitis in older females at nursing homes. *J Am Geriatr Soc*. 2001 Jan;49(1):95-96.
- [2] IM Shapey, T Nasser, P Dickens, M Haldar, MH Solkar. Spontaneously perforated pyometra an unusual cause of acute abdomen and pneumoperitoneum. *Ann R Coll Surg Engl*. 2012; 94; e246-e248.
- [3] Shahid N, Khan H, Onon TS. Perforation of pyometra leading to diffuse peritonitis is not necessarily iatrogenic. *J Obstet Gynaecol*. 2006 Jan; 26(1):76-77.
- [4] Geranpayeh L, Fadaei-Araghi M, Shakiba B. Spontaneous uterine perforation due to pyometra presenting as acute abdomen. *Infect Dis Obstet Gynaecol*. 2006;2006:60276.
- [5] Omori H, Asahi H, Inoue Y, Irinoda T, Saito K. Pneumoperitoneum without Perforation of Gastrointestinal tract. *Dig Surg*. 2003;20:334-38.
- [6] Chan LY, Yu VS, Ho LC, Lok YH, Hui SK. Spontaneous uterine perforation of pyometra. A report of three cases. *J Reprod Med*. 2000 Oct;45(10):857-60.
- [7] Inui A, Nitta A, Yamamoto A, Kanq SM, Kanehara I, et al. Generalised peritonitis with pneumoperitoneum caused by spontaneous perforation of pyometra without malignancy: report of a case. *Surg Today*. 1999;29(9):935-38.
- [8] Qu YC, Lan KC, Lin H, et al. Clinical characteristics of perforated pyometra and impending perforation: specific issues in gynecological emergency. *J Obstet Gynaecol Res*. 2010; 36:661-66.

PARTICULARS OF CONTRIBUTORS:

1. Professor, Department of General Surgery, Shri B.M. Patil Medical College, Bijapur, Karnataka - 586103, India.
2. Professor, Department of General Medicine, Shri B.M. Patil Medical College, Bijapur, Karnataka - 586103, India.
3. Assistant Professor, Department of Obstetrics and Gynaecology, Shri B.M. Patil Medical College, Bijapur, Karnataka - 586103, India.
4. PG Cum Junior Resident, Department of General Surgery, Shri B.M. Patil Medical College, Bijapur, Karnataka - 586103, India.

NAME, ADDRESS, E-MAIL ID OF THE CORRESPONDING AUTHOR:

Dr. Vijaya Patil,
Professor, Department of General Surgery, Shri B.M. Patil Medical College, Bijapur, Karnataka - 586103, India.
Phone: 09035781291, E-mail: drvijayapatil@yahoo.com

Date of Submission: **Dec 03, 2012**
Date of Peer Review: **May 24, 2013**
Date of Acceptance: **Jun 23, 2013**
Date of Publishing: **Aug 01, 2013**

FINANCIAL OR OTHER COMPETING INTERESTS: None.