

# CASE REPORT

---

## PETER'S TYPE II ANOMALY ASSOCIATED WITH CONGENITAL HEART DEFECT: RARE CASE REPORT

Darshan Kumar U. Kansara<sup>1</sup>, Sunil G. Biradar<sup>2</sup>

### HOW TO CITE THIS ARTICLE:

Darshan Kumar U. Kansara, Sunil G. Biradar. "Peter's Type II Anomaly Associated with Congenital Heart Defect: Rare Case Report". Journal of Evidence based Medicine and Healthcare; Volume 2, Issue 10, March 09, 2015; Page: 1565-1568.

**ABSTRACT: PURPOSE:** Reporting a case of Peters' type II with congenital heart defect a rare form of anterior segment dysgenesis in which abnormal cleavage of the anterior chamber occurs. It is characterized by central corneal opacification secondary to defects in a posterior corneal stroma, Descemet's membrane, and endothelium. Majority of cases are sporadic, bilateral, and associated with other systemic malformations. **MATERIAL AND METHOD:** A 18 year old female presented with a history of bilateral cloudy corneas and diminution of vision since early childhood. Visual acuity was OD 6/60, OS 6/60 with PH improvement in OU 6/36. Slit lamp examination showed BE micro cornea with central and paracentral macular grade opacity with lenticulo-irido-corneal adhesions. Iris was found to be fused with the posterior surface of the peripheral cornea with poor formation of the anterior chamber with coloboma of iris. Lens was cataractous. Fundus examination in the left eye showed no abnormality. She was diagnosed as Peters' type II anomaly. Systemic examination revealed congenital heart defects. Echocardiography showed congenital bicuspid aortic valve, grade 3 aortic regurgitation. **RESULT:** Patient require penetrating keratoplasty with combined procedure (Cataract extraction with trabeculectomy). **CONCLUSION:** Early detection of the disease will help in early treatment, with good vision development to combat amblyopia.

**KEYWORDS:** peters' type II anomaly, anterior segment dysgenesis, microcornea, congenital heart defect.

**INTRODUCTION:** Peters' anomaly is a rare form of anterior segment dysgenesis in which abnormal cleavage of the anterior chamber occurs. Peters' anomaly may be caused by incomplete migration and differentiation of the precursor cells of the central corneal endothelium and descemet membrane or a defective separation between the primitive lens and cornea during embryogenesis.<sup>1</sup> It is defined as a congenital central corneal opacity with corresponding defects in the posterior corneal stroma, Descemet's membrane, and endothelium leading to Peter's type I. Peters' type II in addition will have lens abnormalities and tend to be bilateral. 60% of those with Peters' anomaly are bilateral. In both forms, opacification of the cornea leads to an amblyogenic effect on a developing infant and carries high risk early onset glaucoma. Peters' anomaly may be associated with other ocular or systemic abnormalities like microphthalmos, colobomata, retinal and optic nerve dysplasia, microcornea, developmental delay, central nervous system defects, craniofacial abnormalities, seizure disorders, genitourinary malformations, and cardiopulmonary defects.<sup>2</sup> Sporadic, autosomal dominant, and autosomal recessive forms have been described.<sup>3</sup>

# CASE REPORT

---

A small number of cases have been described with mutations in PAX6 gene, RIEG1 gene, and other genes.

**CASE REPORT:** An 18 year female presented with a history of bilateral cloudy corneas and diminution of vision since early childhood. Parents noticed gradually progressing corneal opacity and diminution of vision in both eyes for distance and for near.

Her ocular examination revealed Visual acuity was RE 6/60, LE 6/60 with PH improvement in BE 6/36. Near visual acuity in BE was N 24.

Slit lamp examination showed BE microcornea (8.4 X 8.6 mm) with central and paracentral macular grade opacity with lenticulo-irido-corneal adhesion (Figure 1 & 2). Whole of the cornea was involved leaving peripheral 2 mm of cornea clear. Bilateral multiple temporal and nasal iridocorneal adhesions could be appreciated with iris colobomapostessorsynechia (Figure 3). poorly formed anterior chamber and cataractous lens. IOP measured by applanation tonometry was 20 mm Hg in OD and 18 mm Hg in OS. Gonioscopic examination of the angle revealed ill-defined angle structure over 3/4 of the angle circumference (Figure 4). Fundus examination in the left eye showed no abnormality. A diagnosis of Peter's type II anomaly was made. Systemic examination of respiratory, central nervous system was normal but cardiac examination revealed congenital heart defects. Echocardiography showed congenital bicuspid aortic valve and grade 3 aortic regurgitation.

**DISCUSSION:** Peters' Anomaly occurs with various ophthalmological findings, mainly iridolenticular contact, keratolenticular contact, cataracts, glaucoma and variations in the globe volume.<sup>4</sup> A variant of Peters' anomaly has been described involving the lens. This has been termed as Peter's type II or Peters' anomaly with corneo lenticular contact or cataract.<sup>1</sup>

Most cases of Peter's anomaly are sporadic, although reports of parental consanguinity and more than one affected sibling support an autosomal recessive or irregularly dominant mode of inheritance in some cases. Our patient is sporadic.

Systemic abnormalities include congenital heart defects, hydrocephalus, and renal dysgenesis.<sup>5</sup>

Mesenchymal cells which differentiate into corneal endothelium, stroma, iris, and aqueous outflow structure have been proved to be derived from neural crest cells by histochemical method.<sup>6</sup> Bahn et al suggested that corneal endothelial disorders, Peter's anomaly, congenital glaucoma, posterior embryotoxon, Axenfeld's anomaly, Rieger's anomaly, and sclerocornea result from abnormal neural crest cell migration.<sup>7</sup> Thus, in most cases of Peter's anomaly and of Axenfeld's anomaly the pathogenesis is related to abnormal migration of neural crest cells.

Bilateral Peters' anomaly has a stronger association (71.8%) with systemic malformation.<sup>8</sup> In another study by Mayer.<sup>9</sup> and Heon ET al.<sup>10</sup> published two series of cases with Peters' anomaly. About 60% of cases had non-ocular abnormalities, 25% of the cases had cardiac defects, 30% had CNS abnormalities and an additional 20% had developmental delay. In our case, bilateral micro cornea with central and paracentral opacity with cataract and congenital heart defect was seen.

# CASE REPORT

---

Patient will require penetrating keratoplasty with combined procedure (Cataract extraction with trabeculectomy) with guarded visual prognosis.

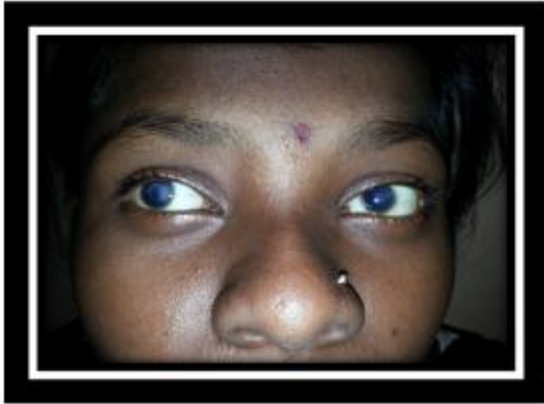**CONCLUSION:** Peter's anomaly is a rare disease in ophthalmic practice; however, its early detection and treatment are important to reduce the risk of visual impairment. We believe that removal of the opacity by penetrating keratoplasty and cataract surgery to obtain clear visual axis and improved visual function.

**ACKNOWLEDGMENTS:** I am very thankful to my patient for kind co-operation. I am very grateful to my staff for their constant support and as well as support from Shri B.M. Patil Medical College and research institute, Bijapur.

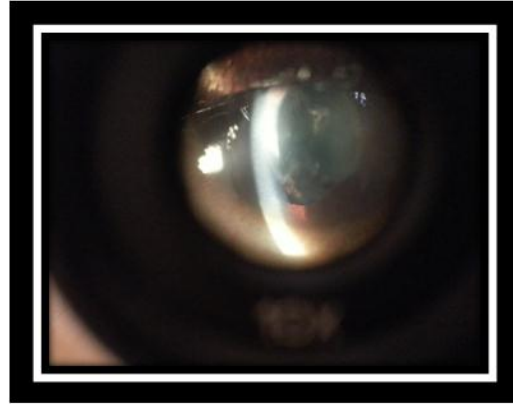
## REFERENCES:

1. Shwaky RM, Sadik DI. Abnormal presentation of Peters' anomaly in a family with micro cornea cataract syndrome. *Egypt. J. Med. Hum. Genet.* 2009; 10:111-114.
2. Park SJ, Byun JL, Lee ST, Shin KC, Kim MH. A Case of Peters' Anomaly. *Korean J Perinatol.* 2007; 18:298-302.
3. Holmstrom GE, Reardon WP, Baraitser M, Elston JS, Taylor DS. Heterogeneity in dominant anterior segment malformations. *Br J Ophthalmol* 1991; 75:591-597.
4. Bateman JB, Maumenee IH, Sparkes RS. Peters' anomaly associated with partial deletion of the long arm of chromosome 11. *Am J Ophthalmol.* 1984; 97:11-15.
5. Tuli N, Kumar S, Sood S. Peters plus syndrome and absence of kidney: a case report. *Cases Journal* 2009, 2:2. Doi: 10.1186/1757-1626-2-2. (Accessed on 19 Feb 2015).
6. Beauchamp GR, Knepper PA. Role of the neural crest in anterior segment development and disease. *J PediatrOphthalmol Strabismus* 1984; 21: 209-214.
7. Bahn CF, Falls HF, Varley GA et al: Classification of corneal endothelial disorders based on neural crest origin. *Ophthalmology* 1984; 91:558.
8. Bhandari R, Ferri S, Whittaker B, Liu M, Lazzaro DR. Peters' anomaly: review of the literature. *Cornea.* 2011; 30:939-44. doi:10.1097/ICO.0b013e31820156a9. (Accessed on 19 Feb 2015).
9. Mayer UM. Peters' anomaly and combination with other malformations (series of 16 patients). *Ophthalmic Paediatr. Genet.* 1992; 13(2): 131-5.
10. Heon E, BarsoumHomsy M, Cevrette L, Jacob JL, Milot J, Polemeno R, et al. Peters' anomaly. The spectrum of associated ocular and systemic malformations. *Ophthalmic Paediatr. Genet.* 1992; 13 (2): 137-43.

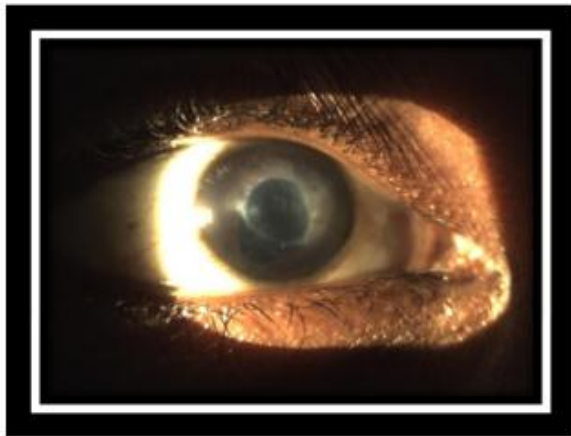
# CASE REPORT




**Fig. 1: Bilateral corneal opacity**



**Fig. 2: Lenticulo-irido-corneal**



**Fig. 3: Iris coloboma with synechiae**



**Fig. 4: Ill-defined angle structure on gonioscopy examination**

## **AUTHORS:**

1. Darshan Kumar U. Kansara
2. Sunil G. Biradar

## **PARTICULARS OF CONTRIBUTORS:**

1. Post Graduate, Department of Ophthalmology, Shri B. M. Patil Medical College & Research Centre, Bijapur.
2. Professor, Department of Ophthalmology, Shri B. M. Patil Medical College & Research Centre, Bijapur.

## **NAME ADDRESS EMAIL ID OF THE CORRESPONDING AUTHOR:**

Dr. Darshan U. Kansara,  
B-27, NRI PG Hostel,  
Shri B. M. Patil Medical College  
& Research Centre,  
Bijapur- 556103.  
E-mail: kdarshan83@yahoo.com

Date of Submission: 26/02/2015.  
Date of Peer Review: 27/02/2015.  
Date of Acceptance: 02/03/2015.  
Date of Publishing: 09/03/2015.