

Indian Journal of Dermatology, Venereology & Leprology

Vol 74 | Issue 1 | Jan-Feb 2008

The Indian Journal of Dermatology, Venereology and Leprology (IJDL)

is a bimonthly publication of the Indian Association of Dermatologists, Venereologists and Leprologists (IADVL) and is published for IADVL by Medknow Publications.

The Journal is **indexed/listed** with Science Citation Index Expanded, PUBMED, EMBASE, Bioline International, CAB Abstracts, Global Health, DOAJ, Health and Wellness Research Center, SCOPUS, Health Reference Center Academic, InfoTrac One File, Expanded Academic ASAP, NIWI, INIST, Uncover, JADE (Journal Article Database), IndMed, Indian Science Abstract's and PubList.

All the rights are reserved. Apart from any fair dealing for the purposes of research or private study, or criticism or review, no part of the publication can be reproduced, stored, or transmitted, in any form or by any means, without the prior permission of the Editor, IJDL.

The information and opinions presented in the Journal reflect the views of the authors and not of the IJDL or its Editorial Board or the IADVL. Publication does not constitute endorsement by the journal.

The IJDL and/or its publisher cannot be held responsible for errors or for any consequences arising from the use of the information contained in this journal.

The appearance of advertising or product information in the various sections in the journal does not constitute an endorsement or approval by the journal and/or its publisher of the quality or value of the said product or of claims made for it by its manufacturer.

The journal is published and distributed by Medknow Publications. Copies are sent to subscribers directly from the publisher's address. It is illegal to acquire copies from any other source. If a copy is received for personal use as a member of the association/society, one can not resale or give-away the copy for commercial or library use.

The Journal is printed on acid free paper.

EDITOR

Uday Khopkar

ASSOCIATE EDITORS

Ameet Valia Sangeeta Amladi

ASSISTANT EDITORS

K. C. Nischal Sushil Pande Vishalakshi Viswanath

EDITORIAL BOARD

Chetan Oberai (Ex-officio)	Koushik Lahiri (Ex-officio)	Sanjeev Handa
Arun Inamdar	Joseph Sundharam	S. L. Wadhwa
Binod Khaitan	Kanthraj GR	Sharad Mutalik
D. A. Satish	M. Ramam	Shruthakirti Sheno
D. M. Thappa	Manas Chatterjee	Susmit Halder
H. R. Jerajani	Rajeev Sharma	Venkatram Mysore
	Sandipan Dhar	

EDITORIAL ADVISORY BOARD

Aditya Gupta, Canada	Jag Bhawan, USA
C. R. Srinivas, India	John McGrath, UK
Celia Moss, UK	K. Pavithran, India
Giam Yoke Chin, Singapore	R. G. Valia, India
Gurmohan Singh, India	Robert A. Schwartz, USA
Howard Libman, USA	Robin Graham-Brown, UK
J. S. Pasricha, India	V. N. Sehgal, India
Rodney Sinclair, Australia	

STATISTICAL EDITOR

S. R. Suryawanshi

OMBUDSMAN

A. K. Bajaj

IADVL NATIONAL EXECUTIVE 2006 – 2007

President

Chetan M. Oberai

Immediate Past President

Suresh Joshipura

President (Elect)

S. Sacchidanand

Vice-Presidents

Amrinder Jit Kanwar

Dilip Shah

Secretary

Koushik Lahiri

Treasurer

Arijit Coondoo

Jt. Secretaries

Rakesh Bansal

Manas Chatterjee

EDITORIAL OFFICE

Dr. Uday Khopkar

Editor, IJDL, Department of Dermatology,
117, 1st Floor, Old OPD Building, K.E.M.
Hospital, Parel, Mumbai - 400012, India.
E-mail: editor@ijdv.com

Published for IADVL by

MEDKNOW PUBLICATIONS

A-109, Kanara Business Centre, Off Link Road,
Ghatkopar (E), Mumbai - 400075, India.
Tel: 91-22-6649 1818 / 1816
Website: www.medknow.com

www.ijdv.com
www.journalonweb.com/ijdv
www.bioline.org.br/dv

Indian Journal of Dermatology, Venereology & Leprology

Journal indexed with SCI-E, PubMed, and EMBASE

Vol 74 | Issue 1 | Jan-Feb 2008

C O N T E N T S

EDITORIAL REPORT - 2007

IIDVL gets into the Science Citation Index Expanded!

Uday Khopkar 1

EDITORIAL

Registration and reporting of clinical trials

Uday Khopkar, Sushil Pande 2

SPECIALTY INTERFACE

Preventing steroid induced osteoporosis

Jyotsna Oak 5

REVIEW ARTICLE

Molecular diagnostics in genodermatoses - simplified

Ravi N. Hiremagalore, Nagendrachary Nizamabad, Vijayaraghavan Kamasamudram 8

ORIGINAL ARTICLES

A clinicoepidemiological study of polymorphic light eruption

Lata Sharma, A. Basnet 15

A clinico-epidemiological study of PLE was done for a period of one year to include 220 cases of PLE of skin type between IV and VI. The manifestation of PLE was most common in house wives on sun exposed areas. Most of the patients of PLE presented with mild symptoms and rash around neck, lower forearms and arms which was aggravated on exposure to sunlight. PLE was more prevalent in the months of March and September and the disease was recurrent in 31.36% of cases.

Comparative study of efficacy and safety of hydroxychloroquine and chloroquine in polymorphic light eruption: A randomized, double-blind, multicentric study

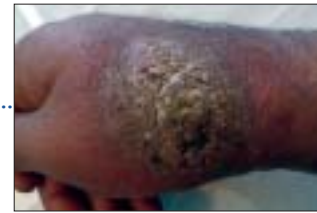Anil Pareek, Uday Khopkar, S. Sacchidanand, Nitin Chandurkar, Geeta S. Naik 18

In a double-blind randomized, comparative multicentric study evaluating efficacy of antimalarials in polymorphic light eruption, a total of 117 patients of PLE were randomized to receive hydroxychloroquine and chloroquine tablets for a period of 2 months (initial twice daily dose was reduced to once daily after 1 month). A significant reduction in severity scores for burning, itching, and erythema was observed in patients treated with hydroxychloroquine as compared to chloroquine. Hydroxychloroquine was found to be a safe antimalarial in the dosage studied with lesser risk of ocular toxicity.

Many faces of cutaneous leishmaniasis

Arfan Ul Bari, Simeen Ber Rahman

Symptomatic cutaneous leishmaniasis is diverse in its presentation and outcome in a tropical country like Pakistan where the disease is endemic. The study describes the clinical profile and atypical presentations in 41 cases among 718 patients of cutaneous leishmaniasis. Extremity was the most common site of involvement and lupoid cutaneous leishmaniasis was the most common atypical form observed. Authors suggest that clustering of atypical cases in a geographically restricted region could possibly be due to emergence of a new parasite strain.

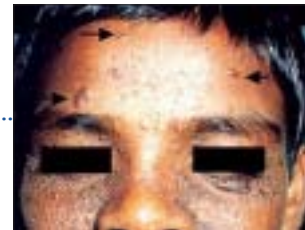

23

Forehead plaque: A cutaneous marker of CNS involvement in tuberous sclerosis

G. Raghu Rama Rao, P. V. Krishna Rao, K. V. T. Gopal, Y. Hari Kishan Kumar, B. V. Ramachandra

In a retrospective study of 15 patients of tuberous sclerosis, eight patients had central nervous system involvement. Among these 8 cases, 7 cases had forehead plaque. This small study suggests that presence of forehead plaque is significantly associated with CNS involvement.

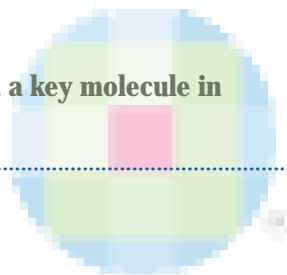


28

BRIEF REPORTS

Ligand-binding prediction for ErbB2, a key molecule in the pathogenesis of leprosy

Viroj Wiwanitkit.....



32

SCORTEN: Does it need modification?

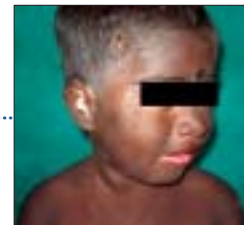Col. S. S. Vaishampayan, Col. A. L. Das, Col. R. Verma

35

CASE REPORTS

Universal acquired melanosis (Carbon baby)

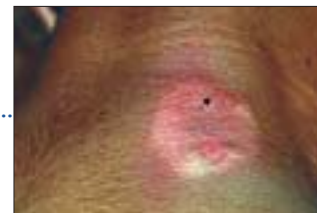P. K. Kaviarasan, P. V. S. Prasad, J. M. Joe, N. Nandana, P. Viswanathan



38

Adult onset, hypopigmented solitary mastocytoma: Report of two cases

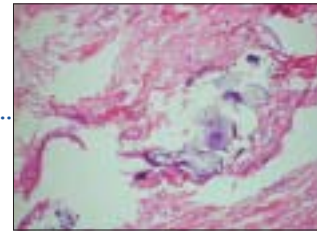
D. Pandhi, A. Singal, S. Aggarwal.....



41

Incidental finding of skin deposits of corticosteroids without associated granulomatous inflammation: Report of three cases

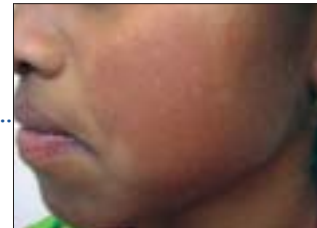Rajiv Joshi



44

**Erythromelanosis follicularis faciei *et* colli:
Relationship with keratosis pilaris**

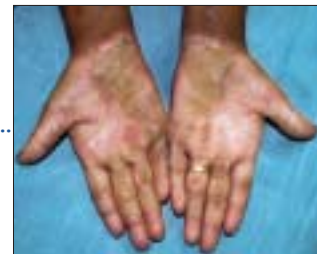M. Augustine, E. Jayaseelan



47

Naxos disease: A rare occurrence of cardiomyopathy with woolly hair and palmoplantar keratoderma

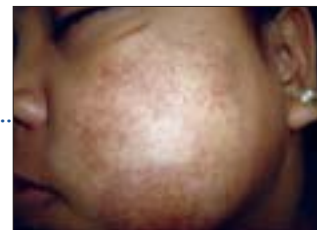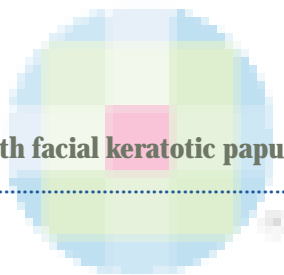
R. Rai, B. Ramachandran, V. S. Sundaram, G. Rajendren, C. R. Srinivas



50

Granular parakeratosis presenting with facial keratotic papules

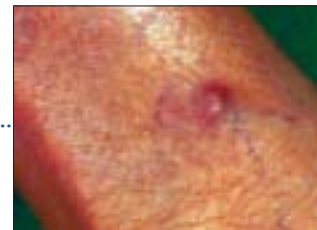R. Joshi, A. Taneja



53

Adult cutaneous myofibroma

V. Patel, V. Kharkar, U. Khopkar

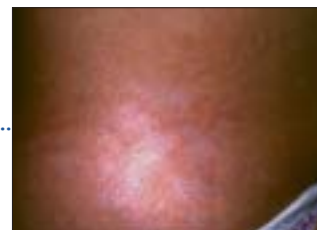

56

LETTERS TO THE EDITOR

Extragenital lichen sclerosus of childhood presenting as erythematous patches

N. G. Stavrianeas, A. C. Katoulis, A. I. Kanelleas, E. Bozi, E. Toumbis-Ioannou



59

Leukocytoclastic vasculitis during pegylated interferon and ribavirin treatment of hepatitis C virus infection

Esra Adisen, Murat Dizbay, Kenan Hize, Nilsel İltter

60

Poland's syndrome

Saurabh Agarwal, Ajay Arya..... 62

Hereditary leiomyomatosis with renal cell carcinoma

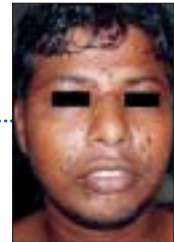Sachin S. Soni, Swarnalata Gowrishankar, Gopal Kishan Adikey,
Anuradha S. Raman 63

Infantile onset of Cockayne syndrome in two siblings

Prerna Batra, Abhijeet Saha, Ashok Kumar 65

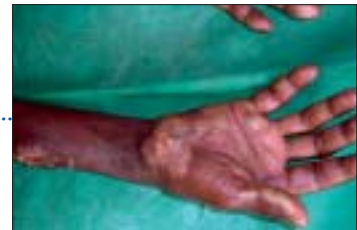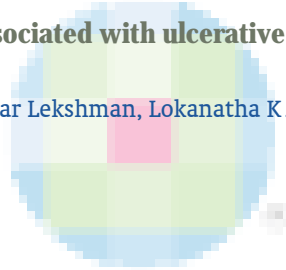Multiple xanthogranulomas in an adult

Surajit Nayak, Basanti Acharjya, Basanti Devi, Manoj Kumar Patra 67



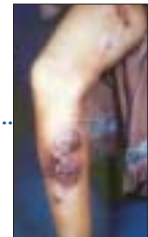Bullous pyoderma gangrenosum associated with ulcerative colitis

Naik Chandra Lal, Singh Gurcharan, Kumar Lekshman, Lokanatha K..... 68



Sporotrichoid pattern of malignant melanoma

Ranjan C. Rawal, Kanu Mangla..... 70

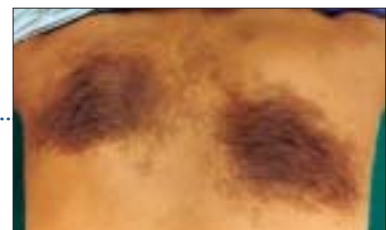

Acitretin for Papillon-Lefèvre syndrome in a five-year-old girl

Didem Didar Balci, Gamze Serarslan, Ozlem Sangun, Seydo Homan 71

Bilateral Becker's nevi

Ramesh Bansal, Rajeev Sen..... 73



RESIDENTS' PAGE

Madarosis: A dermatological marker

Silonie Sachdeva, Pawan Prasher 74

FOCUS

Botulinum toxin

Preeti Savardekar 77

E-IJDVL

Net Studies

A study of oxidative stress in paucibacillary and multibacillary leprosy

P. Jyothi, Najeeba Riyaz, G. Nandakumar, M. P. Binitha 80

Clinical study of cutaneous drug eruptions in 200 patients

M. Patel Raksha, Y. S. Marfatia 80

Net case

Porokeratosis confined to the genital area: A report of three cases

Sujata Sengupta, Jayanta Kumar Das, Asok Gangopadhyay 80

Net Letters

Camisa disease: A rare variant of Vohwinkel's syndrome

T. S. Rajashekar, Gurcharan Singh, Chandra Naik, L. Rajendra Okade 81

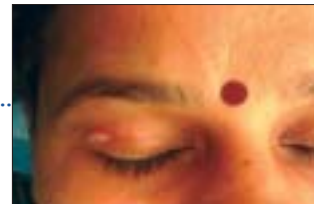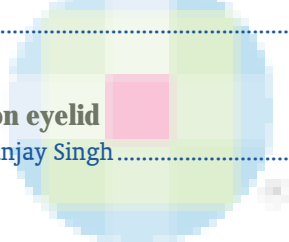
Cross reaction between two azoles used for different indications

Arika Bansal, Rashmi Kumari, M. Ramam 81

Net Quiz

Asymptomatic erythematous plaque on eyelid

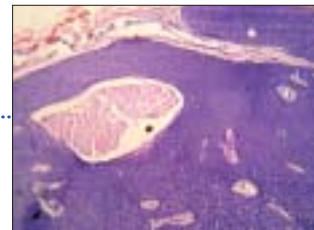Neeraj Srivastava, Lakhan Singh Solanki, Sanjay Singh 82



QUIZ

A bluish nodule on the arm

Ragunatha S., Arun C. Inamadar, Vamseedhar Annam, B. R. Yelikor 83



REFEREE INDEX-2007

INSTRUCTIONS FOR AUTHORS

Quiz

A bluish nodule on the arm

A 21-year-old male presented with an asymptomatic, slow-growing swelling on the left arm of 4 years duration. He gave history of expression of black-colored fluid and, sometimes, blood when punctured. On examination, solitary, sessile, globular, well-circumscribed bluish nodule, measuring 2 cm in diameter, was present on the lower part of his left arm [Figure 1]. The surface of the nodule was smooth, with visible

superficial vessels. On palpation, the nodule was freely mobile, nontender and soft in consistency, with firm base. An excisional biopsy showed a single cyst (3 mm) containing black-colored material. Histopathological features are shown in Figures 2-3.

WHAT IS YOUR DIAGNOSIS?

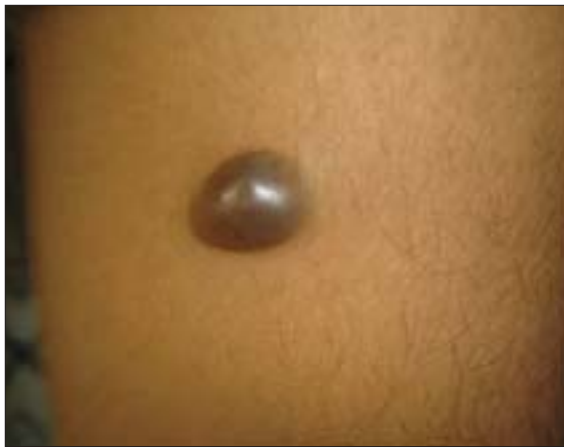

Figure 1: Well-demarcated round bluish nodule on the arm

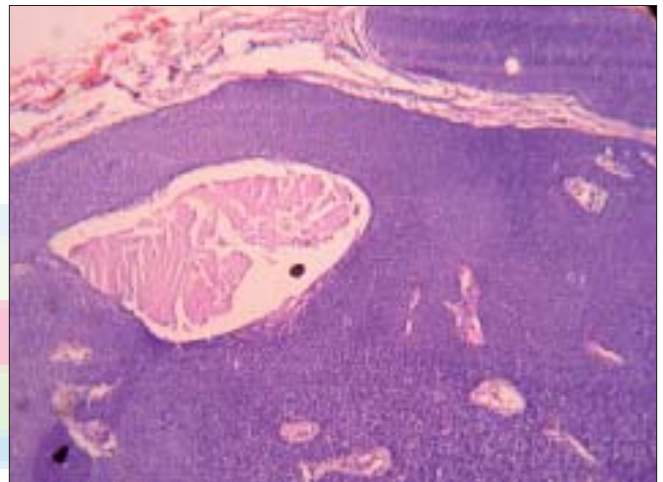


Figure 3: Tumor cells arranged in lobules separated by fibrovascular septae (H and E stain, X100)

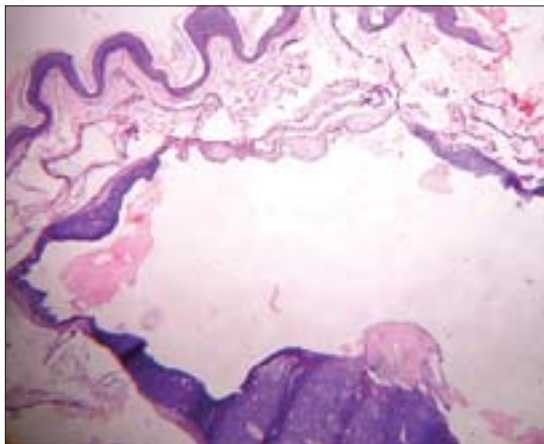


Figure 2: Tumor containing solid areas and cystic spaces separated from thin epidermis (H and E stain, x40)

How to cite this article: Ragunatha S, Arun CI, Vamseedhar A, Yelikar BR. Indian J Dermatol Venereol Leprol 2008;74:83-5.

Received: November, 2006. **Accepted:** April, 2007. **Source of Support:** Nil. **Conflict of Interest:** None declared.

Diagnosis: Nodular hidradenoma

Histopathology showed well-circumscribed tumor with solid and cystic areas [Figure 2], arranged in lobules separated by thin fibrovascular septae [Figure 3]. Two types of tumor cells were seen. One was oval-to-polyhedral with round-to-oval basophilic nucleus and moderate amount of eosinophilic cytoplasm. The other was round-to-oval with small hyperchromatic nucleus, and moderate amount of pale cytoplasm was also seen within the tumor. There were cystic spaces of varying sizes containing mucinous material lined by single-to-multilayered cuboidal epithelium. At some areas, degenerating tumor cells secreting their contents into the cystic spaces were noted.

DISCUSSION

Nodular hidradenomas (NHs) are primitive adnexal tumors that show differentiation towards eccrine and apocrine apparatus.^[1] Clinically, NH presents as slow-growing, firm, solitary, bluish-red mobile nodule, mainly situated over scalp, face, trunk and occasionally on the extremities.^[2] Rarely, it may be cystic, pedunculated or ulcerated.^[3] The size of the nodule varies from 5 to 30 mm in diameter.^[1] However, a size up to 10 cm has been reported.^[3] The overlying skin is stretched and atrophic with visible surface vasculature.^[4-6] NH is usually seen in adults with an average age of 37.2 years and a female-to-male ratio of 1.7:1.^[7] Though usually seen between the fourth and eighth decade of the life, cases have been reported in young children.

Since there are no specific features to diagnose NH clinically, the histopathological study is essential for the correct diagnosis. Microscopically, NH is a circumscribed noncapsulated dermal tumor, sometimes extending into the subcutaneous tissue, with solid areas, cystic spaces and tubular lumina. The solid area is characterized by three types of cells: polyhedral cells with round nucleus and basophilic cytoplasm, similar to cuboidal ductal cells; fusiform cells with elongated nucleus located at the periphery of the tumor, representing myoepithelial cells; and round cells with small dark nucleus and clear cytoplasm, representing secretory coil cells. Occasionally there may be foci of squamoid differentiation with horn pearls, representing intraepidermal ductal cells.^[8] Similarly, tubular lumina are also lined by four types of cells representing cells of different parts of the sweat gland.^[3] Often there are cystic spaces of considerable size bordered by tumor cells. Formation of these cystic spaces is attributed to the degeneration of tumor cells. Sometimes, tumor nodules show areas of

eosinophilic hyalinized stroma.^[8] Other cellular variants include oncocytic, epidermoid and pigmented variants with melanocytes and melanin pigment in the cells and macrophages.^[9]

Multiple foci of growth, atypical mitoses, zonal necrosis and invasion of vascular and perineural sheath indicate the possibility of hidradenocarcinoma.^[11] Histologically, tricholemmoma also shows clear cells. However, tricholemmoma shows peripheral palisading of tumor cells with the absence of cystic spaces and tubular structures.^[8]

On fine needle aspiration cytology (FNAC), NH is usually misdiagnosed as breast carcinoma when it presents as breast lump with ulceration^[10] and as cutaneous metastasis of conventional-type renal cell carcinoma.^[11] Since such cases are usually referred to FNAC, the knowledge of cytological features of NH can aid in the proper diagnosis of the condition. On FNAC, NH is diagnosed by the presence of many clear cells amidst polygonal tumor cells.^[10] NH may also arise from nevus sebaceous as a result of dysembryoplasia^[12] and from mammary duct as subareolar nodule with nipple discharge.^[13]

NH is a benign tumor but malignant transformation with metastasis has been reported.^[14] Local recurrences can occur if the tumor is incompletely excised.^[9] Though mitoses do not necessarily indicate the malignancy, their presence is associated with increased local recurrences and subsequent malignant transformation.^[9] Surgical excision is the recommended treatment.^[14]

**Ragunatha S., Arun C. Inamadar,
Vamseedhar Annam*, B. R. Yeliker***

Departments of Dermatology, Venereology and Leprosy, and
*Pathology, BLDEA's SBMP Medical College, Hospital and Research
Centre, Bijapur, Karnataka, India

**Address for correspondence: Dr. Arun C. Inamadar, Department
of Dermatology, Venereology and Leprosy, BLDEA's SBMP Medical
College, Hospital and Research Centre, Bijapur - 586 103, Karnataka,
India. E-mail: aruninamadar@rediffmail.com**

REFERENCES

- Smoller BR, Coldiron B. Neoplasms with eccrine or apocrine differentiation. *In*: Arndt KA, LeBoit PE, Robinson JK, Wintroub BU, editors. Cutaneous medicine and surgery. 1st ed. W.B. Saunders Company: Philadelphia; 1996. p. 1476-91.
- Kaddu S, Kerl H. Appendage tumors of the skin. *In*:

- Freedberg IM, Eisen AZ, Wolff K, Austen KF, Goldsmith LA, Katz SI, editors, Fitzpatrick's Dermatology in internal medicine. 6th ed. McGraw-Hill: New York; 2003. p. 785-809.
- Hampton MT, Sahn EE. Recurrent draining cyst on the shoulder: Clear cell hidradenoma (CCH) (nodular hidradenoma). *Arch Dermatol* 1992;128:1531,1533-4.
 - Warter A, Diolombi G. Sweat gland tumors in Nigeria: Anatomopathology. *Ann Dermatol Venereol* 1989;116:621-7.
 - Faulhaber D, Worle B, Trautner B, Sander CA. Clear cell hidradenoma in a young girl. *J Am Acad Dermatol* 2000;42:693-5.
 - Ozawa T, Fuziwora M, Nose K, Muraoka M. Clear cell hidradenoma of the forearm in a young boy. *Pediatr Dermatol* 2005;22:450-2.
 - Hernandez-Perez E, Cestoni-Parducci R. Nodular hidradenoma and hidradenocarcinoma: A 10 year review. *J Am Acad Dermatol* 1985;12:15-20.
 - Klein W, Chan E, Seykora JT. Tumors of the epidermal appendages. *In: Elder DE, Elenitsas R, Johnson Jr BL, Murphy GF, editors, Lever's Histopathology of the skin. 9th ed. Lippincott Williams and Wilkins: Philadelphia; 2005. p. 867-926.*
 - Weedon D. Tumors of cutaneous appendages. *In: Skin pathology. 2nd ed. Churchill Livingstone: Edinburgh; 2002. p. 859-916.*
 - Kumar N, Verma K. Clear cell hidradenoma simulating Breast carcinoma: A diagnostic pitfall in fine-needle aspiration of breast. *Diagn Cytopathol* 1996;15:70-2
 - Volmar KE, Cummings TJ, Wang WH, Creager AJ, Tyler DS, Xie HB. Clear cell hidradenoma: A mimic of metastatic clear cell tumors. *Arch Pathol Lab Med* 2005;129:e113-6.
 - Bonvalet D, Bassandon Y, Foix C, Civatte S. Benign adnexal tumors if late occurrence in verrucoid-sebaceous nevus (Jadassohn): Apropos of 7 cases. *Ann Dermatol Venereol* 1983;110:337-42.
 - Domoto H, Terahata S, Sato K, Tamai S. Nodular hidradenoma of the breast: Report of two cases with literature review. *Pathol Int* 1998;48:907-11.
 - House NS, Helm KF, Maloney ME. Management of a hidradenoma with Mohs microscopic surgery. *J Dermatol Surg Oncol* 1994;20:619-22.

