

# Abdominal Actinomycosis in Male Patient- A Case Report

SUREKHA U ARAKERI, PRACHI SINKAR

## ABSTRACT

Actinomycosis is a chronic, suppurative granulomatous inflammation commonly caused by *Actinomyces Israelii*. Invasive infection of abdomen by this organism comprises 20% of all actinomycotic infections. It is commonly seen in women using intrauterine devices and is rarely reported in males. The rarity of disease in general and its non-specific clinical,

biochemical, and radiological features are the causes for frequently mistaking this condition as neoplasm, tuberculosis, appendicitis or inflammatory bowel disease clinically. We report a case of abdominal actinomycosis in a male patient which was clinically masquerading as abdominal tuberculosis and abdominal neoplasm. Diagnosis of actinomycosis was made in this case on histopathology.

**Keywords:** Abdominal mass, Abdominal neoplasm, Abdominal tuberculosis

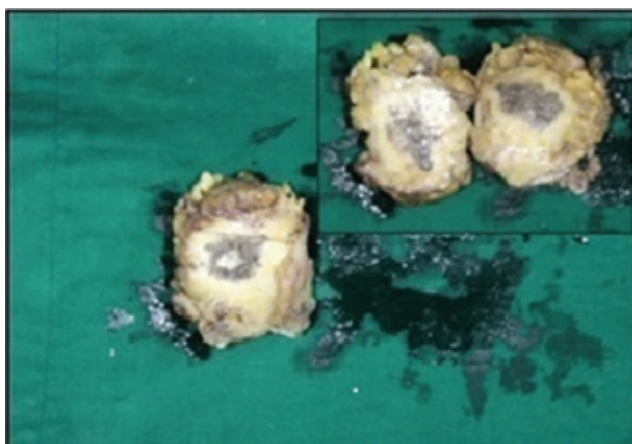
## CASE REPORT

A 50 year old male patient was admitted in the Surgery Department of our hospital with history of right sided abdominal pain of two months duration associated with fever, loss of appetite and loss of weight. He denied any alteration of bowel habit and respiratory complaints. His hematological and biochemical profiles were normal. Stool examination for parasites and occult blood was negative. Physical examination of abdomen revealed a firm, immobile intra-abdominal mass of 8x8 cm in right lumbar area. Ultrasound examination revealed heterogeneous nature of the mass. Based on these findings abdominal neoplasm of mesenchymal origin or abdominal tuberculosis was suspected and laparotomy procedure was planned. During laparotomy procedure, an intra-abdominal firm mass of about 8x8 cm was found, which was infiltrating into the abdominal wall. Liver and rest of the peritoneum was normal. Resection of the mass was done and was submitted

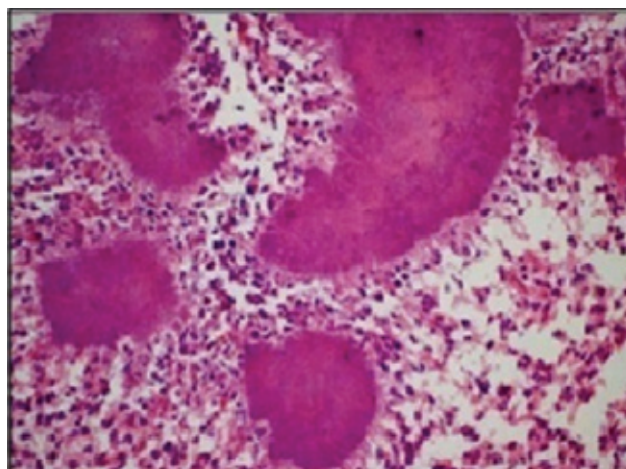
to the Department of Pathology for histopathology study.

On macroscopic examination, mass revealed-globular, yellowish- brown tissue mass measuring 8x8x2cm. One of the surfaces showed an irregular yellowish-white solid area measuring 4x3cm. Cut surface of the mass was solid, yellowish brown in appearance with yellowish-white irregular foci, hemorrhagic areas and areas of necrosis measuring 1.5x1 cm [Table/Fig 1].

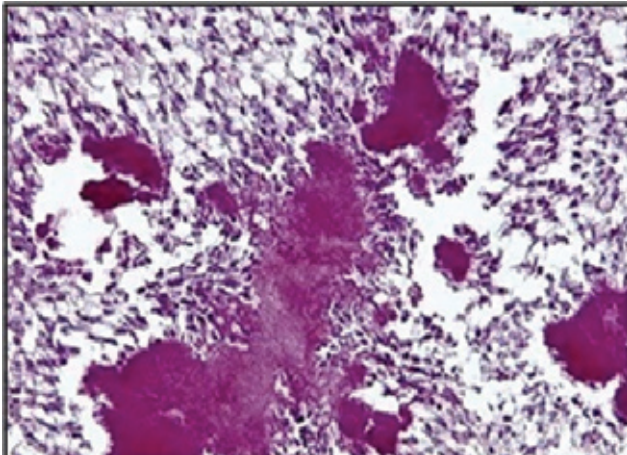
Microscopic examination showed fibrocollagenous and fibroadipose tissue (omental tissue) showing extensive foci of suppurative necrosis surrounded by granulation tissue and intense fibrosis. Granulation tissue showed dense and diffuse mixed inflammatory cells. At places in the necrotic foci colonies of hematoxophilic filamentous structures were noted with surrounding eosinophilic material in some colonies suggesting features of Splendor Hoppeli reaction [Table/Fig



**[Table/Fig-1]:** Gross photograph of globular yellowish-brown abdominal mass [Inset: Cut surface of mass]



**[Table/Fig-2]:** Photomicrograph of actinomycotic colonies surrounded by suppurative inflammation [H & E 100X]



**[Table/Fig-3]:** Photomicrograph of actinomycotic colonies surrounded by suppurative inflammation [PAS Stain 100X]

2]. Gram stain showed gram-positive colonies of intertwined branching filaments. PAS stain showed PAS positive filamentous structures [Table/Fig 3]. Based on these findings diagnosis of chronic granulomatous infection compatible with abdominal actinomycosis was rendered. Patient was treated with oral Ampicillin 500mg-6 hourly. Patient was asymptomatic during post-surgery follow up after three months.

## DISCUSSION

Actinomycosis is a chronic, suppurative granulomatous disease caused by anaerobic gram-positive actinomycotic species with most common species being *Actinomycosis israelii* [1, 2]. Actinomycotic species are normal commensals of oral cavity, gastrointestinal tract and urogenital tract; hence the three main clinical forms of this disease are cervicofacial, thoracic and abdomino-pelvic actinomycosis [2]. Human beings are the natural reservoir and there is no documented person-to-person transmission of this disease. Since, these microorganisms are not virulent, mucosal disruption is required for the progression of infection; hence, it is characterized by tendency to invade into surrounding tissues and can be clinically misdiagnosed as malignancy [1,2]. Abdominal actinomycosis accounts for 20% of all cases of actinomycotic infections. Clinically, it may mimic appendicitis, tuberculosis, inflammatory bowel disease and malignant tumor and may become difficult to diagnose on clinical examination [3]. Abdominal actinomycosis is an uncommon condition caused by actinomycotic organism habituating in human oral flora or gastrointestinal tract and usually present clinically as abdominal mass. It is commonly seen in women using intrauterine devices and is rarely reported in males [4]. Moniruddin ABM et al., [5] in their study stated that according to various authors in actinomycosis of abdomen and pelvis patient usually present with history of recent or remote bowel surgery for perforated acute appendicitis, perforated colonic diverticulitis or trauma to the abdomen. They also mentioned that ileocecal region is commonly involved and the disease presents classically as a slowly growing lesion. However, in the present case duration of

the disease was two months hence clinically it was considered as abdominal tuberculosis or malignancy. Moniruddin ABM et al., [5] in their update also mentioned that diagnosis is usually established on histopathology study, following exploratory laparotomy for a suspected malignancy. Similar findings were noted in the present case. In present case patient clinically presented as abdominal mass for which laparotomy was done and resection of mass was performed which showed actinomycotic colonies on histopathology. However, in the present case there was no history of previous surgery or abdominal trauma. Exact etiology in the present case was not known. Alam MK et al., [6] in their case report on abdominal actinomycosis discussed that according to various authors intraperitoneal spillage of gallstones during laparoscopic cholecystectomy can also produce thoraco-abdominal actinomycosis. Liver involvement can also occur via the portal vein or by direct extension via hepatic artery or by duodenobiliary reflux. They have also stated in their study that, various authors have mentioned that these organisms have tendency to invade into adjacent tissue leading to granulomatous inflammation and mass formation. In the present study we also noted granulomatous inflammation around the actinomycotic colonies on histo-pathology examination. Wagenlehner et al., [7] in their study on abdominal actinomycosis mentioned that management in actinomycosis usually consists of surgery followed by medical treatment with high dose of penicillin. Optimal therapy includes wide excision of necrotic, infected tissue and debris followed by an intense protracted antibiotic therapy. Intravenous 10-20 million units of aqueous penicillin daily followed by 2-15 million units per day orally for a minimum of 2 months and long follow-up is recommended [7]. Sung HY et al., [2] also mentioned that removal of necrotic tissue and surgical drainage combining with medical line of treatment gave good results and also mentioned that antibiotic therapy is essential to minimize the risk of recurrence after surgical excision.

## CONCLUSION

Actinomycosis is a disease that poses great diagnostic challenge clinically due to its insidious course and non-specific symptoms. Because of wide variety of clinical presentations and its tendency to invade into adjacent tissue leading to granulomatous inflammation and mass formation it acts as a great mimicker of tuberculosis and malignancy and should be included in the differential diagnosis when an unusual mass or abscess presents in abdomen with nonspecific symptoms and signs including fever and leukocytosis. This case is presented to raise the awareness of this condition to include actinomycosis infection in the differential diagnosis of an abdominal mass.

## REFERENCES

- [1] Acevedo F, Baudrand R, Letelier LM, Gaete P. Actinomycosis: a great pretender. case reports of unusual presentations and a review of the literature. *International Journal of Infectious Diseases*. 2008; 12(4): 358-62.

- [2] Sung HY, Lee S, Kim S, Jung SE, Kim SW, Kim SY, *et al.* Clinical features of abdominal actinomycosis: a 15-year experience of a single institute. *J Korean Med Sci.* 2011; 26(7): 932-37.
- [3] Karagulle E, Turan H, Turk E, Kiyici E, Yildirim E, Moray G. Abdominal actinomycosis mimicking acute appendicitis. *Can J Surg.* 2008; 51(5):109-10.
- [4] Ozcan R, Mammadov E, Aydin A, Adaletli I, Esen T, Dervisoglu S, *et al.* Actinomycosis presenting as an abdominal mass in a child. *APSP J Case Rep.* 2011; 2(1):4.
- [5] Moniruddin ABM, Begum H, Nahar K. Actinomycosis: an update. *Medicine Today.* 2010; 22(1):43-47.
- [6] Alam MK, Khayat FA, Al-Kayali A, Al-Suhaibani YA. Abdominal actinomycosis: case reports. *Saudi J Gastroenterol.* 2001; 7(1): 37-39.
- [7] Wagenlehner FM, Mohren B, Naber KG, Mannl HF. Abdominal actinomycosis. *Clin Microbiol Infect.* 2003; 9(8):881- 85.

**AUTHOR(S):**

1. Dr. Surekha U Arakeri
2. Dr. Prachi Sinkar

**PARTICULARS OF CONTRIBUTORS:**

1. Professor, Department of Pathology, BLDE University Shri B M Patil Medical College, Hospital and Research Centre, Bijapur, Karnataka, India.
2. Postgraduate Student in Department of Pathology, BLDE University Shri B M Patil Medical College and Hospital and Research Centre, Bijapur, Karnataka, India.

**NAME, ADDRESS, E-MAIL ID OF THE CORRESPONDING AUTHOR:**

Dr Surekha U. Arakeri,  
Professor, Department of Pathology, BLDE University,  
Shri B M Patil Medical College & Research Centre,  
Bijapur, Karnataka, India.  
E-mail: drsuarakeri@hotmail.com

**FINANCIAL OR OTHER COMPETING INTERESTS:**

None.

Date of Publishing: Oct 01, 2015