

**SURGICAL MANAGEMENT OF DIAPHYSEAL FRACTURES OF BOTH BONES  
OF FOREARM IN ADULTS WITH DYNAMIC COMPRESSION PLATES**

**- A CLINICAL STUDY**

Submitted By

**DR.PRASHANT SHAH** M.B.B.S

Dissertation submitted to

**BLDE UNIVERSITY, BIJAPUR, KARNATAKA.**



In partial fulfillment of the Requirements for the degree of

**MS**

in

**ORTHOPAEDICS**

Under the guidance of

**DR. ASHOK R NAYAK** MS (ORTHO)

**PROFESSOR OF ORTHOPAEDICS**

**SHRI B. M. PATIL MEDICAL COLLEGE, HOSPITAL & RESEARCH CENTRE,  
BIJAPUR**

**2011**

## **DECLARATION BY THE CANDIDATE**

I hereby declare that this dissertation entitled “**SURGICAL MANAGEMENT OF DIAPHYSEAL FRACTURES OF BOTH BONES OF FOREARM IN ADULTS WITH DYNAMIC COMPRESSION PLATES-A CLINICAL STUDY**” is a bonafide and genuine research Work carried out by me under the guidance of **DR. ASHOK R NAYAK** M.S (ORTHO) Professor of Orthopaedics.

Date:

Place: Bijapur.

**DR. PRASHANT SHAH**

## **CERTIFICATE BY THE GUIDE**

This is to certify that the dissertation entitled **“SURGICAL MANAGEMENT OF DIAPHYSEAL FRACTURES OF BOTH BONES OF FOREARM IN ADULTS WITH DYNAMIC COMPRESSION PLATES-A CLINICAL STUDY”** is a bonafide research work done by **DR. PRASHANT SHAH** in partial fulfillment of the requirement for the degree of MS In orthopaedics.

**NAYAK** MS (ORTHO)

Date:

Place: Bijapur.

**DR. ASHOK R**

**PROFESSOR OF ORTHOPAEDICS**

BLDEU's Shri. B. M. Patil

Medical College, Hospital

and Research Centre, Bijapur

## **ENDORSEMENT BY THE HOD**

This is to certify that the dissertation entitled “**SURGICAL MANAGEMENT OF DIAPHYSEAL FRACTURES OF BOTH BONES OF FOREARM IN ADULTS WITH DYNAMIC COMPRESSION PLATES-A CLINICAL STUDY**” is a bonafide research work done by **DR.PRASHANT SHAH** under the guidance of **DR.ASHOK R NAYAK** MS (ORTHO) Professor Of Orthopaedics.

**DR. O B PATTANASHETTY** MS (ORTHO)

**Professor and Head  
Department of Orthopaedics**

Date:

BLDEAU's Shri. B. M. Patil

Medical College, Hospital

Place: Bijapur.

and Research Centre, Bijapur

## **ENDORSEMENT BY THE PRINCIPAL**

This is to certify that the dissertation entitled **“SURGICAL MANAGEMENT OF DIAPHYSEAL FRACTURES OF BOTH BONES OF FOREARM IN ADULTS WITH DYNAMIC COMPRESSION PLATES-A CLINICAL STUDY”** is a bonafide research work done by **DR.PRASHANT SHAH** under the guidance of **DR. ASHOK R NAYAK** MS (ORTHO) Professor of Orthopaedics.

**DR. R. C. Bidri** MD

**Principal**

Date :

BLDEU's Shri. B. M. Patil

Place : Bijapur

Medical College, Hospital

and Research Centre, Bijapur

## **COPYRIGHT**

### **DECLARATION BY THE CANDIDATE**

I hereby declare that the BLDE University, Bijapur, Karnataka, shall have the rights to preserve, use and disseminate this dissertation / thesis in print or electronic format for academic / research purpose.

Date:

**DR.PRASHANT SHAH**

Place: Bijapur

**©BLDE UNIVERSITY, Bijapur, Karnataka.**

## **ACKNOWLEDGEMENT**

*On completion of this contribution of scientific document it gives me deep pleasure to acknowledge the guidance provided by my distinguished mentors.*

*With privilege and respect I like to express my gratitude and indebtedness to my Guide. Dr.ASHOK R NAYAK<sub>MS(ORTHO)</sub>, Professor of Orthopaedics, Shri.B.M.Patil Medical College, Bijapur, for his constant inspiration, extensive encouragement and support, which he rendered in pursuit of my post-graduate studies and in preparing this dissertation.*

*I am forever grateful to Dr.O B Pattanashetty prof. and HOD, Dr.Kiran S Patil Assoc Prof, Dr. S S Nandi Assoc Prof, Dr M A Q Ansari Asst Prof, Dr Dayanand Asst Prof, Dr S A Hasan Asst Prof, , Dr Shaheed Asst Prof, Dr Sandeep K Asst Prof, Dr Sudhir H, Dr Basavaraj C, for their valuable help and guidance during my study.*

*I am extremely thankful to Dr.R.C.Bidri, Principal, and Dr.M.H.patil Medical Superintendent, of B.L.D.E.U'S Shri B. M. Patil Medical College Hospital and Research Centre, Bijapur, for permitting me to utilize resources in completion of my work.*

*I would like to express my gratitude to the statistician, Mrs. Vijaya Sorganvi who helped me in my dissertation work.*

*My thanks to one and all staff of Library Staff, Orthopaedic Dept and Hospital for their co-operation in my study.*

*I am thankful to my seniors Dr Neel, Dr Ibrahim, Dr Ranganath, Dr Kiran Reddy, Dr Varun, Dr.Devagouda, Dr Purushottam, Dr Prabhugouda, and my batchmates Dr R P Singh, Dr Abhishek, Dr Naveen, Dr Dinesh and Dr Puneet, Dr. Shravanan PSM pg, Dr. Sachin med pg, for their suggestions and advice.*



*I am thankful to my juniors Dr. Ajay, Dr. Kiran Kumar, Dr. Sourabh, Dr. Ratnakar, Dr. Naveen, Dr. Lokesh, Dr. Natesh, Dr. Shushrut, Dr. Mahesh, Dr. Harshavardhan, Dr. Deepak, Dr. Sangamesh for their co-operation.*

*I am deeply indebted to my Father Dr P G Shah, mother Mrs. Neeta and my brother Dr Rohan whose constant encouragement, patience and support helped me to complete this dissertation.*

*Last but not the least; I convey my heartfelt gratitude to all my patients, without whose co-operation, this study would be incomplete.*

*My special thanks to Mr. Kalyan Kumar and Asif of 'PREETI NET ZONE' Bijapur for computerizing my dissertation work in a right format.*

Date:

Place: Bijapur

**DR.PRASHANT SHAH.**

## **LIST OF ABBREVIATIONS**

AO	Arbeitsgemeinschaft für Osteosynthesefragen
A-P	Anterior posterior
ASIF	Association for the Study of Internal Fixation
D C P	Dynamic compression plate
JBJS	The journal of bone and joint surgery
No. of patients	Number of patients
ORIF	Open reduction and internal fixation
R T A	Road traffic accident
#	Fracture

## ABSTRACT

**Background and objective:** In the current era of industrialization, and with mechanized farming in India, fractures of forearm bones have become more common. The forearm serves an important role in the functioning of the upper extremity. Hence aggressive management through good anatomical reduction and internal fixation of these fractures has become a necessity.<sup>5</sup>

The aim of treatment is to re-establish the normal anatomy and good functional outcome. Rehabilitation if started in the immediate postoperative period prevents disability to a large extent. The aim of this study is to assess the results of fractures of shaft of both bones of forearm with dynamic compression plate (DCP).

**Material and methods:** 40 patients with acute diaphyseal fractures of the radius and ulna were treated with open reduction and internal fixation with dynamic compression plate and screws at Shri B M Patil Medical College Hospital and Research Centre, between October 2008 to April 2010. Cases were taken according to inclusion and exclusion criteria i.e., Adults, both males and females with diaphyseal fracture of forearm bones above the age of 20yrs. Medically unsuitable and patients not willing for surgery were excluded from the study.

**Results:** In our series of 40 cases there were 32 males and 8 females, with average age of 40.7yrs. Good or full range of mobility of elbow and wrist joints with excellent results was present in 28(70%) patients, 11(27.5%) patients with satisfactory results and 1(2.5%) patient with unsatisfactory result.

**Conclusion:** With rigid/anatomical internal fixation, dynamic compression plate is a good fixation for displaced diaphyseal fractures of the forearm bones. Adherence to AO principles, strict asepsis, proper post operative rehabilitation and patient education are more important to obtain excellent results.

**Key Words:** Anatomical fixation, Forearm, Fracture, Dynamic compression plate, Non Union.

## TABLE OF CONTENTS

<b>Sl. No.</b>	<b>Particulars</b>	<b>Page. No.</b>
I	Introduction	1
II	Objectives	3
III	Review of Literature	4
IV	Methodology	72
V	Results	83
VI	Discussion	95
VII	Conclusion	102
VIII	Summary	104
IX	Bibliography	105
X	Annexure	
	A-I: Proforma	110
	A-II: Consent form	115
	A-III: Master Chart	120

## LIST OF TABLES/GRAPHS

Sl.No.	Tables	Page.No
1	Age Distribution with graph	83
2	Sex Distribution with graph	84
3	Side Affected with graph	85
4	Mode of Injury with graph	86
5	Level of Fracture with graph	87
6	Type of the Fracture with graph	88,89
7	Associated Injuries	89
8	Duration of Fracture union with graph	90
9	Results with graph	91
10	Complications with graph	92
11	Age distribution comparison	95
12	Sex distribution comparison	96
13	Extremity affected comparison	97
14	Mode of injury comparison	98
15	Type of fracture comparison	99

## LIST OF FIGURES

Sl.No.	Figures	Page.No
1	Mechanism of dynamization of DCP	22
2	Schematic representation of Radial bowing	31
3	X-ray measurement of Radial bow	31
4	Forearm bones, Radius and Ulna	37
5	Flexor muscles of the forearm	47
6	Extensor muscles of the forearm	48
7	Displacement of radius and ulna with various levels of fracture	58
8	Classification of diaphyseal fractures of both bones of forearm	59
9	Anterior Volar Henry's approach	68
10	Posterior Thomson approach to the radius	69
11	X-ray images of radial tuberosity at different levels of fracture	74
12	Instrument and procedure of the surgery	79,80
13	Case Number 3 With Excellent Results	93
14	Case Number 15 With Excellent Results	94



## INTRODUCTION

The forearm, being a component of upper limb serves important movements in activities of daily living. The forearm, in combination with the proximal and distal radioulnar joints, allows pronation and supination which in turn helps hand, to perform multi axial movements.

With mechanized farming in India and industrialization, fractures of forearm bones have become more common. Fracture of the forearm bones may result in severe loss of function unless adequately treated. Hence good anatomical reduction and internal fixation of these fractures is necessary to restore function<sup>1</sup>.

Closed reduction which was employed in earlier days yielded unsatisfactory results from either non union or loss of motion. Also there are complex forces acting on the forearm bone that makes reduction and maintenance of displaced fracture fragments difficult<sup>2</sup>.

Union may be achieved with any of the methods available however severe loss of function may be the end result unless adequately treated with proper technique and implants.

With the development of compression plate osteosynthesis which provides a good treatment option and predictable outcome, there is an important change in the treatment of forearm fractures<sup>3</sup>. This method helps in perfect reduction of fracture fragments in anatomical position, by rigid fixation and early mobilization, the normal functions of the hand can be reached at the earliest.

Bagby and Denham were the first to describe Dynamic compression plate and more recently developed by the AO School has an intrinsic compression device making extensive

dissection unnecessary. The plate depends upon the obliquity of cylindrical screw holes for compression which is produced as the screws are driven home. The most effective method of producing rigid internal fixation is by the use of compression plates developed by the AO School in Switzerland.

AO (Arbeitsgemeinschaft für Osteosynthesefragen) / Association for the Study of internal fixation (AS IF), dynamic compression plate provides more secure fixation without cast protection. It produces sufficiently rigid fixation, impaction and compression of the fracture site. It can be inserted through a smaller incision than the standard plate because no external compression device is required.

The functional outcome was certified using "*Anderson et al, scoring system*" the variables taken into consideration were,

- a. Union of the fracture,
- b. Range of elbow and wrist movements<sup>4</sup>,
- c. Extent of functional capacity reached.

To conclude, satisfactory reduction of displaced fractures of the forearm bones is difficult to achieve by closed methods and if achieved, it is hard to maintain. So with open reduction and internal fixation using dynamic compression plate, it is possible to achieve perfect fracture reduction, rigid fixation, better bone healing and early mobilization. Cancellous bone grafting can be used whenever there is bone loss.

## **AIMS AND OBJECTIVES**

To assess the results and complications of fixation of dynamic compression plate in fractures of forearm bones in adults.

## REVIEW OF LITERATURE

Fractures are known to occur since evolution of mankind. However Prehistoric man must have had his troubles with broken bones. According to Sudhoff, the bones of Neolithic man showed traces of attempts at corrections of deformities. Apparently enough specimens of fractured bones from that age have been found to justify statistical statements<sup>5</sup>.

Recorded descriptions of the methods of fracture treatment dates back to Egyptian times, which has been clearly mentioned in **Edwin Smith Surgical Papyrus**. Egyptians used palm bark and linen bandages for management of fractures. Clay and lime mixed with egg white were used, but the material most commonly used has been, the wood<sup>6</sup>.

Wood is still used for native splintage in many parts of world like, in India by native doctors.

From the Nubian excavations, came several specimens of forearm fractures which are now in the museum of the Royal College of Surgeons in London. It is a model of neat splinting with wood from the stems of palm leaves, the padding being of coarsely woven cloth such as we today would call homespun. The splints are applied without any attempts at control of the fragments. There is good approximation, but no union<sup>5</sup>.

So in those days, surgeons merely used to fix two bone fragments in an approximate alignment which resulted in mechanical failures either loss of function or nonunion.

Then came the era of Plaster of Paris, described by Mathysen, a Dutch surgeon in 1852. It is made from gypsum, a naturally occurring mineral prepared from ordinary cotton bandage role

smearred with POP powder. When this material is dipped into water, the powdery plaster of paris is transformed into a solid crystalline form of gypsum, and heat is given off.

**Anhydrous calcium sulphate**

**Hydrated calcium sulphate**

**Plaster of Paris**

**Gypsum**

In recent years, fibreglass cast materials are trying to replace plaster of Paris. Most of these are a fibreglass fabric impregnated with polyurethane resin.

1. Merits: These materials are strong, lightweight, and resist breakdown in water.
2. Demerits: They are harder to contour than plaster of Paris, and the polyurethane may irritate the skin. Fibreglass is harder to apply, although the newer bias stretch material is an improvement.

**Principles:** Three points of force are produced by the operator, who moulds the cast firmly against the proximal and distal portions of the extremity (two of the points) and locates the third point directly opposite the apex of the cast. Periosteal or other soft tissue attachments usually are required on the convex side of the cast to provide stability.

So there is always a chance for cast slippage if not properly applied. This may result in malunion or non-union if there is motion at the fracture site.

A study of supination and pronation with regard to forearm fractures by **Patrick** pointed out that when fractures of both bones of the forearm were perfectly aligned in anteroposterior and lateral radiological views, the degree of rotation must ipso-facto be correct. Patrick also considered that the restriction of motion in these fractures was due to callus or fibrous tissue in

the interosseous space, especially from ulna side resulting in shortening and fixation of the interosseous membrane<sup>7</sup>.

The first attempt at internal fixation took place around 1770 in Toulouse, France, Where two surgeons Lapejode and Sicre, used brass wire for cerclage of long bone fractures<sup>6</sup>.

First recorded surgical device for fracture stabilization was the graffe, described by Malgaigne in 1843. It was two sets of paired, curved spikes used to approximate the distracted fragments of a fractured patella<sup>6</sup>.

The term "Osteosynthesis" was coined by **Albin Lambotte** in 1894, a Belgian surgeon regarded universally as Father of modern internal and external fixation. He devised an external fixator and different plates and screws, together with surgical instruments<sup>6</sup>.

Plate fixation of diaphyseal fractures was first advocated by Beckman in 1912, a year later Nicholaysen described intramedullary nailing<sup>8</sup>.

In 1913, Schone described the principles of intramedullary nailing in forearm fractures. Gilfillen devised metallic plate for fixation of fractures of Radius and Ulna<sup>8</sup>.

Robert Danis a surgeon in Brussels published two books on osteosynthesis in 1932 and 1940. The second of these works recorded fascinating observations on the use of rigid fixation devices, his aim was to stabilize the fracture firmly so that securing recovery of soft tissue injury, joint mobility, and muscle function, i.e. immediate functional rehabilitation. To achieve this end he devised a compression plate and, after anatomically reducing the fracture, he compressed the bone ends together to increase the rigidity of fixation<sup>6</sup>.

In 1944, Murry advocated early open reduction of forearm fractures to avoid difficulty in fracture reduction by soft tissue contracture and also advised length of the plate should be five times the diameter of the bone at fracture site, and preferred six holed plate<sup>9</sup>.

In 1945, Mervyn Evans described the method to determine rotational alignment in forearm fractures by the so called Tuberosity View<sup>10</sup>.

A Swiss Surgeon Maurice E. Muller, was inspired by Robert Danis books, put these ideas into practice to investigate this new healing phenomenon. He along with group of surgeons on historical weekend in 1958 formed the AO group (Arbeitsgemeinschaft fur osteosynthe sefragen), later on to be known in English speaking countries as the Association for the study of internal fixation (ASIF). This group dedicated itself to research into osteosynthesis, the design of appropriate instrumentation for fracture surgery and the documentation<sup>6</sup>.

They found that the more accurately a fracture is aligned, the less demand there will be for callus. Four principles were accepted as "Working hypothesis".

1. Anatomical reduction,
2. Rigid internal fixation,
3. Atraumatic technique on soft tissue as well as on the bone,
4. Early pain free active mobilization during the first ten post operative days.

According to AO "Life is movement and movement is life" should be the guiding principle of fracture care. A satisfactory internal fixation is achieved only when external splinting is superfluous and when full active pain free mobilization of muscles and joints is

possible. This is the AO's main objective and is best achieved by a stable internal fixation which will last for the whole duration of bone healing.

A study showed that certain long oblique fractures could be fixed with two screws. Also satisfactory intramedullary fixation could be achieved by using prebent diamond shaped nails by SMITH<sup>11</sup>.

Brunwell & Charnely in their series of 102 cases (130 fractures), compared patient who were treated early i.e. within 1 week and after 1 week and concluded that by delaying surgery, non union chances are more. They also said that the fixity of plate depends upon the obliquity of cylindrical screw holes for compression which is produced as the screws are driven home. The most effective method of producing rigid internal fixation is by the use of compression plates developed by the AO School in Switzerland<sup>12</sup>.

Sarmiento et al in their study of treatment of forearm fractures in adults using plates believed that plate fixation as the most satisfactory treatment for forearm fractures and can achieve good functional results with avoidable complications<sup>13</sup>.

The dynamic compression plate (DCP) was developed in 1969 by Perren and used successfully in humans by Allgower et al in the same year. Its spherical geometry not only allowed self compression but also enabled the maintenance of a congruent fit between the screw and the plate hole at different angles of inclination. Thus, the plate was more adaptable to different situations of internal fixation and could fulfill all the different plate functions; also they published a wonderful series of cast bracing. They avoided below and above joint immobilization and still documented excellent functional results<sup>14</sup>.



**Anderson et al** at the Campbell Clinic from 1960 to 1970, revived experience of 244 patients (216 with closed and twenty-eight with open fractures) with 330 acute diaphyseal fractures of the radius and ulna which were treated with ASIF compression plates and followed for from 4 months to 9 years. 112 patients had fractures of both bones of the forearm; 50, single fractures of the ulna; and 82, single fractures of the radius. In all, 193 fractures of the radius and 137 fractures of the ulna were treated by compression plating, 63 (25.9 per cent) with severely comminuted fractures also had iliac-bone grafts. The over-all rate of union for the radius was 97.9 per cent and for the ulna, 96.3 percent. He achieved excellent functional results in acute diaphyseal fractures of forearm and advised minimal stripping. ASIF compression plates, therefore, provided a successful method for obtaining union and restoring optimum function after acute diaphyseal fractures of the forearm<sup>4</sup>.

Grace J. G. and Eversmann W. analyzed 64 patients with fracture of radius and / ulna fixed with AO compression plates. The purpose of their study was to determine the effect of early post operative mobilization after rigid fixation<sup>15</sup>.

In a study conducted on the animals to know the effect of compression on bone with the help of measuring device that measured compression as bone healing progressed, they noted that there was loss of compression as the fracture heals and some amount of compression persisted even after bony union. The fall in compression was due to the Haversian remodeling. They concluded that compression and absolute rigidity of fracture ends that results from the force applied is highly favorable for fracture healing<sup>16</sup>.

In a study, which was consisted of 1903 radial shaft fractures, 666 ulnar shaft fractures, for 97% cases narrow DCP was used. They noted that there were 3.2% non union

and rest of them had good functional outcome. They recommended the 3.5mm DCP for fixation of forearm fractures<sup>17</sup>.

In a study analysed with 47 forearm fractures in 661 head injured adults. They found no non-union and one delayed union. In 20% traumatic heterotrophic ossification developed at the elbow. 24% demonstrated calcification in the interosseous membrane with myositis in 18%. High rate of union was accounted to delayed surgery. Their review failed to demonstrate the association of head injury, increasing the rate of union. Authors recommended some type of internal fixation and early motion as the treatment of choice. They corroborated interosseous membrane and collateral ligaments of the elbow ossification, to their inherent capacity to ossify after direct trauma<sup>18</sup>.

Stern PJ, Drury WJ. Outlined the complication of forearm fractures in 87 diaphyseal radius/ulna fractures. Major complications occurred in 28% of cases. Non union occurred in 93% of cases, in fractures treated with only 4 screws<sup>19</sup>.

They concluded that

1. Plating with 4 screws may be inadequate fixation for forearm fractures and at least 5 screws must be used to affix the plate to either radius / ulna,
2. The ulna remains the most difficult bone to achieve primary healing. This may be due to torsional stresses that increase during pronation and supination,
3. Synostosis appears to be more common in patients who sustain concomitant head injury and hence heterotrophic ossification<sup>19</sup>.

SHAH in his study of 134 patients compared semi tubular plate with 3.5 mm DCP

used for the treatment of forearm diaphyseal fractures. They concluded that 3.5 mm DCP fixation gives excellent fixation and limb can be mobilized immediately<sup>20</sup>.

A study reported entrapment of flexor digitorum profundus in the ulnar cortical defect (in fracture both bones of forearm). The authors opined that this complication can be avoided by achieving anatomical reduction of the both bones at the time of manipulation and by careful examination for active and passive range of motion of all digital joints with wrist in extension<sup>21</sup>.

A retrospective study by CHAPMAN et al was done of eighty-seven patients who had 129 diaphyseal fractures of either the radius or the ulna, or both, and who were treated with fixation using an AO dynamic-compression plate. Open fractures were internally fixed primarily, and both comminuted and open fractures routinely had bone-grafting. 98% of the fractures united, and 92% of the patients achieved an excellent or satisfactory functional result, the rate of infection was 2.3 per cent. Refracture occurred after removal of a 4.5- millimeter dynamic-compression plate in 2 patients, but no refractures after removal of a 3.5- millimeter plate. The authors concluded that the 3.5-millimeter-plate system gave excellent results in patients who had a fracture of the forearm, and it minimized the risk of refracture. Immediate plate fixation of an open fracture of the forearm, with a low rate of complications, is possible<sup>22</sup>.

Watson-Jones (1982) said "Internal fixation is nothing more than a bone suture" stressing the importance of immobilization after internal fixation. Finger and shoulder exercises should be encouraged right from the start. He condemned the idea "Internal fixation of the fractures of the forearm with metal can allow unrestricted activities", mobilization can be achieved with plates but full activity requires radiological union<sup>23</sup>.

A study was conducted regarding effect of malunion on functional outcome after plate fixation of fractures of both bones of forearm in adults. The authors concluded that restoration of normal radial bow was necessary to achieve good functional outcome<sup>24</sup>.

In a study, regarding immediate fixation of open fractures of the diaphysis of the forearm, they demonstrated immediate stable plate fixation is a beneficial method of treatment of open fractures of forearm and achieved excellent or good functional results in 85% of the series<sup>25</sup>.

**Larry D. Iversen, Marc F. Seintkowski (1994)** in their Manual of orthopaedic therapeutics has listed following observations and recommendations.

In adults it is difficult to achieve a satisfactory closed reduction of displaced fracture of the forearm bones, and if achieved, it is hard to maintain.

Fractures of both bones or a displaced isolated fracture of the radius or ulna should be treated by open reduction and plate fixation.

At a minimum, there must be screws engaging six cortices above and below the fracture site. The use of 3.5 mm plate systems has nearly eliminated the problem of refracture after plate removal. Eight holed plates are used most often.

Cancellous bone grafting to these fractures, in addition to plate fixation, should be considered, as the union rate using this method of treatment has been nearly 100%.

The arm is immobilized in a long arm plaster cast until there is roentgenographic evidence of union. Reliable patients may be placed in a removable splint and early motion started as soon as wound healing is complete<sup>26</sup>.

**Campbell's Operative Orthopaedics** says "with compression plate fixation, early active motion is possible. This helps prevent muscle atrophy and joint stiffness, which are often responsible for unsatisfactory results"<sup>27</sup>.

In a study performed to check mechanical comparison of DCP, LC-DCP and Point contact fixator (PC-fix) in cadaveric sheep tibiae, they concluded that the DCP has torsion and bending properties comparable with LC-DCP and PC-Fix in fixation of simple transverse diaphyseal fractures<sup>28</sup>.

**Ronald McRae Max Esser (2002)**. In the adults displacement, angulations, rotation and comminution may be quite marked and closed reduction is often difficult or impossible to achieve. The best treatment for displaced fractures of the forearm bones in the fit adult is open reduction and internal fixation, usually by placing both bones through separate incision. 3.5 mm AO dynamic compression plates are commonly used, with the radial plate contoured to fit the curve of the shaft. The screws should preferably engage 6 cortices above and below the fracture. The aim is to achieve a rigidity of fixation which will permit early mobilization<sup>29</sup>.

In a study, they proposed the use of biodegradable polymeric materials, avoiding a second operation for removal of implant. No such material has yet been made available for use with conventional techniques of internal fixation, which combines adequate strength, ductility,

maintenance of compression and degradability without marked tissue reaction. Tissue tolerance and local effects on infection are still unsolved problems<sup>30</sup>.

A study was conducted measuring the magnitude of prestressing with transverse fractures. Data from their work are presented. Prestressing of a compression plate applied to the tension side of a bone produces an enhanced dynamic tension band effect<sup>31</sup>.

Uthoff HK and co-workers (1981) have compared stainless steel and titanium plates in the healing of osteotomies in beagles and found that radiologic bone loss was 19% for stainless steel and only 3% for the titanium plates. While histological measurements showed a total bone loss of 3.7 per cent under titanium alloy and of 11 percent under stainless steel plates<sup>32</sup>.

Study by Mihovil Ivica et al stated stable internal fixation with plate reduces pain and allows for early soft tissue rehabilitation without the use of external splints or casts. Restoration of forearm and hand function is ensured by use of DCP<sup>33</sup>.

Study conducted by C.A. Goldfarb et al over the functional outcome after fracture of both bones of forearm showed that operative stabilization by plate and screws led to reliably acceptable functional outcome<sup>34</sup>.

In the study conducted by Wang JP et al 1991-2003 data from 25 patients showed that early meticulous debridement, good open reduction and internal fixation with a small DCP proved very effective in the management of type I and II open fractures of both the radial and ulnar diaphyses<sup>35</sup>.

In a study regarding refracture following removal of plates, Thirty-two plates originally used for fracture fixation in the ulna and radius in twenty-three patients were removed eight to sixty-two months after application. They concluded that refractures always occurred within a year after plate removal. Therefore, if a plate has to be removed, it would be best to use a

protective splint, a brace or a functional cast for at least a few weeks afterward. The bones also should be protected by restriction of athletic activity, heavy lifting, and torsional stresses for one year<sup>35</sup>.

PETER A. DELUCA, et al .conducted study regarding refracture following removal of a plate that has been used to treat a fracture of the forearm.

They identified following risk factors for refracture,

1. The nature of the original fracture (a disproportionate number of refractures occur in patients in whom the initial fracture was due to high energy trauma or a crush injury, was open, or was associated with other fractures in the extremity);
2. Failure to achieve adequate initial compression or reduction in a comminuted fracture; and
3. Radiographic determination that the site of the original fracture has remained radiolucent<sup>36</sup>.

KEITH TAYTON et al, Semi-rigid plates have been constructed from epoxy resin reinforced with carbon fiber. These have been used in animal trials and also for internal fixation of 20 fractures of the human tibia. The results are generally very satisfactory, and support the view that semi-rigid fixation is not only desirable theoretically, but also works in practice. However, the results are from preliminary trials only, and it is emphasized that further experience is necessary before widespread use of such plates can be advocated<sup>37</sup>.

## **Evolution of plates**

Plating of fractures is traceable into the last century, when Hansmann described a percutaneously removable plate in 1886 where he devised a retrievable plate. Lambotte, Lane, Sherman and Townsend and Gilfillan played prominent roles in the development of the early plates. The designs of the plates used by these surgeons and others improved progressively, providing greater strength and better conformity of the plates to the bone surface. During the decades in which these designs were developed, new alloys became available, providing greater strength and better acceptability of the implants by the body. Pauwels defined tension-band techniques in 1935. It was Danis in 1950's pioneered techniques of compression osteosynthesis and defined primary union biologically. He was the first to report use of inter fragmentary compression by applying plates under tension along longitudinal axis of the bone.

A plate has two mechanical functions:<sup>38</sup>

1. It transmits force from one end of a bone to the other, bypassing & thus protecting the area of fracture,
2. Holds the fracture ends together while maintaining proper alignment.

Regardless of their length, thickness, geometry, configuration/type of holes, all plates are classified into four groups<sup>38</sup>.



1. **Neutralization plate:** It acts as a bridge. It transmits various forces from one end of the bone to the other, bypassing the area of fracture. Its main function is to act as a mechanical link. A plate used in combination with a lag screw is also a neutralization plate counteracting the torsional, bending and shearing forces.

2. **Compression plate:** The plate produces a locking force across a fracture site to which it is applied. The effect occurs according to Newton's third law. The bone under compression will have superior stability, improved milieu for bone healing and early mobilization. The direction of compression force is parallel to the plate.

### **Role of compression**

- a. Compaction of the fracture to force together the inter digitating spicules of bone and increase the stability of the construct.
- b. Reduction of the space between the bone fragments to decrease the gap to be bridged by the new bone.
- c. Protection of the blood supply through enhanced fracture stability
- d. Resists the tendency of the fragments to slide under torsion or shear.

### **Methods of achieving compression are by:**

- Self compression plate with eccentric placement of screw.
- Tension device

3. **Buttress plate:** The mechanical function of this plate is to strengthen (buttress) a weakened area of cortex. The plate prevents the bone from collapsing during the healing process. It has a large surface area which facilitates wider distribution of load. A buttress plate applies a force to the bone which is perpendicular to the flat surface of the plate.

4. **Condylar plate:** This is mainly used in intraarticular distal femoral fractures. It maintains the reduction of the major intra articular fragments, hence restoring the anatomy of the joint surface. It also rigidly fixes the metaphyseal components to the diaphyseal shaft, permitting early movement of the extremity. Special instrumentation is required for application. Its use is diminishing with the advent of condylar screw.

Plate fixation techniques, as mainly practiced, necessitate exposure of the fracture site, evacuation of the haematoma, and violation of the periosteal circulation of the bone in proportion to the degree of soft tissue release performed by the surgeon. Whether the fracture haematoma is a source of cellular elements contributing to fracture healing, but preservation of the haematoma may be of value.

### **DYNAMIC COMPRESSION PLATE**

Bagby and Denhan (1956) first described the dynamic compression plate (DCP).

The studies of Eggers and associates, of the effect of compression on the healing of experimental fractures in animals were the first attempts to demonstrate that a compression force applied to healing bone fragments could influence the rate of healing. However, Eggers' slotted Plate did not represent a clinical application of the results of his experiments<sup>39</sup>.

Perhaps the first surgeon to use a true compression plate in the treatment of acute fractures was Danis, in 1949. Danis had less experience and less encouraging results with fractures of the humerus, tibia, and femur, and he wrote about his '**coapteurs**' in 1956.

Later it was introduced in 1965 by AO School which follows the basic design of Danis but has a much more sophisticated compressing mechanism which is applied temporarily at one end of the plate. Because the screw of this compression device has a hexagonal head and the screws and holes in the plate are of special design, a kit which includes the necessary screws, screwdrivers, and wrenches must be used, as well as a long incision and an extra screw-hole in the bone to secure the compressing mechanism.

DCP is now the workhorse of AO system. When introduced in 1965 it was made of Titanium, but it is now fabricated from 316L stainless steel (Zimmer) and of Vitallium (Howmedica)<sup>39</sup>.

The DCP of AO.ASIF consists of a plate with obliquity of cylindrical screw holes for compression which is produced as the screws are driven home. Due to this mechanism, use of a tension device is not required. This has made the plate more adaptable to different situation of internal fixation and can be used as a static compression plate, a buttress plate, a neutralization plate or as DCP<sup>40</sup>.

As the name indicates DCP has the ability to cause the fragments to approximate to one another, resulting in self compression at the fracture site. It also achieves a congruent fit between screw head and plate hole at different angles of inclination.

By applying DCP on the tension side of the bone, the implant absorbs all the tensile stress while all the compressive stress is taken up by the bone. Plate have notch on the undersurface for the hook of the tension device<sup>40</sup>.

### **Compression Plate using external tension device:**

Fracture is reduced; plate is applied and held in place with a bone clamp. The plate is fixed to the shorter fragment by inserting a screw near the fracture site. Tension device is fixed to the other fragment temporarily with a screw beyond the plate and hook of the tension device is engaged in end hole of the plate. Screw of the tension device is tightened to pull on plate and compress fracture. Once it is fully tightened the fracture is under maximal axial compression and the remaining screws are inserted<sup>38, 40</sup>.

### **Advantages:**

- Provides rigid fixation and also prevents rotational strain
- There is no interference with medullary blood supply and there is no external callus formation, therefore there is no encroachment upon the interosseous space.

### **Disadvantages**

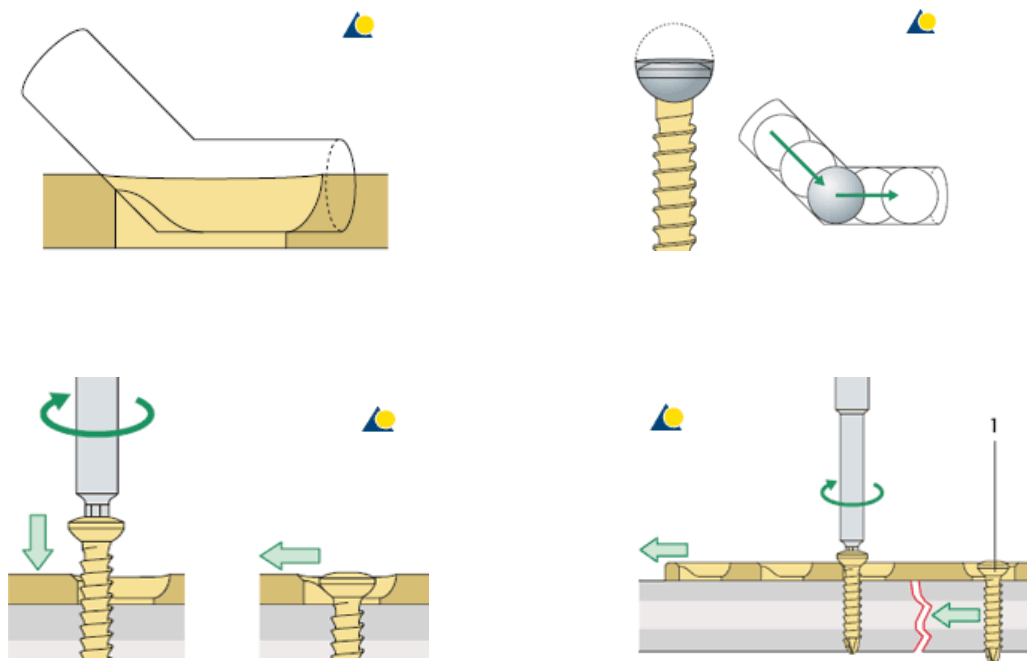
- The use of external tension device will require longer exposure.
- More periosteal stripping, would delay fracture union.

## **Dynamics of DCP**

Screw hole of DCP can be compared with a ball confined to an inclined cylindrical path, where it slides down and horizontally. The screw hole resembles two half cylinders placed at an angle. The spherical gliding principle is implemented at both ends of the plate hole, which enables compression in either direction along its longitudinal axis. So Axial compression results from an interplay between screw hole geometry and eccentric placement of the screw in the screw hole. The under surface of the screw resembles the ball, and sloping wall of the screw hole is analogous to the inclined path. The screw descends as it is inserted by twisting the slope of the screw hole causes the plate to move at right angles to the direction of the descend, the horizontal cylinder (path) facilitates this movement. The aim is to position the screw head at the inter section of the inclined and downward cylinder. At the end point the screw head has a spherical contact in this screw hole which results in maximum stability without completely blocking the horizontal movement of the screw. Sideways movements of the screw head are impossible.

The strength of bone plate assembly will be influenced by the character of the fracture. Transverse fractures are under stronger compression than oblique fractures. Communion, inadequate reduction and missing fragments all contribute to the weakness of the assembly.

The interplay between the spherical screw head and the geometry of screw hole permit the angulations of the screws in all directions. Maximum  $25^{\circ}$  longitudinally and  $7^{\circ}$  sideways. It also facilitates the insertion of an oblique lag screw across the plate.



**Figure -1: Mechanism of dynamization of DCP**

**Advantages of DCP<sup>38, 40</sup>:**

- Usage of two load screw in main fragment for axial compression at fracture.
- Congruent fit between screw head and plate hole
- Inclined insertion of screw with hemispherical screw head is possible up to an angle of 25 deg horizontally, 7 deg sideways.
- Placement of a screw in neutral position without danger of distraction of fragments
- Insertion of a load screw into hole positioned most favorably for a given fracture.
- All screws permit compression.
- Compression of several fragments individually in comminuted fractures.

- Application as a buttress plate in articular areas by inserting the screws in the buttress position.
- Early mobilization is possible.
- Oval inclined surface allows using lag screw in spiral or oblique fractures.

### **Disadvantages<sup>41</sup>:**

#### **Inclination of Screw Hole:**

The geometry of the DCP hole is such that in the long axis, a screw cannot be tilted more than 25°. This has led to difficulties to lag short oblique fractures through the plate.

#### **Flat undersurface:**

The flat undersurface of plate leads to major interference with periosteal blood supply. This leads to plate induced osteoporosis. The potential danger of necrosis, with formation of a sequestrum from underneath the plate.

With the interference in periosteal blood supply immediately below the plate, this area heals more slowly. At the time of plate removal from the tension side of the bone, there is a notch in the bone, which behaves as a stress riser and may induce or facilitate a refracture. So it is always necessary to protect bone till it consolidates after plate removal.

#### **Distribution of Plate Holes:**

When a plate bridges a defect in the bone diaphysis, a fatigue fracture can occur because of stress, due to cyclic weight bearing, flexural and or torsional loads, becomes concentrated at the exposed plate holes.

### Asymmetry of plate holes:

To be best suited for the more common multi fragmentary and complex fracture, a plate must have symmetric plate holes, allowing compression in both directions. The plate hole of the DCP is asymmetric: the self-compressing part of the plate hole is located at the end of the plate hole away from the fracture.

### Fragile lining:

Plates with a rectangular cross section provoke the formation of a comparatively thin bony wall along the length of the plate. If the ridges so formed are thin they are easily nicked at the time of the plate removal. This not only renders the bone less strong, but may also act as a stress riser and contribute to failure.

### Important dimensions<sup>40</sup>

Name	Thickness	Width	Hole spacing	Hole length	Uses
4.5mm Broad DCP	4.5 mm	16 mm	16&25mm	8.5 mm	Humerus and femur
4.5 mm narrow DCP	3.6 mm	12 mm	16&25mm	8.5 mm	forearm, tibia & pelvis
<b>3.5mm DCP</b>	<b>3.0 mm</b>	<b>10 mm</b>	<b>12&amp;16mm</b>	<b>6.5mm</b>	<b>radius and ulna</b>
2.7mm DCP					Mandibular surgeries

The number in the beginning indicates the size of cortical screw used.



### **The Drill guides for DCP<sup>40</sup>**

1. The neutral drill guide
2. The load drill guide

#### **The Neutral drill guide (Green color):**

Used when drilling for a screw in neutral position, at the intersection of the two cylinders. A minimal movement of 0.1 mm in fact occurs when the screws are fully tightened even in neutral position resulting in slight degree of axial compression.

#### **The load drill guide (Gold color):**

This allows eccentric drilling, placing the screw in a load position. The little arrow on the top must point towards the fracture because when the screw is driven home, it is displaced 1.0 mm horizontally. When screw is tightened its head slides downwards along the inclined path plane resulting in axial compression of the bone and tension in the plate. Insertion of one screw in load position results in axial compression of 50-80 kp. This is used only to achieve axial compression once the fracture has been anatomically reduced and fixed with at least one screw in the opposite fragment.

#### **DCP as a Buttress plate:**

Generally buttressing of metaphysis is best carried out with the special T plate, L plate and condylar plates. In many situations however, the buttressing effect of the *DCP* is enough. If used as such it can be used to fix the fracture line and the screw should be angled obliquely into the diaphysis.

## **Contouring of plates**

Special contouring devices permit accurate and controlled shaping of the plates. The new shape is the result of plastic deformation and is permanent. With practice, the plates can be twisted at the time they are bent. This is accomplished by inserting the plate at an angle into the bending pliers or press. Shaping of normal straight plates such as the DCP is extremely difficult. Normal plates can be twisted and bent in the direction of their long axis, but they resist strongly any attempt to bend them in the direction of their short axis or width. The contouring of any plates has been further facilitated by the design of the malleable templates. They come in different sizes to correspond to the different plates, and in different lengths. They have been colour coded for easy identification. Once reduction is carried out, the malleable template is laid on the bone and then gently shaped to correspond exactly to the underlying bone. The template is then removed and taken to the contouring device where the plate is shaped until it corresponds to the template. At the end, the contouring of the plate is checked against the bone and adjusted to make it perfect. In contouring a plate, care should be taken not to bend it back and forth because this weakens the plate.

## ANATOMY OF FOREARM

The forearm is important in the integrated function of the upper extremity. It maintains a stable link between the elbow and the wrist, provides an origin for many of the muscles that insert on the hand, and allows rotation of the wrist to position the hand more effectively in space<sup>42</sup>.

Surgical anatomy of the forearm is very essential to understand the mechanism of injury and deforming forces.

### Embryology<sup>43</sup>

**Development of the limb buds.** Limb development may be conceptualized as the result of a series of ectodermal-mesenchymal interactions.

- The upper limb bud appears on 26th day as small bulges on the lateral body wall at about the level of C5 – C8.
- By 4th week they have grown to form noticeable, coronally oriented ridges.
- Limb morphogenesis takes place from 4<sup>th</sup> to 8<sup>th</sup> week.
- By 33 days the hand plate is visible.
- Digital rays appear on hand during 6<sup>th</sup> week. By 6<sup>th</sup> week end segments of upper limb can be distinguished.
- By the 50th day or so the elbows and shoulder are established, and the fingers are free.
- Each limb consists of a mesenchymal core of mesoderm, covered by ectodermal cap.
- Skeletal elements of limbs develop from a column like mesodermal condensation that appears along the long axis of the limb during 5<sup>th</sup> wk and full differentiation by 12<sup>th</sup> wk.

- Ossification begins in these cartilaginous precursors in 8<sup>th</sup> to 12<sup>th</sup> wk.
- Rotation of limbs occurs during 6<sup>th</sup> to 8th week.

### **Skeletal Anatomy<sup>44</sup>**

Forearm consists of skeletal structures; interosseous membrane; stable proximal and distal radio-ulnar joints; and soft-tissue structures, including the muscles, nerves, and vessels that are in the forearm and that traverse it.

#### **Radius:**

##### **Osteology**

The radius is the lateral bone of the forearm. It has expanded proximal and distal ends; the distal is much broader. The shaft widens rapidly towards its distal end, is convex laterally and concave anteriorly in its distal part.

##### **Proximal end**

The proximal end includes a head, neck and tuberosity. The head is discoid, its proximal surface a shallow cup for the humeral capitulum. And is covered by articular cartilage. Its posterior surface is palpable in a small depression on the lateral side of the back of the extended elbow. The neck is the constriction distal to the head. The tuberosity is distal to the medial part of the neck; posteriorly it is rough, but anteriorly it is usually smooth.

## **Shaft**

The shaft has a lateral convexity, and is triangular in section. The interosseous border is sharp. The interosseous membrane is attached to its distal three-fourths, and connects the radius to the ulna. The anterior border is obvious at both ends, but rounded and indefinite. It descends laterally from the anterolateral part of the tuberosity as the anterior oblique line. The posterior border is well defined only in its middle third: The anterior surface, between anterior and interosseous borders, is concave transversely and shows a distal forward curvature. The posterior surface, between interosseous and posterior borders, is largely flat but may be slightly hollow in the proximal area. The lateral surface is gently convex.

## **Distal end**

The distal end is the widest part. It is four-sided in section. The lateral surface is slightly rough, projecting distally as a styloid process. The smooth carpal articular surface is divided by a ridge into medial and lateral areas. The medial is quadrangular, whereas the lateral is triangular and curves on to the styloid process. The medial surface is the ulnar notch, which is smooth and anteroposteriorly concave for articulation with the head of the ulna. The posterior surface displays a palpable dorsal tubercle (Lister's tubercle), which is limited medially by an oblique groove.

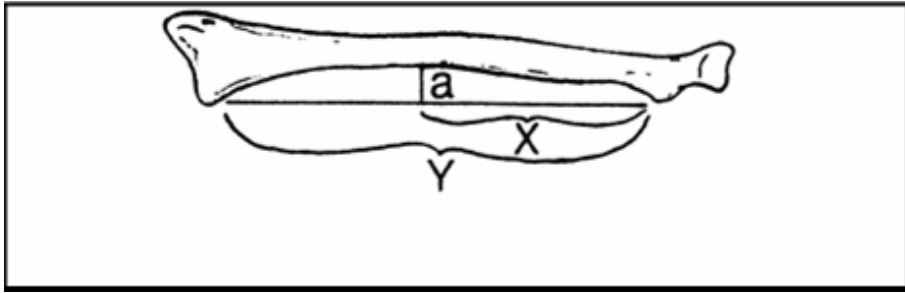
Radius has a characteristic bow which has demonstrated to be important for forearm rotation and must be accurately restored when this bone is fractured. It has double curvature in both anteroposterior and lateral planes.

## **Radius ossification**

The radius ossifies from three centres (one primary centre and two secondary centres). One appears centrally in the shaft in the eighth week of foetal life, and the others appear in each end. Ossification begins in the distal epiphysis towards the end of the first postnatal year, and in the proximal epiphysis during the fourth year in females, and fifth in males. The proximal epiphysis fuses in the fourteenth year in females, seventeenth in males, and the distal in the seventeenth and nineteenth years respectively. A fourth centre sometimes appears in the tuberosity at about the fourteenth or fifteenth year.

## **Technique of Schemitsch and Richards<sup>45</sup>**

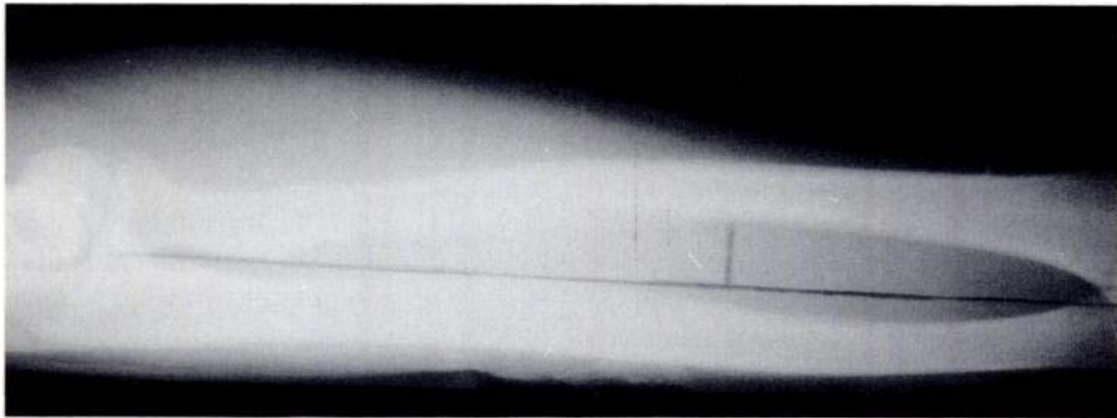
To measure the radial bow, a line is drawn from the bicipital tuberosity to the most ulnar aspect of the radius at the wrist. A perpendicular line is then drawn from the point of the maximum radial bow to this line. The height of the perpendicular line (the maximum radial bow) is measured in millimetres. The distance from the bicipital tuberosity to the previously measured perpendicular line at the point of the maximum radial bow is then measured and is recorded as a percentage of the length of the entire bow (the distance from the mid-point of the bicipital tuberosity to the most ulnar aspect of the subchondral bone of the distal part of the radius). This measurement is termed the location of the maximum radial bow. The value is expressed as a percentage.



**MAXIMUM RADIAL BOW -- a (mm)**

**LOCATION OF MAXIMUM RADIAL BOW --  $x/y \times 100$**

**Figure - 2: Schematic representation of Radial bowing**



**Figure -3: X-ray measurement of Radial bowing**

**Ulna: (Latin, ulna = elbow or arm)**

The ulna is medial to the radius in the supinated forearm. It is the stabilizing bone of the forearm. It obtains a good grip of the humerus and on this foundation the radius and hand move in pronation-supination to secure the appropriate working position for the hand.

It has an upper end, a shaft and lower end (head). Its size diminishes from upper to lower end. Its proximal end is a massive hook which is concave forwards. The bone diminishes

progressively from its proximal mass throughout almost its whole length, but at its distal end expands into a small rounded head and styloid process.

### **Proximal end**

The proximal end has large olecranon and coronoid processes and trochlear and radial notches which articulate with the humerus and radius.

The olecranon is more proximal and is bent forwards at its summit like a beak, which enters the humeral olecranon fossa in extension. Its posterior surface is smooth, triangular and subcutaneous, and its proximal border underlies the 'point' of the elbow.

The coronoid process projects anteriorly distal to the olecranon. Its proximal aspect forms the distal part of the trochlear notch. On the lateral surface, distal to the trochlear notch, there is a shallow, smooth, oval radial notch which articulates with the radial head. Distal to the radial notch the surface is hollow to accommodate the radial tuberosity during pronation and supination.

The trochlear notch articulates with the trochlea of the humerus. It is constricted at the junction of the olecranon and coronoid processes, where their articular surfaces may be separated by a narrow rough non-articular strip. A smooth ridge, adapted to the groove on the humeral trochlea, divides the notch into medial and lateral parts.

The radial notch, an oval or oblong proximal depression on the lateral aspect of the coronoid process, articulates with the periphery of the radial head, and is separated from the trochlear notch by a smooth ridge



## **Shaft**

The shaft is triangular in section in its proximal three-fourths, but distally is almost cylindrical. It has interosseous, posterior and anterior borders.

The interosseous border continues above with the supinator crest, which gives attachment to interosseous membrane.

Posterior border begins at the posterior aspect of olecranon and is subcutaneous throughout its length.

Anterior border is thick and rounded. Begins above and at the medial side of the tuberosity of ulna and runs down to the base of styloid process.

Ulna has three surfaces, anterior, medial and posterior which serve for muscle attachments.

## **Distal end**

The distal end is slightly expanded and has a head and styloid process. The head is visible in pronation on the posteromedial carpal aspect, and can be gripped when the supinated hand is flexed. Its lateral convex articular surface fits the radial ulnar notch.

Ulnar styloid is palpable (most readily in supination) about 1 cm proximal to the plane of the radial styloid.

## **Ulna ossification**

The ulna ossifies from four main centres (one primary center for the shaft and secondary centers, one for distal end and two for olecranon). Ossification begins in the midshaft about the 8th fetal week, and extends rapidly. In the 5th (females) and 6th (males) years, a centre appears in the distal end, and extends into the styloid process. The distal olecranon is ossified as an extension from the shaft, the remainder from two centres, one for the proximal trochlear surface, and the other for a thin scale like proximal epiphysis on its summit. The latter appears in the 9th year in females, 11th in males. The whole proximal epiphysis has joined the shaft by the 14th year in females, 16th in males. The distal epiphysis unites with the shaft in the 17th year in females, 18th in males.

## **The radioulnar articulations<sup>44</sup>**

The radius and ulna are joined to each other at the superior and inferior radioulnar joints. The two bones are also connected by the interosseous membrane; which is sometimes said to constitute a middle radioulnar joint.

### **a. Superior radioulnar joint:**

The proximal radioulnar joint is a uniaxial pivot joint. The articulating surfaces are between the circumference of the radial head and the fibro-osseous ring made by the ulnar radial notch and annular ligament

The essential structure is the annular ligament which holds the head of radius in place. The annular ligament is attached to the anterior and posterior margins of radial notch of ulna and has no attachment to radius. Superiorly it blends with the capsule at the lower margin of the cylindrical articular surface.

**Movement**-pronation and supination of forearm

**b. Inferior radioulnar joint:**

The distal radio-ulnar joint is a uniaxial pivot joint. The articulating surfaces are between the convex distal head of the ulna and the concave ulnar notch of the radius. These surfaces are connected by an articular disc.

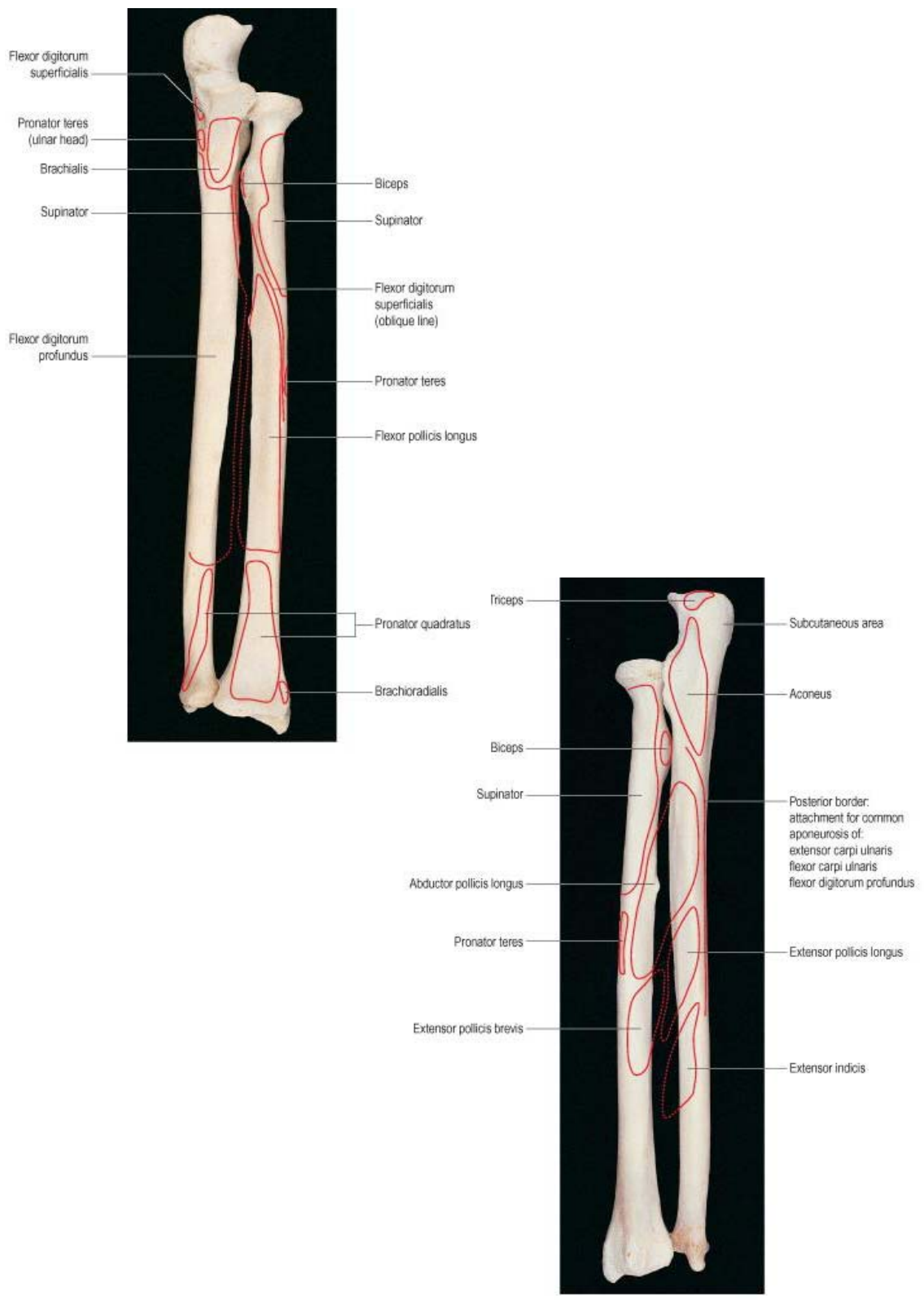
It is closed distally by a triangular fibrocartilage which is attached to its base to the ulnar notch of radius and by its apex to a fossa at the base of ulnar styloid.

**Movement**-pronation and supination of forearm

**c. Interosseous membrane:**

This connects the borders of two bones. The interosseous membrane is a broad, thin, collagenous sheet. Its fibres slant distomedially between the radial and ulnar interosseous borders, and its distal part is attached to the posterior division of the radial border. The membrane is deficient proximally, starting 2 or 3 cm distal to the radial tuberosity, and broader at

midlevel. An oval aperture near its distal margin conducts the anterior interosseous vessels to the back of the forearm, and the posterior interosseous vessels pass through a gap between its proximal border and the oblique cord. The membrane provides attachments for the deep forearm muscles. Its fibres appear to transmit forces which act proximally from the hand to the radius, thence to the ulna and humerus.



**Figure -4: Forearm bones, Radius and Ulna**

## MUSCLES OF THE FOREARM <sup>44</sup>

**Anterior Compartment:** The flexor muscles in the forearm are arranged in two groups, superficial and deep. The five muscles of the superficial group cross the elbow joint; the three muscles of the deep group do not. The flexor compartment is much more bulky than the extensor compartment, for the necessary power of the grip. The extensor muscles merely release the grip.

### Superficial flexor compartment

Muscles of the superficial flexor compartment arise from the medial epicondyle of the humerus by a common tendon. They are pronator teres, flexor carpi radialis, palmaris longus, flexor digitorum superficialis, and flexor carpi ulnaris.

Name of the muscle	Origin	Insertion	Nerve supply	Nerve roots	Action
Pronator teres a) Humeral head	Medial epicondyle of humerus	Lateral aspect of shaft of radius	Median nerve	C6,C7	Pronation and flexion of forearm
b) Ulnar head	Medial border of coronoid process of ulna				

### Clinical testing:

Pronator teres is tested by palpating its contracting fibres during pronation against resistance.

Flexor carpi radialis	Medial epicondyle of Humerus	Bases of second and third metacarpal bones	Median nerve	C6, C7	Flexes and abducts hand at wrist
-----------------------	------------------------------	--	--------------	--------	----------------------------------

**Clinical testing:**

Flexor carpi radialis is tested by palpating its contracting fibres during flexion of the wrist against resistance.

Palmaris Longus	Medial epicondyle of Humerus	Flexor retinaculum and palmar aponeurosis	Median nerve	C7.C8	Flexes hand
-----------------	------------------------------	---	--------------	-------	-------------

**Clinical testing:**

If the wrist is flexed against resistance, the taut tendon of palmaris longus will be seen in the midline of the flexor wrist crease as the tendon passes superficial to the flexor retinaculum. It helps to oppose the thumb to the middle fingertip at the same time as the wrist is flexed.

Flexor digitorum superficialis	Medial epicondyle of humerus; medial border of coronoid process of ulna	Middle phalanx of medial four fingers	Median nerve	C7.C8, T1.	Flexes middle phalanx of fingers and assists in flexing phalanx and hand.
a) Humeroulnar head					
b) Radial head	Oblique line on anterior surface of shaft of radius				

**Clinical testing:**

The independent action of flexor digitorum superficialis for a particular finger is tested by flexing that digit while holding the three other fingers in full extension. This eliminates any

simultaneous contraction of the flexor digitorum profundus which might flex the digit.

Flexor carpi Ulnaris		Base of fifth Metacarpal bone	Ulnar nerve	C8.T1	Flexes and Adducts hands at wrist Joint
a) Humeral head	Medial epicondyle of Humerus				
b) Ulnar head	Medial aspect of olecranon process and posterior border of ulna				

### Clinical testing:

Flexor carpi ulnaris is tested by palpating its fibres while the wrist is flexed against resistance. A more positive test is to palpate the tendon while the patient abducts the little finger against resistance. FCU synergistically contracts to stabilize the pisiform, giving abducted digiti minimi a stable origin.

### Deep flexor compartment

The muscles of the deep flexor compartment are flexor digitorum profundus, flexor pollicis longus and pronator quadratus.

Flexor digitorum profundus	Anteromedial surface of shaft of ulna	Distal phalanges of medial four fingers	Ulnar (medial half) and median (lateral half) nerves	C8.T1	Capable of flexing any or all of the joints over which it passes. Has a role in coordinated finger flexion, but it is the only muscle capable of flexing the distal interphalangeal joints. Index finger tendon is capable of independent function.
----------------------------	---------------------------------------	---	--	-------	---



**Clinical testing:**

Flexor digitorum profundus is tested by flexing the distal interphalangeal joint while holding the proximal interphalangeal joint in extension.

Flexor pollicis longus	anterior surface of shaft of ulna	Distal phalanx of thumb	Anterior interosseous branch of median nerve	C8,T1	Flexes distal phalynx of thumb
------------------------	-----------------------------------	-------------------------	--	-------	--------------------------------

**Clinical testing:**

Flexor pollicis longus is tested by flexing the interphalangeal joint of the thumb against resistance.

Pronator Quadrates	Anterior surface of shaft of ulna	Anterior surface of shaft of radius	Anterior interosseous branch of median	C8.T1	Pronates forearm
--------------------	-----------------------------------	-------------------------------------	--	-------	------------------

**Clinical testing:**

Pronator quadratus is tested by pronation of the forearm against resistance while the wrist finger flexors are relaxed. The simultaneous contraction of pronator teres makes it difficult to test the independent action of pronator quadratus.

**Posterior Compartment**

The posterior compartment contains the extensor muscles of the forearm and brachioradialis and supinator.

**Superficial extensor compartment:**

Name of the muscle	Origin	Insertion	Nerve supply	Nerve root	Action
Brachioradialis	Lateral supracondylar ridge of humerus	Base of styloid process of radius	Radial nerve	C5,C6,C7	Flexes forearm at elbow joint, rotates forearm to the mid prone position

**Clinical testing:**

Brachioradialis can be seen and felt when the semi-pronated forearm is flexed against resistance.

Extensor carpi radialis longus	Lateral supracondylar ridge of humerus	Posterior surface of base of second metacarpal bone	Radial nerve	C6,C7	Extends and abducts hand at wrist joint
--------------------------------	--	---	--------------	-------	---

**Clinical testing:**

The muscle belly and tendon of extensor carpi radialis longus can be palpated when the wrist is extended and abducted against resistance with the forearm pronated.

Extensor carpi radialis brevis	Lateral epicondyle of humerus	Posterior surface of base of third metacarpal bone	Deep branch of radial nerve	C7.C8	Extends and abducts hand at wrist joint
--------------------------------	-------------------------------	--	-----------------------------	-------	---

**Clinical testing:**

The muscle belly and tendon of extensor carpi radialis brevis can be palpated when the wrist is extended and abducted against resistance with the forearm pronated.

Extensor digitorum	Lateral epicondyle of humerus	Middle and distal phalanges of medial four fingers	Posterior interosseous Nerve	C7.C8	Extends fingers and hand
--------------------	-------------------------------	--	------------------------------	-------	--------------------------

**Clinical testing:**

The tendons of extensor digitorum can be readily felt, and usually seen, when the fingers are extended against resistance and the forearm is pronated.

Extensor digiti minimi	Lateral epicondyle of humerus	Extensor expansion of little finger	Posterior interosseous Nerve	C7.C8	Extends metacarpo phalangeal joint of little finger
------------------------	-------------------------------	-------------------------------------	------------------------------	-------	---

**Clinical testing:**

Extensor digiti minimi is tested by extending the little finger while holding the remaining fingers flexed at the metacarpophalangeal joints. This eliminates any simultaneous contraction of extensor digitorum.

Extensor carpi ulnaris	Lateral epicondyle of humerus	Base of fifth metacarpal bone	Deep branch of radial nerve	C7.C8	Extends and adducts hand at wrist joint
------------------------	-------------------------------	-------------------------------	-----------------------------	-------	---

**Clinical testing:**

If the wrist is extended and adducted against resistance, and the forearm is pronated and the fingers are extended, extensor carpi ulnaris can be felt lateral to the groove that overlies the posterior subcutaneous border of the ulna.

Anconeus	Lateral epicondyle of humerus	Lateral surface of olecranon	Radial nerve	C7,C8,T1	Extends elbow joint
----------	-------------------------------	------------------------------	--------------	----------	---------------------

**Deep extensor compartment**

The five deep forearm extensor muscles are abductor pollicis longus, extensor pollicis longus and extensor pollicis brevis (which all act on the thumb), extensor indicis and supinator

Abductor pollicis longus	posterior surface of the shaft of the ulna, the adjoining interosseous membrane, and the middle third of the posterior surface of the radius	Radial side of the first metacarpal base & trapezium.	Deep branch of radial nerve	C7.C8	abducts the wrist joint & thumb.
--------------------------	--	---	-----------------------------	-------	----------------------------------

**Clinical testing:**

Can be seen and felt at the radial aspect of the anatomical snuff box when the thumb and wrist are abducted against resistance at the carpometacarpal joint.

Extensor pollicis longus	Posterior surface of shaft of ulna	Base of distal phalanx of thumb	Deep branch of radial nerve	C7.C8	Extends distal phalanx of thumb
--------------------------	------------------------------------	---------------------------------	-----------------------------	-------	---------------------------------

**Clinical testing:**

The tendon of extensor pollicis longus can be palpated at the ulnar border of the anatomical snuff-box when the thumb is extended at the interphalangeal joint against resistance.

Extensor pollicis brevis	Posterior surface of shaft of radius	Base of proximal phalanx of thumb	Deep branch of radial nerve	C7.C8	Extends metacarpophalangeal joints of thumb
--------------------------	--------------------------------------	-----------------------------------	-----------------------------	-------	---

**Clinical testing:**

The tendon of extensor pollicis brevis can be felt at the radial border of the anatomical snuff-box, lying medial to the tendon of abductor pollicis longus, when the metacarpophalangeal joint of the thumb is extended against resistance.

Extensor indices	Posterior surface of shaft of ulna	Extensor expansion of index finger	Deep branch of radial nerve	C7.C8	Extends Metacarpophalangeal joint of Index finger.
------------------	------------------------------------	------------------------------------	-----------------------------	-------	--

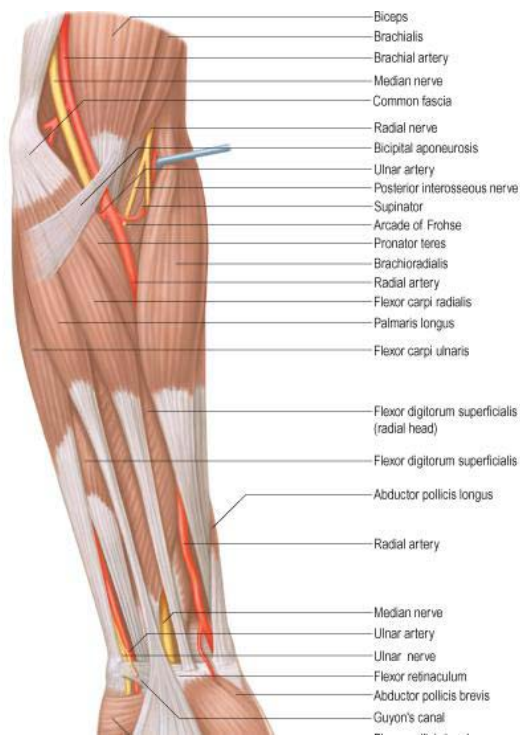
**Clinical testing:**

Extensor indicis is tested by extending the index finger while holding the remaining fingers flexed at the metacarpophalangeal joints. This eliminates the effects of any simultaneous contraction of extensor digitorum.

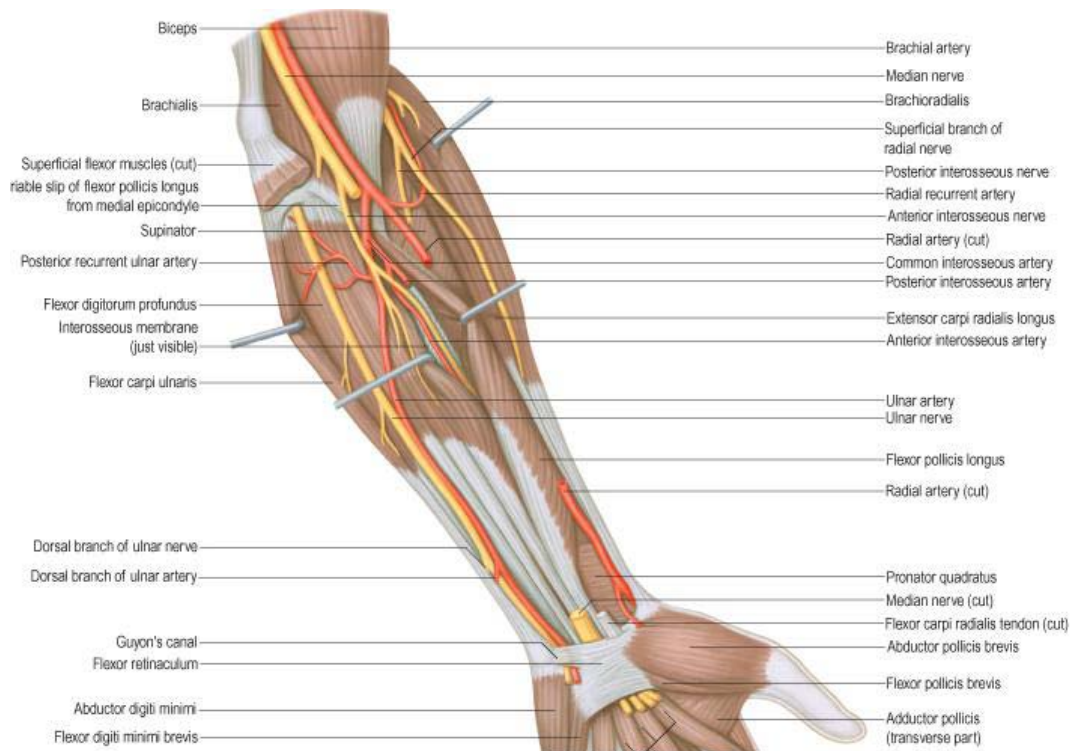
Supinator	Lateral epicondyle of humerus, annular ligament and proximal ulna	Neck and shaft of radius	Deep branch of radial nerve	C5, C6	Supination of forearm
-----------	---	--------------------------	-----------------------------	--------	-----------------------

**Clinical testing:**

Supinator is too deep to be palpated and independent testing is difficult. Biceps is inactive on supination with the elbow fully extended, therefore this must be produced by supination alone and can be used to test its function.

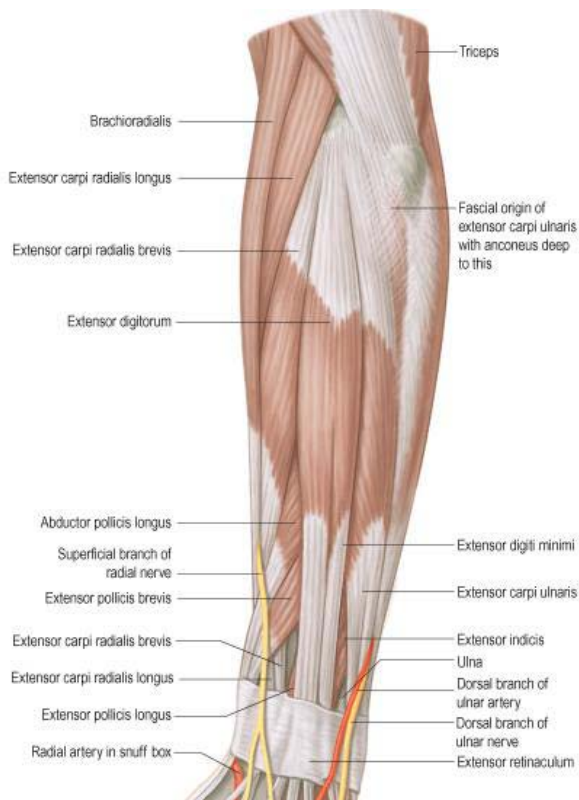


**Superficial Flexor compartment muscles of forearm**



**Deep Flexor compartment muscles of forearm**

**Figure - 5: Flexor muscles of the forearm**



### Superficial extensor compartment muscles of forearm

### Deep extensor compartment muscles of forearm

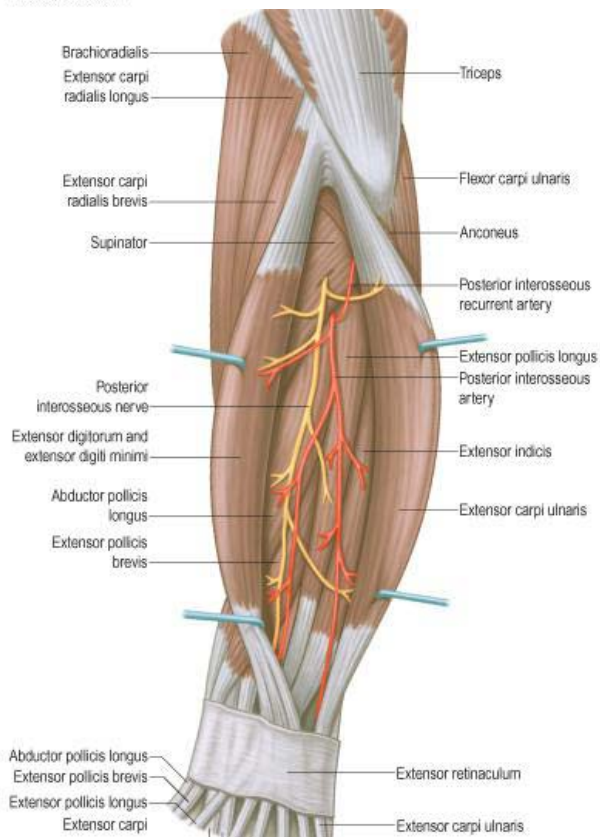


Figure -6: Extensor muscles of the forearm



## VASCULAR SUPPLY OF FOREARM<sup>44</sup>

### **Radial artery**

Originates from brachial artery at about 1 cm distal to the flexion crease of the elbow.

It descends along the lateral side of the forearm, the artery is medial to the radial shaft proximally, and anterior to it distally. Runs inferolaterally under cover of brachioradialis and distally lateral to flexor carpi radialis tendon; Its posterior relations in the forearm are successively the tendon of biceps, supinator, the distal attachment of pronator teres, the radial head of flexor digitorum superficialis, flexor pollicis longus, pronator quadratus and the lower end of the radius (where its pulsation is most accessible).

Winds around lateral aspect of radius and crosses floor of anatomical snuff box to pierce fascia; ends by forming deep palmar arch with deep branch of ulnar artery.

Branches in the forearm

- Radial recurrent artery
- Cutaneous branches & Muscular branches.

### **Ulnar artery**

The ulnar artery is the larger terminal branch of the brachial artery. It starts 1 cm distal to the flexion crease of the elbow and reaches the medial side of the forearm midway between elbow and wrist.

Passes inferomedially and then directly, deep to pronator teres, palmaris longus, and flexor digitorum superficialis to reach medial side of forearm. The ulnar artery crosses the flexor retinaculum lateral to the ulnar nerve and pisiform bone to enter the hand and gives a deep palmar branch to deep arch and continues as superficial palmar arch. The ulnar nerve lies medial to the distal two-thirds of the artery.

### **Branches in the forearm**

- Anterior and posterior ulnar recurrent arteries
- Common interosseous artery
- Anterior interosseous artery
- Muscular and nutrient branches

### **Radial recurrent artery**

Originates on the lateral side of radial artery, just distal to its origin.

Ascends on supinator and then passes between brachioradialis and brachialis. It supplies these muscles and the elbow joint, anastomosing with the radial collateral branch of the profunda brachii.

### **Anterior ulnar recurrent and posterior ulnar recurrent artery.**

Originates from ulnar artery, just distal to elbow joint.

AUR artery ascends between brachialis and pronator teres, supplies them and anastomoses with the inferior ulnar collateral artery anterior to the medial epicondyle.

PUR artery passes dorsomedially between flexores digitorum profundus and superficialis, ascending behind the medial epicondyle; it supplies adjacent muscles, nerve, bone and elbow joint, and anastomoses with the ulnar collateral and interosseous recurrent arteries.

### **Common interosseous artery**

The common interosseous artery is a short branch of the ulnar artery.

After a short course, terminates by dividing into anterior and posterior interosseous A.

### **Anterior interosseous artery**

The anterior interosseous artery descends on the anterior aspect of the interosseous membrane with the anterior interosseous branch of the median nerve.

The anterior interosseous artery proper leaves the anterior compartment by piercing the interosseous membrane proximal to pronator quadratus. It anastomoses with the posterior interosseous artery in the posterior compartment of the forearm.

### **Posterior interosseous artery**

It passes dorsally between the oblique cord and proximal border of the interosseous membrane. It descends deep in the groove between extensor carpi ulnaris and the extensor digiti minimi part of extensor digitorum. While in the groove it gives rise to multiple muscular branches. The posterior interosseous artery accompanies the deep branch of the radial nerve (posterior interosseous nerve) on abductor pollicis longus. Distally it anastomoses with the terminal part of the anterior interosseous artery and the dorsal carpal arch.

## **NERVES OF FLEXOR COMPARTMENT<sup>44</sup>**

The lateral cutaneous nerve of the forearm, the cutaneous continuation of the musculocutaneous nerve, pierces the deep fascia above the elbow lateral to the tendon of biceps and supplies the anterolateral surface of the forearm.

The medial cutaneous nerve of the forearm supplies front and back of the medial part of the forearm.

The posterior cutaneous nerve of the forearm passes along the dorsum of the forearm to the wrist. It supplies the skin along its course.

### **Median Nerve**

Enters the forearm between the heads of pronator teres. It passes behind a tendinous bridge between the humero-ulnar and radial heads of the flexor digitorum superficialis, and descends through the forearm posterior and adherent to flexor digitorum superficialis and anterior to flexor digitorum profundus. About 5 cm proximal to the wrist it becomes superficial. It then passes deep to the flexor retinaculum into the palm.

### **Branches in the forearm**

- Anterior interosseous nerve
- Muscular branches to pronator teres, flexor carpi radialis, palmaris longus and flexor digitorum superficialis.
- Articular branches.

## **Ulnar Nerve**

The ulnar nerve enters the forearm from the extensor compartment of arm by passing between the two heads of flexor carpi ulnaris. The ulnar nerve descends on the medial side of the forearm, lying on flexor digitorum profundus with the ulnar artery to its radial side.

It supplies flexor carpi ulnaris and ulnar half of flexor digitorum profundus also gives palmar cutaneous branch

### **Superficial terminal branch**

The superficial terminal branch of the radial nerve, the cutaneous continuation of the main nerve, runs from the cubital fossa on the surface of supinator, pronator teres tendon and flexor digitorum superficialis, on the lateral side of forearm under cover of brachioradialis. In the middle third of the forearm it lies beside and lateral to radial artery. It then leaves the flexor compartment of the forearm by passing backwards deep to the tendon of brachioradialis and breaks into two or three branches.

### **Nerve of extensor compartment:**

#### **Posterior interosseous nerve:**

The posterior interosseous nerve is the deep terminal branch of the radial nerve. It reaches the back of the forearm by passing round the lateral aspect of the radius between the two heads of supinator. It passes downwards over the abductor pollicis longus origin and dips down to reach the interosseous membrane where it passes between the muscles as far as the wrist joint. Here it ends in a small nodule from which branches supply the wrist joint.

## **Branches in the forearm**

Muscular branches to all muscles which arise from the common extensor origin and deep muscles of the extensor compartment.

## **Biomechanics Of Forearm<sup>42</sup>**

The longitudinal axis of rotation of the forearm passes through the articular surface of the radial head, the interosseous membrane, and the articular surface of the ulna at the distal radio-ulnar joint<sup>46</sup>.

Ulna is relatively straight bone, but the radius is much more complex. The ulna is a fixed strut around which the radius rotates in pronation and supination.

Both the supinator and the biceps muscle supinate the forearm. The biceps is a stronger supinator when the forearm is pronated and the elbow is flexed.

Supination strength is normally greater than pronation strength.

Pronation occurs by the action of the pronator quadratus and pronator teres muscles.

The normal range of rotation of the forearm is 75 degrees of pronation and 85 degrees of supination.

Most normal activities of daily living can be accomplished with an arc of 100 degrees of rotation, with equal amounts of pronation and supination<sup>47</sup>.

## **MECHANISM OF INJURY<sup>48</sup>**

The mechanism of injury that cause fractures of radius and ulna are myriad.

By far the most common is some form of **vehicular accident**, especially automobile and motorcycle accidents. Frequently the patient is unable to recount the exact mechanism of injury owing to the sudden nature of the accident. Probably most of these vehicular accidents result in some type of direct blow to the forearm.

Other causes of **direct blow injuries** include fights in which one of the adversaries is struck on the forearm with a stick.

**Gunshot wounds** can cause fracture of both bones of the forearm. Such injuries are commonly associated with nerve or soft tissue deficits and frequently have significant bone loss.

**Pathologic fractures** of the forearm bones are not common.

Indirect force like **fall on an outstretched hand** is the other cause. Most forearm shaft fractures resulting from falls occur in athletics or in falls from heights.

## **Displacements<sup>49</sup>**

Fractures of the forearm bones may result in severe loss of function unless adequately treated. The relationship of the radiohumeral, proximal radioulnar, ulnohumeral, radiocarpal, and distal radioulnar joints and the interosseous space must be anatomical, or some functional impairment eventually results. Severe loss of function may result if axis of forearm is not maintained even though adequate healing of the fractures occurs.

The radius and ulna are connected to each other by three muscles - the supinator, pronator teres and pronator quadratus, which take origin on one bone and insert on the other. When there is a fracture, these muscles tend to approximate the radius and ulna and decrease the interosseous space.

When there is fracture of radius in upper third, the biceps and the supinator muscles, through their insertions, exert rotational forces on fractures of the proximal third of the radius. Distally, the pronator teres, inserting on the midshaft and the pronator quadratus on the distal fourth of the radius exert rotational and angulatory forces.

In fracture of the radius located distal to the pronator teres, the combined forces of biceps and supinator is somewhat neutralized on the proximal fragment by the pronator teres and the proximal fragment assumes mid prone position<sup>48</sup>.

Fractures of the distal radius, distal to the pronator teres distal fragment tends to angulate toward the ulna by the action of the pronator quadratus and the pull of the long forearm muscles.

Hence in closed treatment of fracture both bones forearm, immobilization in desired position is mandatory. For upper third fractures of radius, the forearm is to be immobilized in supination. For middle third, mid pronation and for distal third, pronation of forearm. These immobilization positions help in satisfactory union and good functional results<sup>48</sup>.

Fractures of the ulna tend to be affected primarily by angulatory forces because the proximal fragment usually displaces toward the radius. The muscle mass in the proximal forearm makes maintenance of closed reduction difficult<sup>49</sup>.

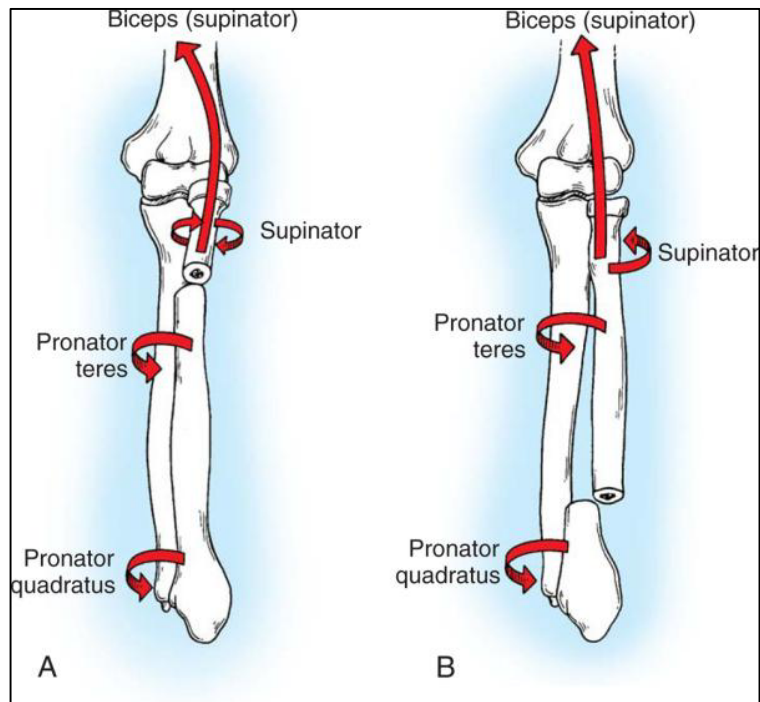


The anatomical restoration of the double bow of the radius must be maintained to achieve normal pronation and supination. Bone healing of both radius and ulna is slow because of small contact surfaces at the fracture site and is the reason why stable fixation of fragments is very important. Intramedullary nailing straightens the radius with loss of curvatures leading to cross union. Hence plating is considered to be the treatment of choice in forearm fractures<sup>50</sup>.

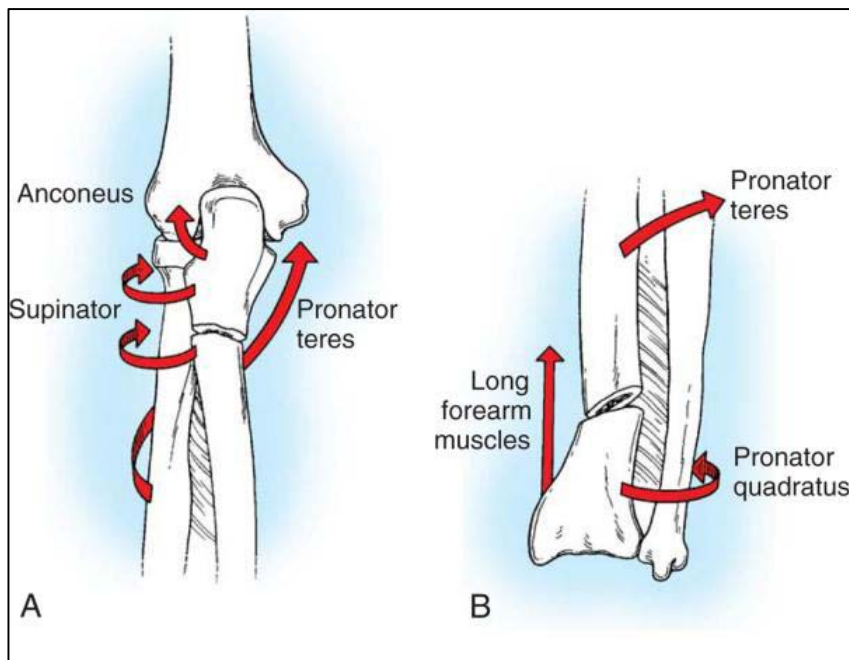
The usual deformities encountered are rotation, angulation and over-riding. Associated comminution may also be seen. Care must be taken to include the elbow and wrist joint radiographs to ascertain any associated dislocation or articular fractures.

During the normal range of pronation, the radius crosses over the ulna and thus compressing the deep flexor muscles between the two bones. So anything encroaching upon this space such as fibrous tissue, callus, oedema or haemorrhage will alter the compressibility of the flexor muscles and limit pronation. It is therefore expected that in all the fractures of mid third radius/ulna some loss of pronation will occur and will last for a considerable time after union has occurred<sup>45</sup>.

Because closed reduction is considered somewhat demanding and unpredictable, most orthopaedic surgeons prefer open reduction and internal fixation for fractures of both bones of forearm.



**A**, Deforming forces of fractures of radius above level of insertion of pronator teres. Proximal fragment lies in supination because of unopposed pull of supinator and biceps. **B**, Below level of insertion of pronator teres, proximal fragment is in neutral position.

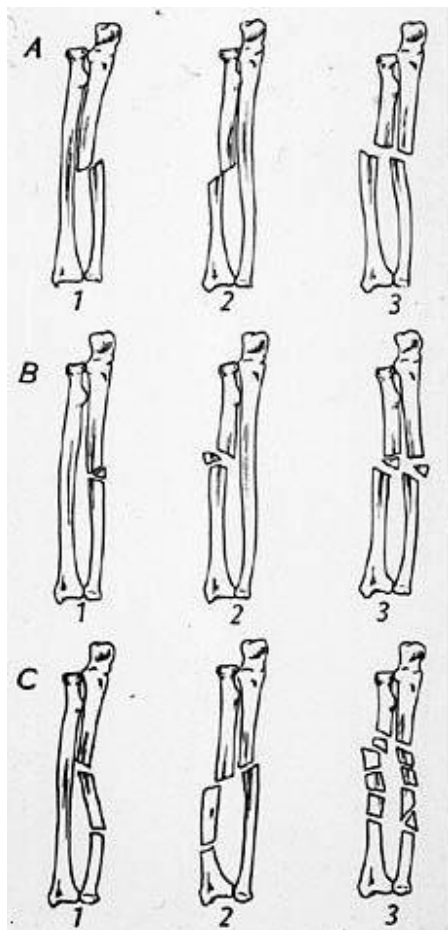


**A**, Isolated fractures of ulna in its proximal third are angulated toward radius and are difficult to reduce. **B**, Fractures of distal radius are angulated toward ulna because of pull of long forearm muscles and pronator quadratus.

**Figure-7: Displacement of radius and ulna with various levels of fracture**

## CLASSIFICATION OF DIAPHYSEAL FRACTURES OF BOTH BONES OF FOREARM

The AO has broadly classified into three types. Type A is the simple fractures. Type B are wedge fractures and Type C are complex fractures<sup>1</sup>. The subtypes of these fractures are shown in the Figure.



### A1 Simple fracture, of the ulna, radius intact

- .1 oblique
- .2 transverse
- .3 with dislocation of the radial head (Monteggia)

### A2 Simple fracture, of the radius, ulna intact

- .1 oblique
- .2 transverse
- .3 with dislocation of the distal radio-ulnar joint (Galeazzi)

### A3 Simple fracture of both bones

- .1 radius, proximal zone
- .2 radius, middle zone
- .3 radius, distal zone

### B1 Wedge fracture, of the ulna, radius intact

- .1 intact wedge
- .2 fragmented wedge
- .3 with dislocation of the radial head (Monteggia)

### B2 Wedge fracture, of the radius, ulna intact

- .1 intact wedge
- .2 fragmented wedge
- .3 with dislocation of the distal radio-ulnar joint (Galeazzi)

### B3 Wedge fracture, of the one bone, simple or wedge fracture of the other

- .1 ulna wedge and simple fracture of the radius
- .2 radial wedge and simple fracture of the ulna
- .3 ulnar and radial wedges

### C1 Complex fracture, of the ulna

- .1 bifocal, radius intact
- .2 bifocal, radius fractured
- .3 irregular

### C2 Complex fracture, of the radius

- .1 bifocal, ulna intact
- .2 bifocal, ulna fractured
- .3 irregular

### C3 Complex fracture, of both bones

- .1 bifocal
- .2 bifocal of the one, irregular of the other
- .3 irregular

**Figure-8:**

## **OTA classification system for the fracture configurations**

Type 1) Linear fractures :

Transverse

Oblique

Spiral

2) Comminuted fractures:

Comminuted - less than 50%

Comminuted - more than 50%

Butterfly -less than 50%

Butterfly - more than 50%

3) Segmental fractures:

Two levels

Three levels or more

Longitudinal split

Segmental comminuted fracture

4) Fracture with bone loss:

Bone loss less than 50%

Bone loss more than 50%

Complete bone loss.

## Treatment

There are many treatment modalities available for treating the fracture of diaphyseal bones of the forearm. They include cast immobilization, intramedullary nailing, external fixation and plate fixation.

Closed treatment of fracture both bones of forearm have resulted in poor results. The role of intramedullary nailing of forearm fractures is very limited in adults. It is fair to say that the vast majority of fractures of both bones of forearm can be most effectively treated by accurate anatomic reduction, rigid plate fixation and early mobilization of the soft tissues<sup>48</sup>.

Indications for open reduction of fractures of the shafts of the radius and ulna<sup>48</sup>,

- All displaced fractures of radius and ulna in adults.
- All isolated displaced fractures of the radius.
- Isolated fractures of the ulna with angulation greater than 10°.
- All Monteggia fractures
- All Galeazzi fractures
- Fractures associated with compartment syndrome, regardless of the degree of displacement.
- Multiple fractures in the same extremity.
- Pathologic fractures.

## **APPROACHES TO THE RADIUS<sup>51</sup>:**

### **ANTERIOR APPROACH: (Volar Henry's approach)**

Offers an excellent, safe exposure of the radius, uncovering the entire length of the bone. The volar (anterior) surface of the distal half of the radius is broad, flat, and smooth and provides a more **satisfactory bed for a plate or a graft**.

#### **Position**

Supine with arm on arm board with the forearm in supination,

#### **Land marks**

Biceps tendon, brachioradialis muscle and styloid process of the radius

#### **Incision:**

Make a 15- to 20-cm longitudinal incision from the anterior flexor crease of the elbow just lateral to the biceps tendon down to the styloid process of the radius over the interval between the brachioradialis and the flexor carpi radialis muscles.

This interval, as Kocher stated, "Lies in the frontier line between the structures innervated by the different nerves."

#### **Internervous plane**

Proximally: Brachioradialis muscle (radial nerve) and pronator teres (median nerve) .

Distally: Brachioradialis muscle (radial nerve) and Flexor carpi radialis muscle (median nerve).

**Dissection:**

Incise deep fascia in line with skin incision.

Identify and protect the sensory branch of the radial nerve, which lies beneath the brachioradialis muscle. The radial artery lies beneath the brachioradialis in the middle part of forearm,

Carefully mobilize and retract medially the flexor carpi radialis tendon and the radial artery and vein to achieve adequate exposure. Preserve the superficial radial nerve, which is a sensory nerve.

**Proximal third**

The proximal third of the radius is covered by the supinator muscle, through which the posterior interosseous nerve passes on its way to the posterior compartment of the forearm. The posterior interosseous nerve is vulnerable by this approach. To displace the nerve laterally and posteriorly fully supinate the forearm and perform subperiosteal dissection.

**Middle third**

The anterior surface of the middle third of bone is covered by pronator teres and flexor digitorum superficialis. Pronate the arm so that the insertion of pronator teres onto the lateral aspect of the radius is exposed. Detach this insertion and strip the muscle off medially.

## **Distal third**

To reach the bone, partially supinate the forearm and incise the periosteum of the lateral aspect of the radius lateral to the pronator quadratus and flexor pollicis longus. Continue the dissection subperiosteal lifting them off the radius.

## **Dangers**

### **Nerves**

- **The posterior interosseous nerve:** The nerve winds round the neck of radius within supinator muscle. To ensure its safety; detach the insertion of supinator subperiosteally.
- **The superficial radial nerve**

### **Vessels**

- The radial artery: Runs down the middle of forearm under brachioradialis muscle.
- The recurrent radial arteries are a leash of vessels that arise from radial artery just below the elbow joint.

## **Approach to the Proximal and Middle Thirds of the Posterior Surface of**

### **Radius- Thompson**

Exposing the proximal third of the radius is difficult because the deep branch of the radial nerve (posterior interosseous) traverses it within the supinator muscle



## **Position**

Supine with patients arm across the chest. Pronate the patient's forearm to expose the extensor compartment.

## **Landmarks**

- Lateral epicondyle of humerus
- Listers tubercle.

## **Incision:**

Skin incision over the proximal and middle thirds of the radius along a line drawn from the center of the dorsum of the wrist to a point 1.5 cm anterior to the lateral humeral epicondyle; when the forearm is pronated, this line is nearly straight.

## **Internervous plane:**

Proximally lies b/w extensor carpi radialis brevis (Radial nerve) & extensor digitorum communis muscle (Posterior interosseous nerve).

Distally lies b/w extensor carpi radialis brevis(Radial nerve) & extensor pollicis longus muscle(Posterior interosseous nerve).

## **Dissection**

In the distal part of the incision develop the interval between the extensor digitorum communis muscle and the extensor carpi radialis brevis, and retract these structures to the ulnar and radial sides.

The abductor pollicis longus muscle is visible; retract it distally and toward the ulna to expose part of the posterior surface of the radius in the middle third.

Continue the dissection proximally between the extensor digitorum communis and the extensors carpi radialis brevis and longus to the lateral humeral epicondyle.

Reflect the extensor digitorum communis toward the ulna to expose the supinator muscle, or for a wider view, detach the extensor digitorum from its origin on the lateral epicondyle and retract it further medially.

Exposure of the radius in the proximal third covered by the supinator by one of two means. Either **divide the muscle fibres down to the deep branch of the radial nerve** and carefully retract the nerve, or **free the muscle from the bone subperiosteally and reflect it proximally** or distally along with the nerve; the latter is the better method if the exposure is wide enough.

### **Dangers**

Posterior interosseous nerve (by identifying nerve & protecting it in the supinator muscle) and posterior interosseous artery.

### **Approach to Ulna<sup>51</sup>**

Because part of the posterior surface of the ulna throughout its length lies just under the skin, any part of the bone can be approached by incising the skin, fascia, and periosteum along this surface.

**Position:** Place the patient in supine position on the operating table with the arm placed across the chest to expose the subcutaneous border of the ulna.

**Landmarks:** Subcutaneous border of ulna.

**Incision:** Linear, longitudinal incision over the subcutaneous border of the ulna

**Internervous plane:**

Extensor carpi ulnaris (posterior interosseous nerve) and Flexor carpi ulnaris (ulnar nerve).

**Surgical dissection:**

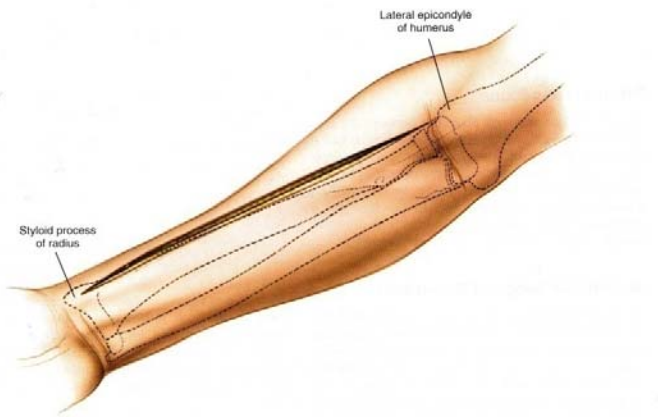
Incise the skin, fascia and periosteum along this surface. In the proximal fifth, part of the insertion of triceps will need to be detached. In its middle third, the fibers of Extensor carpi ulnaris muscle nearly always have to be divided to reach the bone.

**Dangers**

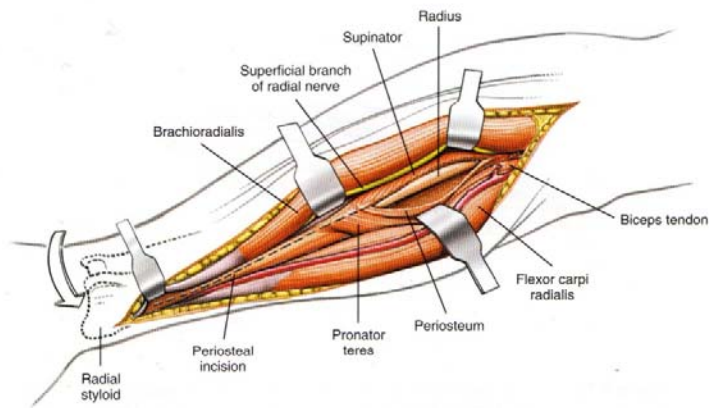
Ulnar nerve, which travels down the forearm under the flexor carpi ulnaris, lies on the flexor digitorum profundus. The nerve is safe as long as the flexor carpi ulnaris is stripped off the ulna subperiosteally. Nerve is most vulnerable in its proximal dissections.

**Vessels**

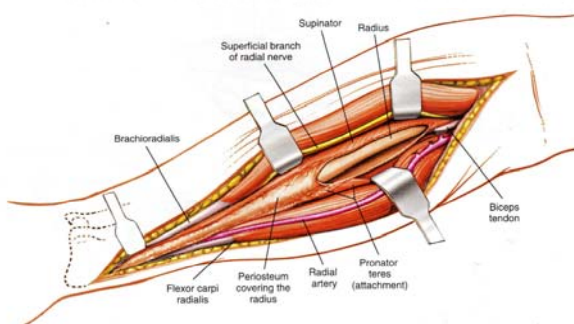
The ulnar artery travels down the forearm with the ulnar nerve, lying on its radial side. Hence vulnerable while dissecting the flexor carpi ulnaris<sup>51</sup>.



Make a straight incision on the anterior part of the forearm, from the flexor crease on the lateral side of the biceps down to the styloid process of the radius.

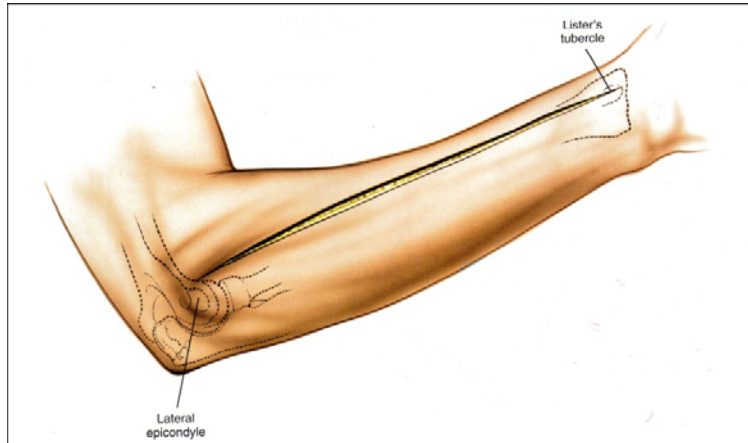


Turn the arm downward to identify the pronator teres muscle. Resect it along its insertion on the lateral aspect of the radius.

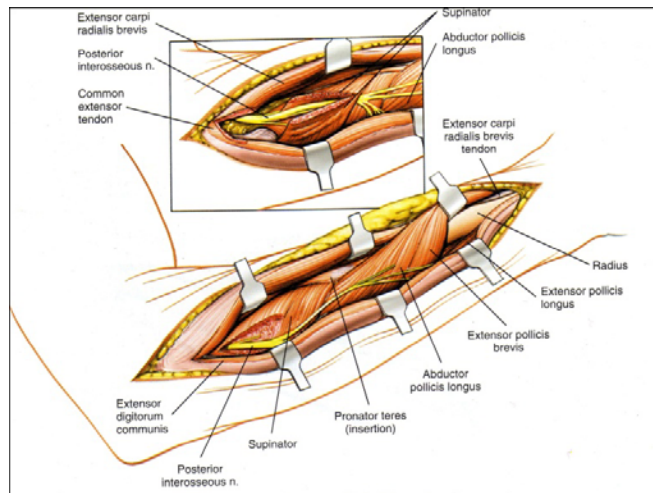


Continue dissection distally to uncover the distal of the radius. Leave the periosteum intact

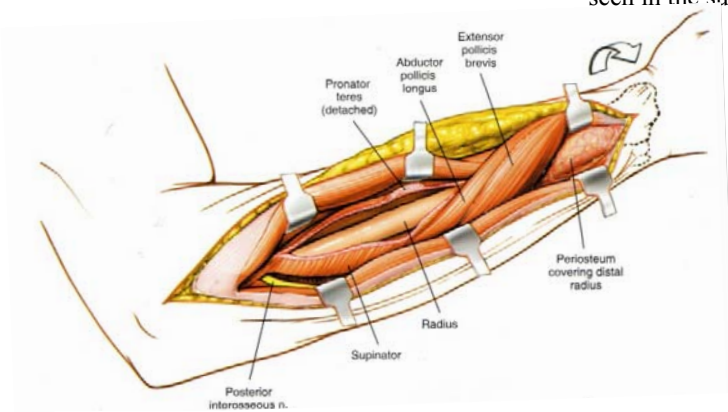
**Figure -9: Anterior Volar Henry's approach**



The long incision extends from just anterior to the lateral epicondyle of the humerus to just distal to the ulnar side of Lister's tubercle at the wrist



The supinator cloaks the upper third of the radius; the posterior interosseous nerve runs through its substance. The nerve must be protected and identified as it traverses the muscle. The interosseous nerve is seen in the substance of the supinator (inset).



Detach the insertion of the supinator from the anterior aspect of the radius, with the arm in full supination to bring the origin of the supinator into view and to move the posterior interosseous nerve away from the area of incision. This uncovers the lateral border of the radius.

**Figure-10: Posterior Thomson approach to the radius**

## **COMPLICATIONS**

### **Non union and Malunion**

Nonunion of fractures is most often seen when infection is present, when fixation is inadequate. Accurate open reduction and rigid internal fixation will prevent these complications. Fracture both bones forearm results in malunion if neglected and can be corrected by corrective osteotomy<sup>48</sup>.

### **Infection**

Despite all attempts to prevent infection, some open fractures and closed fractures treated by open reduction inevitably become infected. The incidence is higher in patients with extensive soft tissue injury. If infected, wound should be surgically drained, copiously irrigated, debrided and appropriate antibiotics instituted. The principle of the treatment is that union of the fracture must be obtained even in presence of the infection<sup>48</sup>.

### **Nerve injury**

They are uncommon in closed fracture of forearm bones. They are more common in compound wounds with extensive soft tissue loss. Posterior interosseous nerve may be injured when fixing proximal third radius by posterior approach<sup>48</sup>.

### **Vascular injury**

Radial artery may be injured when radius is approached anteriorly. The viability of the forearm and hand will not be a problem if one of the radial or the ulnar artery is patent. It is rare to have both radial and ulnar artery getting lacerated except in open fractures<sup>48</sup>.

## **Compartment syndrome**

This can occur either after trauma or after surgery on the forearm bones. They are usually due to faulty hemostasis or closure of the deep fascia. They can usually be avoided by releasing the tourniquet before wound closure to make sure hemostasis is adequate, by closing only the subcutaneous tissue and skin<sup>48</sup>.

## **Post-traumatic Radioulnar synostosis:**

Synostosis is relatively uncommon. Seen frequently in patients with either a crushing injury of forearm or a head injury. The highest risk for synostosis is in proximal fractures treated through single incision. If synostosis develops and position of forearm is relatively functional, it is best to do nothing. If rotational alignment of forearm is poor, an osteotomy to position the hand in more functional position can be considered.

Excision of the synostosis, obliteration of the dead space with muscle, prevention of hematoma formation and early mobilization have yielded good results<sup>48</sup>.

## **Refracture**

If the plate is removed early, minor trauma can cause refracture. It is best to keep plates for at least for 18 months to prevent refracture. Also after removal of plates protect the forearm at least for 6- 8wks<sup>48</sup>.

## **Muscle and Tendon Entrapment and Adherence**

Usually belly of tendon gets trapped between ends of bone. Release of the entrapped muscle belly results in full activity<sup>48</sup>.

## **METHODOLOGY**

In this study 40 patients with forearm fractures, were treated by ORIF with 3.5 mm dynamic compression plate (DCP) and screws, in patients with displaced fractures of the shaft of forearm bones. This study was conducted from October 2008 to April 2010 at Shri B M Patil Medical College Hospital and Research Centre.

### **Inclusion and Exclusion criteria**

#### **Inclusion Criteria:**

- Patient who has been diagnosed to have Radius and Ulna diaphyseal fractures.
- Patients of >20years of age of either sex.

#### **Exclusion criteria**

- Patients <20years of age.
- Minimally displaced stable Radius and Ulna fractures.
- Fractures associated with elbow dislocation.
- Patients with associated ipsilateral Humerus or Wrist fractures.
- Old fractures.

All patients admitted with acute diaphyseal fractures of the radius and ulna, a careful history was elicited from the patient and/or attendants to reveal the mechanism of injury and the severity of trauma.



The patients were then assessed clinically to evaluate their general condition and the local injury. It was done in accordance to Acute Trauma Life Support protocol. Vital parameters were recorded. Methodical examination was done to rule out fractures at other sites. Local examination of injured forearm and hand such as attitude and position of the affected upper limb compared with normal counterpart, any abnormal swelling and deformity, their level and direction.

**Palpation** to check any local rise of temperature, soft tissue tenderness, any palpable step, breach in continuity of bone, any revealed abnormal mobility, crepitus and shortening of the forearm.

**Distal vascularity** was assessed by radial artery pulsations, capillary filling, pallor and paraesthesia at finger tips.

**Neurological examination:** Sensory system was examined for pain and touch sensation in the radial. Ulnar and median nerve innervated areas. Power including handgrip was tested in forearm and hand muscles.

**Movements:** Flexion and extension of elbow, supination and pronation of forearm, Abduction and adduction and palmar flexion and dorsiflexion of the wrist were performed and any restriction of motion and pain observed.

## **Imaging**

The clinical signs and symptoms are usually obvious in shaft fractures of both bones of the forearm, so are the radiologic signs. The configuration of midshaft fractures of the radius and ulna varies depending on the mechanism of injury and the degree of violence involved. Low-

energy fractures tend to be transverse or short oblique, whereas high-energy injuries are frequently extensively comminuted or segmented, often with extensive soft tissue injuries.

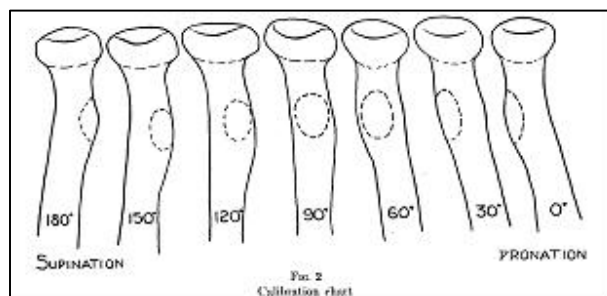
Radiographs of the radius and ulna i.e., anteroposterior and lateral views, were obtained. The elbow and wrist joints were included in each view.

The determination of the correct rotational position in which to immobilize fractures of both bones of the forearm is of importance, in that any degree of error will be followed by a corresponding limitation of rotational movement.

To achieve standardization, a constant technique must be employed to demonstrate what may be termed “**the tuberosity view**” by EVANS<sup>13</sup>. It is an anteroposterior view of the elbow joint taken with the tube at an angle of **20 degrees**; the tip of the olecranon is placed one-third of the way along the plate, with the elbow joint flexed to 90 degrees, and care is taken that both condyles of the humerus are at the same level.

The rotational position of the hand when this view is taken is of no importance, the only essential being the careful alignment of the elbow joint.

The X-ray can be compared with serial diagrams showing the prominence in supination. As an alternative, a film of the opposite elbow can be taken at a given degree of rotation for comparison. In this method full supination is referred to as 180° and mid position 90° and full pronation as 0°



**Figure -11: X-ray images of radial tuberosity at different levels of fracture**

The limb was then immobilized in above elbow Plaster of Paris slab with sling. Proximal radius was approached by dorsal Thompson incision and volar Henry approach was used for middle and distal radius. A narrow 3.5mm DCP was used and a minimum of 6 cortices were engaged with screw fixation in each fragment.

### **Preoperative planning:**

- Consent of the patient or relative was taken prior to the surgery.
- Appropriate length of the plate to be used was assessed with the help of radiographs.
- A dose of tetanus toxoid and antibiotic were given preoperatively.
- If evidence of compartment syndrome, surgery has to be done as soon as possible.
- Part Prepared.

## **INSTRUMENTS AND IMPLANTS USED IN DYNAMIC COMPRESSION**

### **PLATING FOR FOREARM BONES:**

- Drill and Drill Bit of 2.5mm and 3.5mm
- 3.5mm Drill sleeve system
- 3.5mm counter sink
- 3.5mm universal drill guide
- Depth gauge
- Tap for 3.5mm cortex screw
- 3.5mm Cortex Screws
- Plate Holding Clamp (Lowman's Clamp)
- Hexagonal Screwdriver

- Bending templates
- Bending press/pliers
- Narrow 3.5mm stainless steel DCP of varying length
- General instruments like Bone Holding Forceps, Periosteum Elevator, Bone Lever, and Bone Reduction Clamps.

## **Operative procedure**

**Type of anaesthesia:** General anaesthesia was used in 14 cases and brachial block in 6 cases.

### **Position**

Patient supine on the operating table

- Henry's approach-the arm is placed on an arm board with elbow straight and forearm in supination.
- Thompson approach-the arm is on the arm board, Elbow flexed and forearm in mid pronation.

Painting and draping of the part done.

### **Incision**

- Ulnar shaft: Parallel and slightly volar to the subcutaneous crest of the ulna.
- Radial shaft: Dorsal Thompson approach and Volar Henry's approach.

### **Procedure:**

Usually Ulna was fixed first, however the bone which was less comminuted and more stable was fixed first and later the other bone was fixed<sup>1</sup>.

After identifying the fracture ends, periosteum was not elevated and fracture ends were cleaned. Fracture was reduced. The contoured plate is applied to the bone with middle portion placed over the fracture, and held with reduction forceps for short oblique, or transverse fracture.

A plate hole is left vacant for angled lag screw through the plate in case of oblique fractures. This hole is used for interfragmentary compression of a lag screw. A plate of at least 6 holes was chosen and longer plates were used in spiral, segmental and comminuted fractures.

For upper third radial fractures, the plate was fixed dorsally. For middle third, the plate was fixed dorsolateral and for distal radial fractures the plate was fixed on the volar aspect.

In ulnar fractures, plate was applied over the posterior surface of ulna<sup>39</sup>.

In case of transverse and short oblique fractures plate hole adjacent to fracture is drilled first using neutral drill guide.

In case of oblique fractures, the first screw is applied to the fragment, which forms an obtuse angle with the fracture near the plate. The resulting space between the fracture plane and plate under surface guides the opposite fragment towards the plate.

The arrow of the neutral drill guide points towards the fracture. 2.5mm drill bit is used

for drilling a hole through both cortices and with depth gauge, appropriate 3.5mm screw length is determined.

The tap of 3.5mm is used to cut the thread. The chosen 3.5 mm cortex screw is inserted, but not fully tightened. The plate is pulled towards the fracture to place first eccentric screw.

The second screw hole for axial compression is drilled in the fragment which forms an acute angle near the plate.

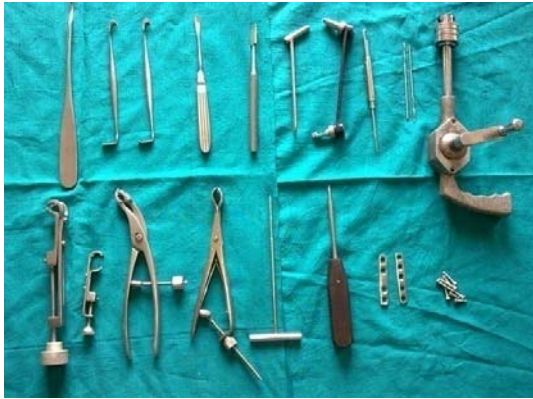The load guide (yellow) is used with the arrow pointing towards the fracture line to be compressed. At this position, a lag screw will be inserted. Tightening of the two screws produces axial compression.

The position of the oblique lag screw through the plate is determined. The angulation of the screw should not exceed +/- 25 degrees longitudinally and +/- 7 degrees transversely. The lag screw is applied by subsequently over drilling (3.5mm) the near cortex to create a gliding hole.

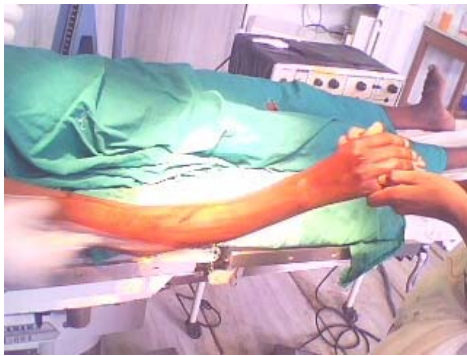If compression is sufficient the remaining screws are applied one by one, alternating from one side to the other.

In case of porotic, comminuted and/or small bones, long screws and/or a longer plate were used.

Finally tightening of all the screws. Haemostasis is maintained, the wound is closed in layers over a suction drain and sterile dressing is applied.



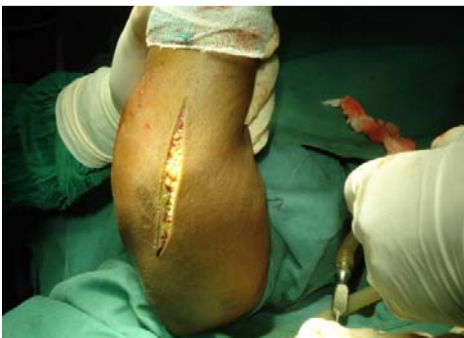**Instruments and implants used for surgery**



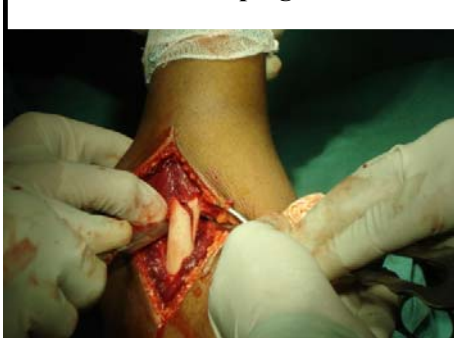**Painting**



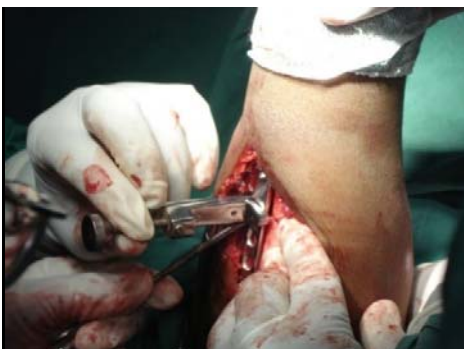**Draping**



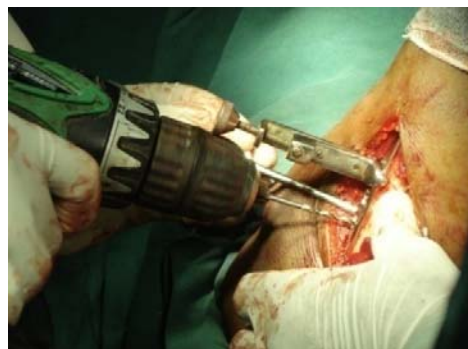**Skin incision and exposure (Ulna)**



**Exposure of fracture site**

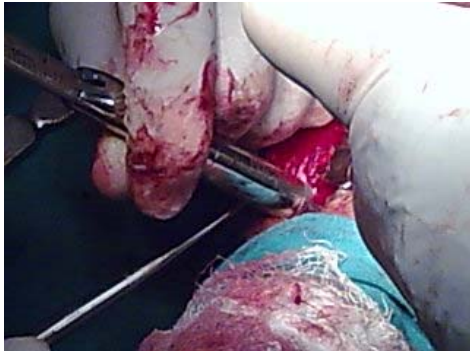

**Reduction of fracture and placement of plate**

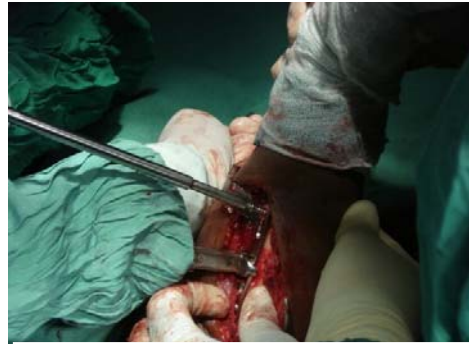

**Drilling for screws**

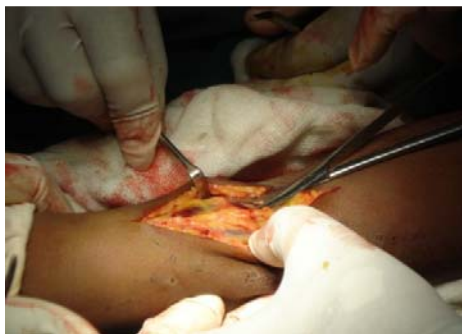**Figure -12: Instrument and procedure of the surgery**



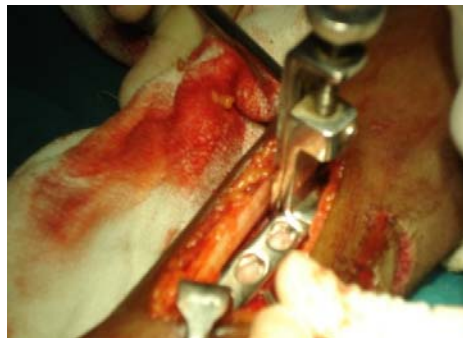
**Measuring screw length**



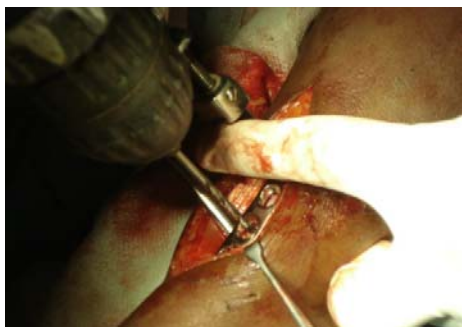**Fixation with screws**



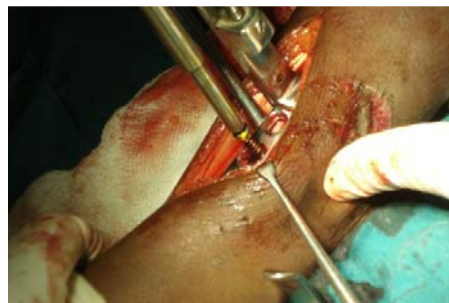**Incision and dissection for radius**



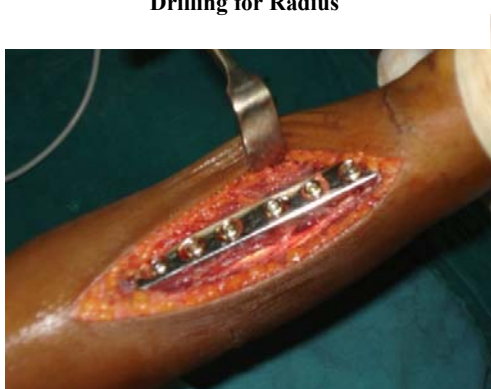
**Reduction of fracture and placement of plate**



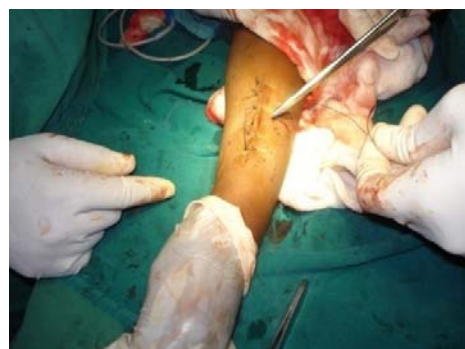**Drilling for Radius**



**Screw fixation**



**Good fixation with plate insitu**



**Skin closure**

**Figure -12: Procedure continued..**



Crepe bandage was applied over the affected forearm and either pre op posterior slab was continued or arm pouch was given depending upon the requirement.

Limb is elevated and active movement of the fingers and elbow joint is encouraged. Suction drain was removed after 48 hours and Wound was inspected. Check X ray AP and Lateral view was taken at that time.

Antibiotics and analgesics were continued till the time of suture removal which was done on 10-12 postoperative day.

On discharge patient was advised physiotherapy of shoulder, elbow, wrist and finger movements. They were told not to lift heavy weight or exert the affected forearm.

#### **Follow-up:**

The patients were followed regularly at monthly interval for first three months then every three months depending upon the outcome.

The patients were evaluated based on "**Anderson et al<sup>4</sup>**" scoring system. Elbow movements and wrist movements were noted and the union was assessed radiologically.

The fracture is said to be united when there was presence of periosteal callus bridging the fracture site and trabeculation extending across the fracture line.

"Anderson" et al scoring system (1975)<sup>4</sup>

**Criteria for Evaluation of Results**

<b>Results</b>	<b>Union</b>	<b>Flexion/Extension at elbow joint and wrist</b>	<b>Supination and pronation of forearm</b>
Excellent	Present	<10 <sup>0</sup> loss	<25% loss
Satisfactory	Present	<20 <sup>0</sup> loss	<50% loss
Unsatisfactory	Present	>20 <sup>0</sup> loss	>50% loss
Failure	Non union with or without loss of motion		

## RESULTS

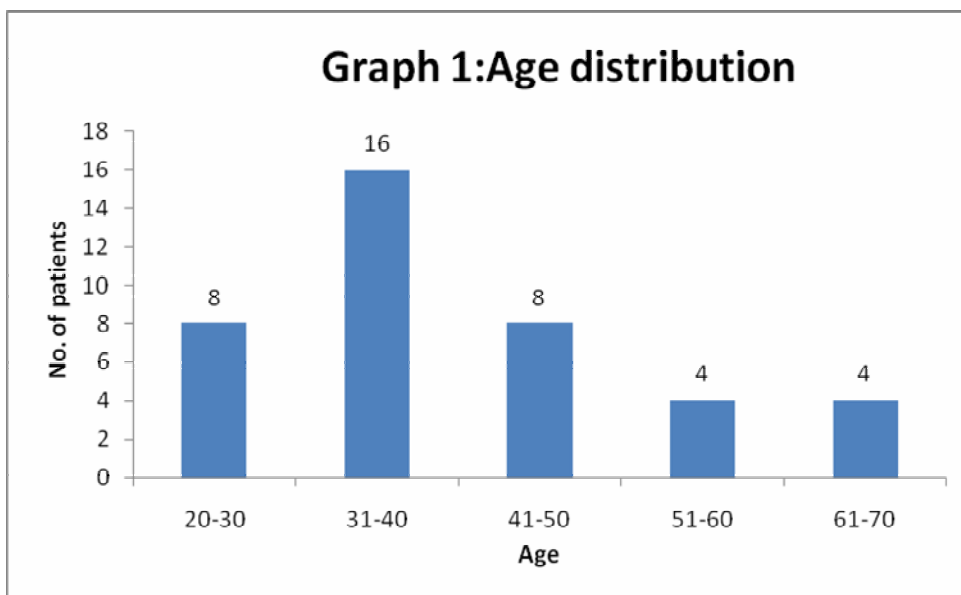
In this study, 40 patients with displaced fractures of the shaft of forearm bones were treated by open reduction and internal fixation with 3.5 mm dynamic compression plate (DCP) and screws. This study was conducted from October 2008 to April 2010 at Shri B M Patil Medical College Hospital and Research centre, Bijapur.

### 1. Age Distribution

The age of these patients ranged from 20-70 years and average age was 40.7 years.

**Table-1: Age Distribution**

Age	Number of Patients	Percentage
20-30	8	20
31-40	16	40
41-50	8	20
51-60	4	10
61-70	4	10
<b>Total</b>	<b>40</b>	<b>100</b>

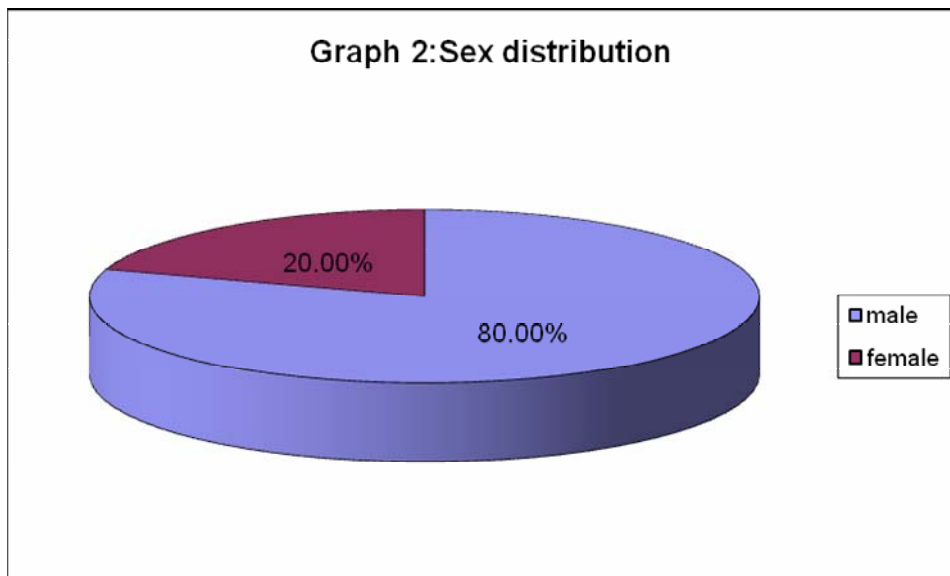


## 2. Sex Distribution:

Out of 40 patients, 32 patients (80%) were males and 8 patients (20%) were females showing male preponderance because of working in fields, travelling, factories, and sports.

**Table-2: Sex Distribution**

Sex	Number of Patients	Percentage
Male	32	80
Female	8	20
<b>Total</b>	<b>40</b>	<b>100</b>

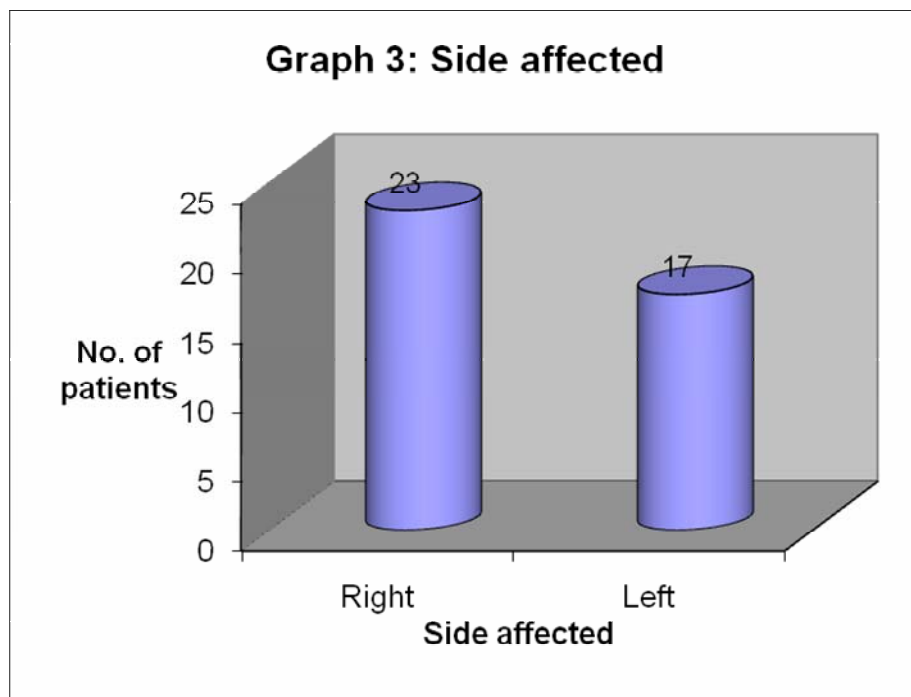


### 3. Side Affected

There were 23 (57.5%) patients with right forearm fracture and 17(42.5%) patients with left forearm fracture.

**Table-3: Side Affected**

Side affected	Number of Patients	Percentage
Right forearm	23	57.5
Left forearm	17	42.5
<b>Total</b>	<b>40</b>	<b>100.00</b>

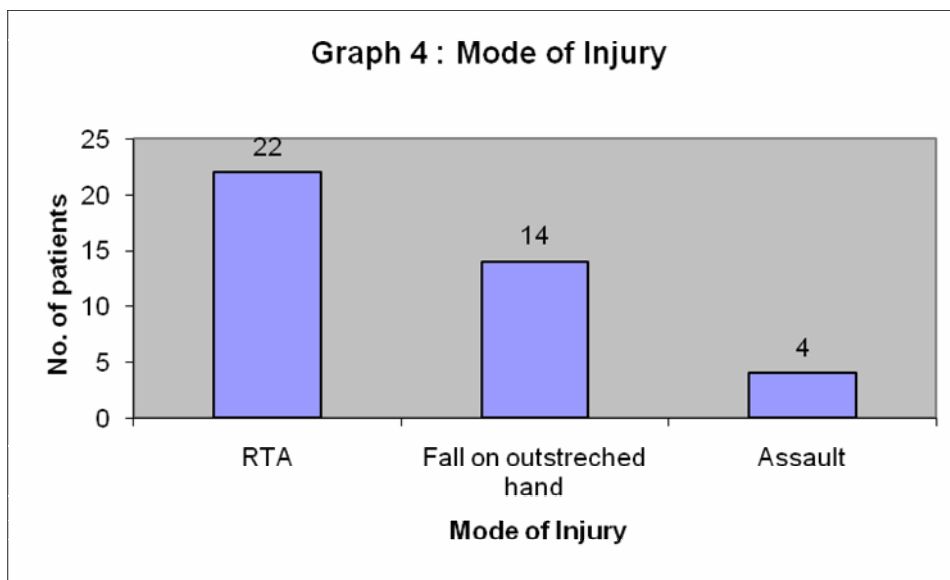


#### 4. Mode of Injury

In our study, there were 22(55%) patients with road traffic accident, 14(35%) patients with fall, and 4(10%) patients with assault.

**Table-4: Mode of Injury**

<b>Mode of injury</b>	<b>Number of patients</b>	<b>Percentage</b>
RTA	22	55
Fall on out stretched hand	14	35
Assault	4	10
<b>Total</b>	<b>40</b>	<b>100</b>



#### 5. Fracture characteristics:

**a. Clinical**

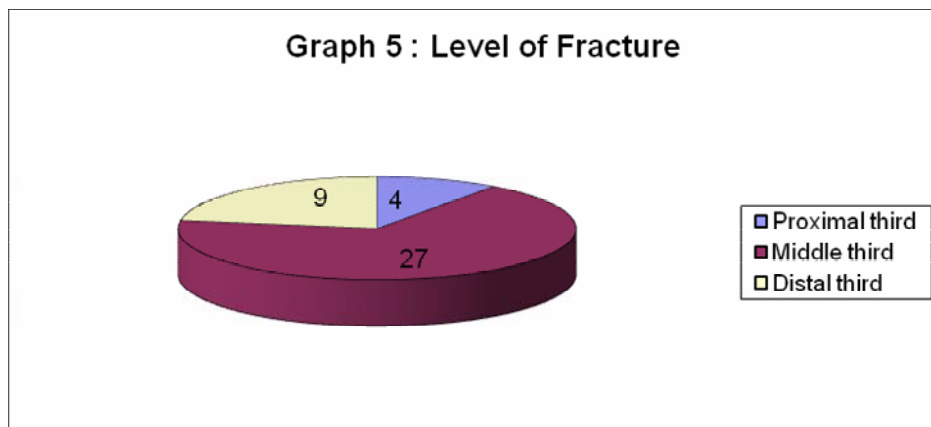
All the fractures were closed injuries.

**b. Level of fracture**

Majority of the fractures were seen in the mid diaphysis of both bones of forearm. 27 (68%) patients had mid diaphysial fractures, 4 (10%) had proximal third fractures and 9 (22%) patients had distal third fracture of both bones of forearm.

**Table -5: Level of Fracture**

Level of fracture	Number of Patients	Percentage
Proximal third	4	10
Middle third	27	68
Distal third	9	22
<b>Total</b>	<b>40</b>	<b>100</b>



**c. Type of the fracture**

As we have included diaphyseal fractures of both bones, in total we had total of 40 radius shaft

fractures and 40 ulna fractures.

Among 40 radius fractures, 25(62.5%) were Transverse/short oblique type and 15(37.5%) were comminuted variety.

**Table -6: Type of the Fracture (Radius)**

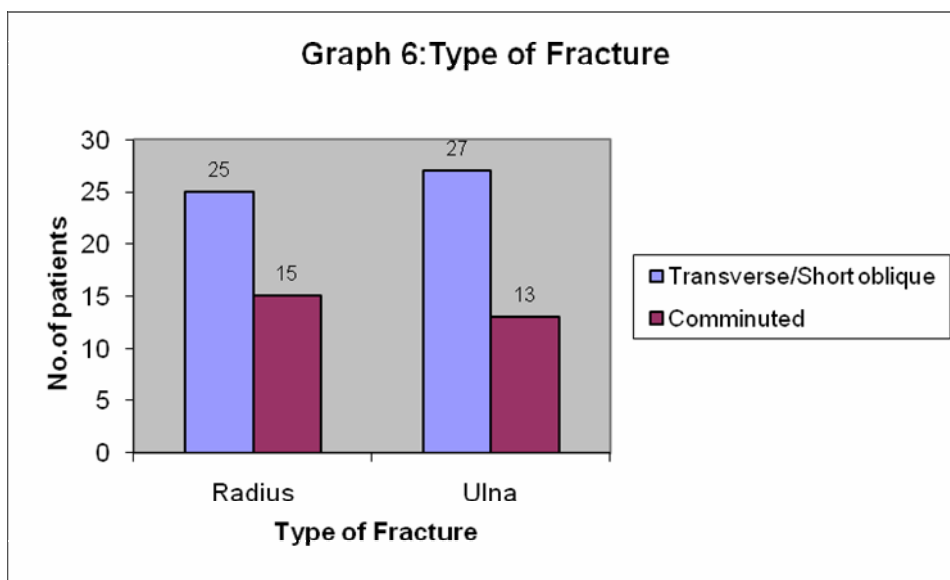
Type of fracture	Radius	Percentage
Transverse/short oblique	25	62.5
Comminuted	15	37.5
Segmental	---	---
<b>Total</b>	<b>40</b>	<b>100</b>

Among 40 ulna fractures, 27(67.5%) were Transverse/short oblique type and 13(32.5%) were comminuted variety.

**Table-7: Type of the Fracture (Ulna)**

Type of fracture	Ulna	Percentage
Transverse/short oblique	27	67.5
Comminuted	13	32.5
Segmental	-----	-----
<b>Total</b>	<b>40</b>	<b>100</b>





#### 6. Associated injuries:

5 (12.5%) of the patients had associated injuries.

**Table-8: Associated Injuries**

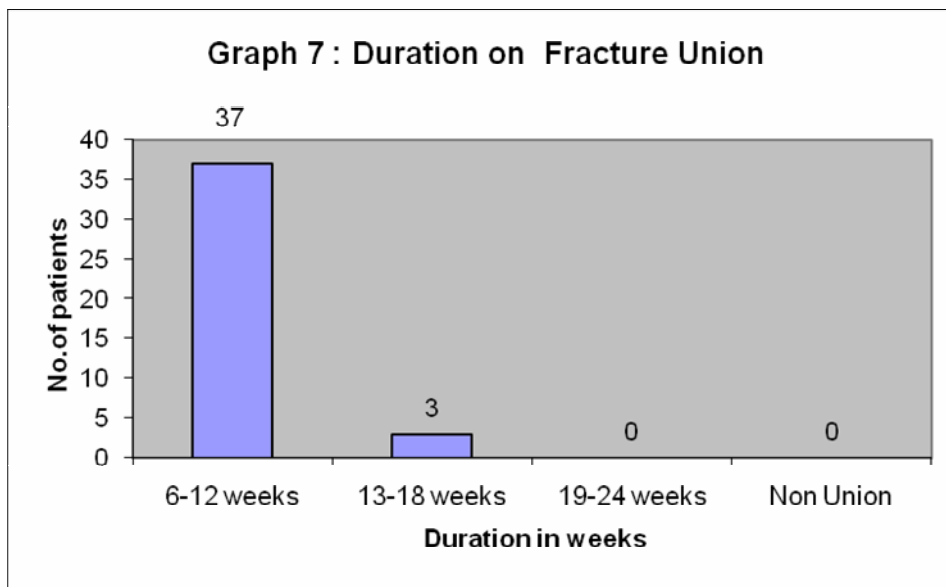
Associated injuries	Number of Cases	Percentage
Fracture of the shaft of femur	1	2.5
Metatarsal fractures	3	7.5
Fracture of both bones of leg	1	2.5
<b>Total</b>	<b>5</b>	<b>12.5</b>

## 7. Duration of Fracture union:

The fracture was considered as united when there were no subjective complaints, radiologically when the fracture line was not visible.

**Table-9: Duration of Fracture Union**

<b>Time of union</b>	<b>Number of patients</b>	<b>Percentage</b>
6-12 Weeks	37	92.5
13-18 Weeks	3	7.5
19-24 Weeks	0	0
Non Union	0	0
<b>Total</b>	<b>40</b>	<b>100</b>

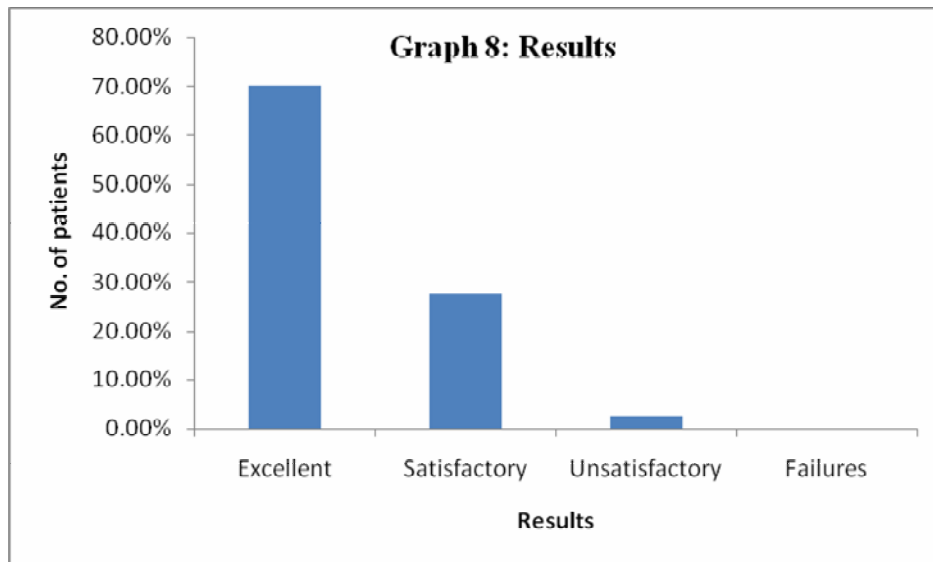

## 8. Results

Using the Anderson et al scoring system we had 28(70%) patients with excellent results, 11 (27.5%) patients with satisfactory results and 1(2.5%) patient with unsatisfactory result.

**Table-10: Results**

Results	Number of Patients	Percentage
Excellent	28	70
Satisfactory	11	27.5
Unsatisfactory	1	2.5
Failure	0	0
Total	40	100

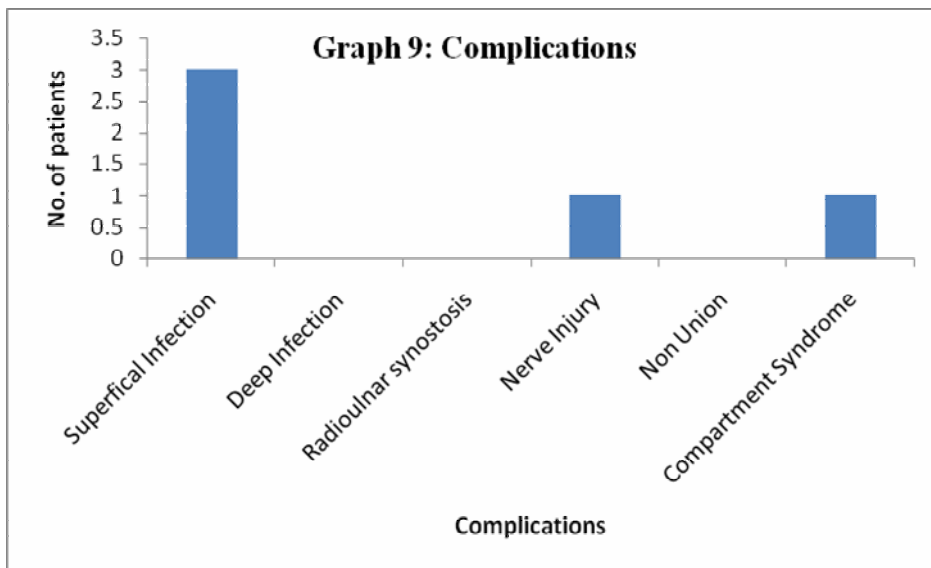


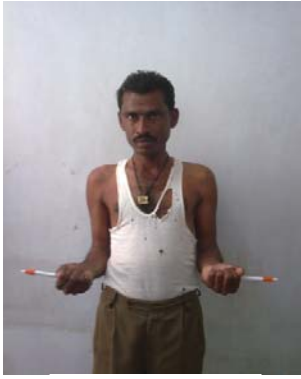## 9. Complications

We had complications in about 5(12.5%) patients with the following type.

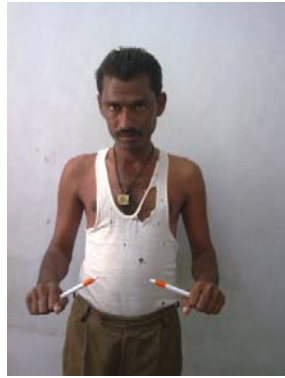**Table-11: Complications**

<b>Complications</b>	<b>Number of cases</b>	<b>Percentage</b>
Superficial infection	3	7.5
Deep infection	0	0
Radioulnar synostosis	0	0
Nerve injury-Posterior interosseous nerve injury	1	2.5
Non Union	0	0
Compartment Syndrome	1	2.5
<b>Total</b>	<b>5</b>	<b>12.5</b>





Supination



Pronation



Elbow flexion



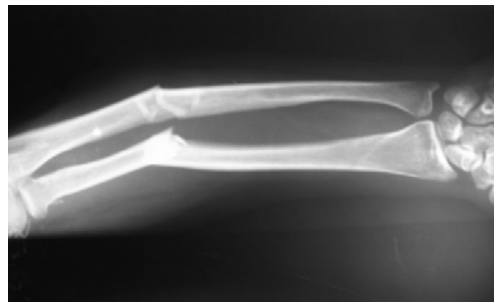Wrist dorsi flexion



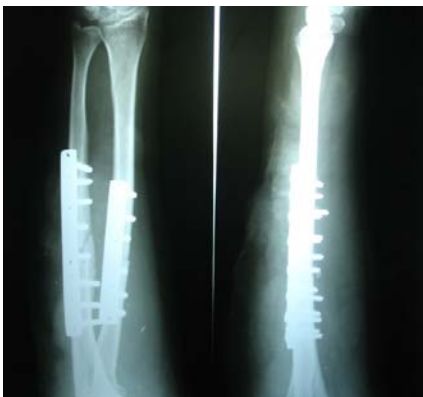Wrist palmar flexion



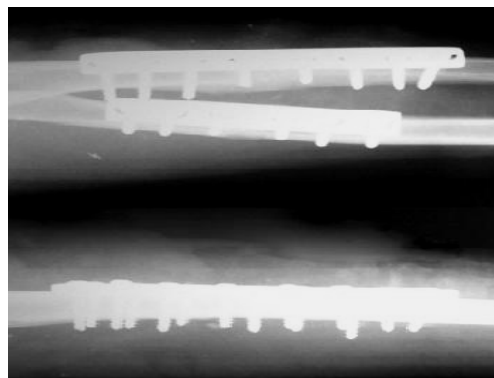
Elbow extension



Pre operative X-ray



Immediate post Op X-ray

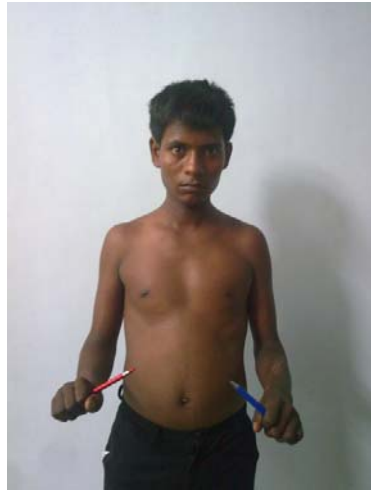

24 weeks Post Surgery

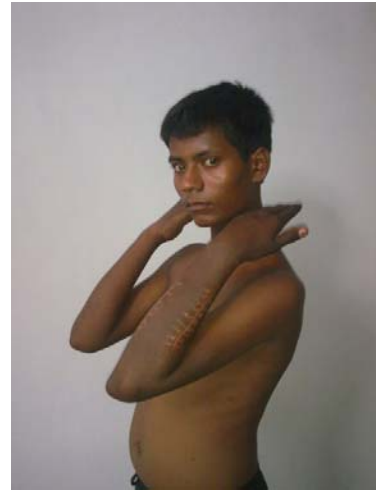**CASE NO. 3: WITH EXCELLENT RESULTS**



Supination



Pronation



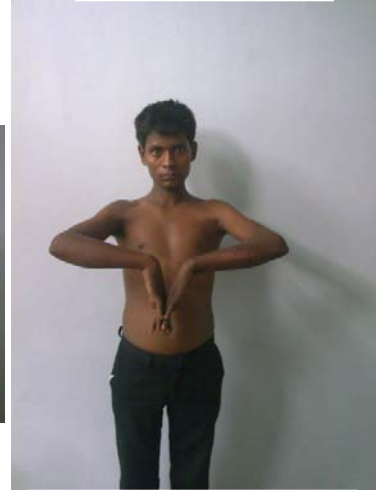Elbow flexion



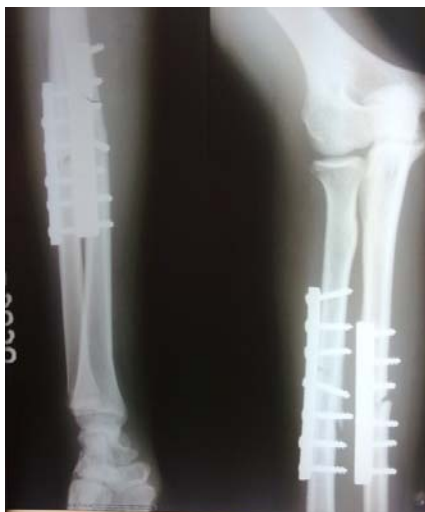Wrist dorsi flexion



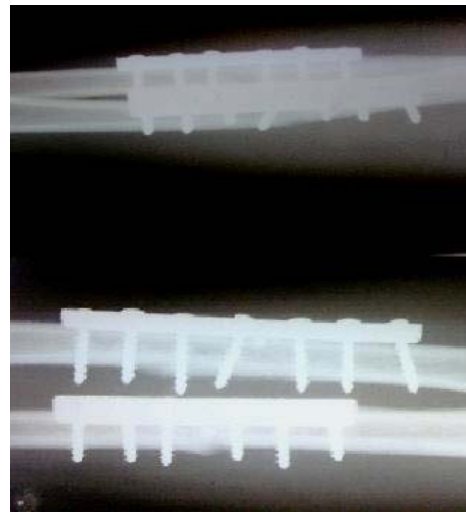
Elbow extension



Wrist palmar flexion



Immediate post Op X-ray



12 weeks Post Surgery

**CASE NO. 15: WITH EXCELLENT RESULTS**

## DISCUSSION

The forearm, being a component of upper limb serves important movements required in activities of daily living. The forearm, allows pronation and supination which in turn helps hand, to perform multi axial movements.

Fracture of the forearm bones may result in severe loss of function unless adequately treated. Hence good anatomical reduction and internal fixation of these fractures is necessary to restore function<sup>1</sup>.

This study was conducted at our hospital with the aim to know the importance of anatomical reduction and rigid fixation of forearm diaphyseal fractures with 3.5 mm DCP. This in turn was reciprocated on the functional results obtained.

We evaluated our results and compared them with those obtained by various other studies. Our analysis is as follows.

### **1. Age distribution:**

In our study, age of the patients ranged from 20-70 years with an average age of 40.7 years.

H.Nevile Burwell and A.D. Charnley in 1964 witnessed 50% of the patients between second and third decade and an average of 44.8years<sup>12</sup>.

Our findings are comparable to the study made by, H.Nevile Burwell and A.D. Charnley series which showed average age as 44.8years<sup>12</sup>.

In 1972, Herbert S.Dodge and Gerald W.Cady found 24 years as the average age in their series<sup>2</sup>.

Berton R.Moed(1986) found the average age was 22years<sup>25</sup>.

**Table-13: Age Distribution Comparison**

<b>Series</b>	<b>Min.age(yrs)</b>	<b>Max. age(yrs)</b>	<b>Average(yrs)</b>
Michael Chapman	13	79	33
Marek	12	75	31
Moed B.R	14	65	22
Herbert Dodge	13	59	24
H.N.Burwell	16	57	44.8
<b>Present study</b>	<b>20</b>	<b>70</b>	<b>40.7</b>

## **2. Sex distribution:**

Our series had male preponderance with 32(80 %) male patients and 8(20%) female patients which were comparable to previous studies.

Michael Chapman noted about 78% males and 22% females<sup>22</sup>.

William in his series had 67% of males and 33% of females<sup>52</sup>.

H.Dodge in his study noted about 89% males and 11% females<sup>2</sup>.

Talwalkar in his series had 80% males and 20% females<sup>53</sup>.



**Table-14: Sex distribution comparison**

<b>Series</b>	<b>Males (%)</b>	<b>Females (%)</b>
M.Chapman	78	22
Talwalkar	80	20
William A.T	67	33
H.Dodge	89	11
<b>Present study</b>	<b>80</b>	<b>20</b>

**3. Extremity affected:**

We had about 23(57.5%) incidence of forearm fractures in right extremity, and 17(42.5%) in left extremity which is also comparable to the previous studies.

M. W. Chapman reported about 55% incidence of fractures in right extremity<sup>22</sup>.

H. N. Burwell and A. D. Charnley reported about 50% incidence of fracture in right arm<sup>12</sup>.

**Table 15: Extremity Affected**

<b>Series</b>	<b>Right (%)</b>	<b>Left (%)</b>
H.N.Burwell	50	50
M.W.Chapman	55	45
<b>Present study</b>	<b>57.5</b>	<b>42.5</b>

#### 4. Mode of injury:

In our series 22(55%) of cases had road traffic accident, 14(35%) had fall, and 4(10%) with history of assault.

Moed B. R. et al. accounted 50% of his cases to road traffic accident, 20% due to industrial accident, 14% due to fall, 12% due to direct blow and 4% due to gunshot injuries<sup>2</sup>.

Smith noted about 45% of his cases was due to RTA, 36% were due to fall and 19% were due to industrial accidents<sup>11,50</sup>.

Talwalkar series had 26.6% of his cases to road traffic accident, 16.6% due to industrial accident, 50% due to fall and 6.6% due to direct blow<sup>53</sup>.

Our series is comparable to Smith series.

**Table-16: Mode of Injury comparison**

<b>Series</b>	<b>Accident (%)</b>	<b>Fall (%)</b>	<b>Direct blow/assault (%)</b>	<b>Industrial accident/fall of heavy object</b>
Moed	70	14	16	
Smith	45	36	19	
Talwalkar	26.6	50	6.6	16.6
<b>Present study</b>	<b>55</b>	<b>35</b>	<b>10</b>	

## **5. Fracture anatomy**

### **a. Type of fracture:**

As we had included diaphyseal fractures of both bones in our study, in total we had total of 40 radius shaft fractures and 40 ulna fractures.

Among 40 radius, 25(62.5%) were Transverse/short oblique type and 15(37.5%) were comminuted variety.

Among 40 ulna, 27(67.5%) were Transverse/short oblique type and 13(32.5%) were comminuted variety.

M. W. Chapman et al, series noted about 53% of fractures as comminuted and 47% were transverse/short oblique

On an average we had 65% with Transverse/short oblique type and 35% were comminuted variety. Ours were not comparable to any of the studies available.

### **b. Level of fracture:**

M. W. Chapman et al noted about 59% and 61% of fractures in middle third of Radius and ulna, 13% and 21% in proximal third of radius and ulna and 28% and 12% in lower third of radius and ulna respectively<sup>22</sup>.

A.Sarmiento et al, noted about 84.6% of fracture both bones were in middle third and 15.4% of cases had lower third fracture of both bones<sup>13</sup>.

H.S. Dodge and G.W. Cady documented 71.5% fracture both bones n middle third,

21.5% in distal third and 7% in proximal third<sup>2</sup>.

Our series had 68% of fractures in middle third, 10% in proximal third and 22% in lower third, comparable to previous studies.

## **6. Time of union:**

Anderson's criteria for evaluation of union were taken into account. In our study we had an average union time of 8.8 weeks.

Anderson's et al showed average union time of around 7.4 weeks with range of 5 to 10 weeks, 97% of the cases united<sup>4</sup>.

Chapman in a study had 98% union with range of 6 to 14 weeks union the average union time was 12 weeks<sup>22</sup>.

The present series had average union time of 8.8 weeks with a range of 6 to 12 weeks. The results of our present studies are comparable to the previous studies.

## **7. Functional results:**

The range of motion was determined and Anderson et al, scoring system was used as a measure for the functional outcome<sup>4</sup>.

Chapman et al reported 36 (86%) cases as excellent, 3 (7%) satisfactory, 1 (2%) unsatisfactory and 2 (5%) failure<sup>22</sup>.

Anderson et al reported about 54 (50.9%) cases as excellent, 37 (34.9%) satisfactory, 12 (11.3%) unsatisfactory and 2 (2.9%) failure<sup>4</sup>.

Our series had 28(70%) of excellent, 11(27.5%) satisfactory results, 1(2.5%)

unsatisfactory results which is comparable to the previous studies.

Unsatisfactory result was seen in a female patient with comminuted fracture. The patient was uncooperative where she didn't follow physiotherapy properly.

## **8. Complications**

In our series we had 3 cases of superficial infection. The wound was debrided, pus sent for culture. They resolved with appropriate antibiotics.

A case of posterior interosseous nerve palsy noted after surgery where radius was approached in proximal third through dorsal Thompson approach. Patient was treated conservatively and there was resolution of the nerve injury by 2 months.

A case of compartment syndrome was observed which was treated by fasciotomy.

## CONCLUSION

### **Based on our experience and results we conclude:**

Diaphyseal fractures of forearm are seen most commonly in middle aged subjects.

Males show high incidence of fractures as they are often engaged in agriculture, industrial work and motor vehicle driving.

The cause of fractures is mostly due to road traffic accident and fall on an outstretched hand.

Majority of the fractures were transverse/short oblique in the middle third region of forearm.

With the use of AO/ASIF 3.5 mm DCP for acute diaphyseal fractures of forearm, rigid and anatomical fixation can be achieved.

With the use of DCP, distraction forces leading to separation fracture fragments as seen in interlocking nail for upper limb is not possible.

Radial bow is very important for normal supination and pronation. This can be maintained very well with compression plates.

A minimum of 6 cortices should engage in each fracture fragment. It is better to use longer plates like a bridge plate in case of comminuted oblique fractures.

Radius and Ulna are approached separately to avoid extensive soft tissue dissection and

resulting complication.

Post operatively with DCP fixation additional supportive measures may not be required after soft tissue healing and shoulder, elbow and wrist movements can be started early. This helps prevent muscle atrophy and joint stiffness. It is very much possible in intelligent and cooperative patients. However all patients should be curtailed from lifting heavy weights till union of fracture.

Almost all fractures in our study united by 3 months.

The AO principles of internal fixation namely (1) Anatomical fixation, (2) Preservation of vascularity, (3) Mechanically stable fixation, (4) Rapid mobilization of joints in proximity, can be achieved with compression plating system.

With rigid/anatomical internal fixation, dynamic compression plate is a good fixation for displaced diaphyseal fractures of the forearm bones. Adherence to AO principles, strict asepsis, proper post operative rehabilitation and patient education are more important to obtain excellent results.

## **SUMMARY**

In our study 40 patients with closed diaphyseal fractures of both bones of forearm were treated with open reduction and internal fixation with AO/ASIF 3.5 mm DCP and screw.

There were 32 male and 8 female patients in the study.

Most of the patients were of age group from 20 to 70 years with average age of 40.7 years.

Most of the fractures were in middle third region with transverse and short oblique type.

Separate incisions were used for radius and ulna. In most cases 6-8 holed plate was used.

On an average follow up period of these patients were 24 weeks.

The results were correlated under Anderson et al, scoring system. There were 28 (70%) patients with excellent results, 11 (27.5%) patients with satisfactory results, and 1(2.5%) patient with unsatisfactory result.

Unstisfactory was due to comminution of fracture (prolonged immobilisation) and patient non cooperation for instructions.



## BIBLIOGRAPHY

1. Richards RR. Fractures of the shafts of the radius and ulna. In. Bucholz RW, Heckman JD, editors. Rockwood and Green's fractures in adults. 5<sup>th</sup> ed. Philadelphia, USA: Lippincott Williams and Wilkins; 2001; p.869-917.
2. Dodge, Herbert S. and Gerald W. Cady, Treatment of fractures of the radius and ulna with compression plates. *J Bone Joint Surg.* 1972; 54-A(6): 1167-1176.
3. S Hidaka and RB Gustilo. Refracture of bones of the forearm after plate removal *J Bone Joint Surg Am.* 1984; 66:1241-1243.
4. L.D.Anderson,Sisk.D,Tooms.RE and ParkW.I Compression plate fixation in acute diaphyseal fractures of the radius and ulna *J. Bone Joint Surg. Am.*, Apr 1975; 57: 287.
5. William a Clark. History of fracture treatment. *J.bone Joint Surg. Am.*,1937;19:47-63
6. Colton C.: History of Osteosynthesis. Chapter-2, in *AO/ASIF Instruments and implants* 2nd edn, Texhammer R and C. Colton, Berlin, Springer Verlag, 1994:3pp.
7. Patrick J. A study of supination and pronation with special reference to the treatment of forearm fractures. *J Bone Joint Surg* 1946 Oct; 28:737-748.
8. Chandler R. N.: Principles of Internal Fixation. Chapter-3, in *Fractures in Adults, Vol. 1,* 4th Edn., Rockwood C. A. Jr. et al, Philadelphia; Lippincott Raven, 1996: 159pp.
9. Roger.Anderson.Fractures of the radius and ulna. A new anatomical method of treatment. *J. Bone Joint Surg. Am.*, Apr 1934; 16: 379 - 393.
10. Crenshaw, Andrew H.: Fractures of shoulder girdle, Arm and Forearm. Chapter-49, in *Campbells Operative Orthopaedics*, Edt. Canale, S. Tery, Mosby, 2003: 3042-3058.
11. Smith. J. E. M : Internal Fixation in the Treatment of Fractures of the shaft of Radius and Ulna in Adults , *J. Bone & Joint Surg*, 1959, 41 (B) No. 1, 122-131.

12. Burwell, H. N and Charnley. D. A. Treatment of Forearm fractures in adults with particular reference to plate fixation, *J. Bone & Joint Surg.* 1964, 46-B(3), 404-424.
13. Sarmiento, Augusto, Cooper. S .J. and Sinclair F. W. Forearm fractures. *J Bone & Joint Surg.* 1975:57-A (3): 297-304.
14. Perren.S.M. Physical and biological aspects of fracture healing with special reference to internal fixation. *Clin. orthop.* 1979.138; 175-196pp.
15. Grace J. G. and Eversmann W. W. J. R., Forearm fractures treated by rigid fixation with early motion. *J Bone & Joint surg.* 1980.68-A: 43-438.
16. Hadden WA, Reschauer R, Seggl W. Results of AO plate fixation of forearm shaft fractures in adults. *Injury.* 1983;15:44-52.
17. Allgower, M., Ehram, R., Ganz, R. et al. Clinical experience with a new compression plate "DCP". *Acta Orthop. Scand.* 1969 Suppl., v.125, p.45-63,
18. Garland DE. Forearm fractures in head injured adults. *Clin Orthop* 1982; 176:190-195.
19. Stern PJ, Drury WJ. Complications of plate fixation of forearm fractures. *Clin Orthop* 1983; 175:25-9.
20. Shah K.M., Divetia P.A. Management of diaphyseal fractures of forearm bones. An evolution-Clinical orthopaedics India, 1988.3; 51-56.
21. Ghazi RM, Haves M. Entrapment of flexor digitorum profundus in the ulna with fracture of both bones of forearm. *J Bone Joint Surg* 1986; 68A: 1102-1103.
22. Chapman MW, Gordon JE, and Zissimos AO Compression-plate fixation of acute fractures of the diaphyses of the radius and ulna. *J. Bone Joint Surg. Am.*, Feb 1989; 71: 159 - 169.
23. Watson-Jones. *Fracture and Joint injuries.* 6th ed. Churchill Livingstone; 1982.

24. Schemitsch, Emil H. and Richards. R.R .The effect of malunion on functional outcome after plate fixation of fracture of both bones of forearm in adults. *J Bone & Joint surg*, 1992; 74\_A (7). 1068-1078.
25. Moed BR, Kellam JF, Foster RJ, Tile M, and Hansen ST Immediate internal fixation of open fractures of the diaphysis of the forearm *J. Bone Joint Surg. Am.*, Sep 1986; 68: 1008 - 1017.
26. Iversen LD, Swiontkowski MF. *Manual of acute orthopaedic therapeutics*, 4th ed. 1994; 64-66.
27. *Campbell's Operative Orthopaedics*. 10th ed. Canale ST (ed). 3:3044-3045.
28. Miclau T, A mechanical comparison of the DCP, LC-DCP and point contact fixator. *J Orthop Trauma*, 1995;9(1): 17-22.
29. Ronald McRae, Max Esser. *Practical fracture treatment*. 2002; 4th ed. 178.
30. Perren S. M. Basic Aspects of Internal Fixation. Chapter-1, in *Manual of Internal Fixation*, 3rd Edn., Allgower M., et al, Berlin, Springer Verlag,1991.1
31. Tscherne H, Hass N, Drettek C. Intramedullary nailing combined with cerlage wiring in the treatment of fractures of the femoral shaft. *Clin Orthop* 1986; 212:62-67.
32. UhthoffHK, Bardos OJ, Liskova Kiar M. The advantages of titanium alloy over stainless steel plates for the internal fixation of fractures. An experimental study in dogs. *J Bone Joint Surg* 1981; 63B:427-484.
33. Ivica M, Tomijenovit ML, Krolo I. Forearm shaft fractures: Results of ten-year follow up. *Acta Clin Croat*, 2000; 39:147-53.
34. Goldfarb Ca, Ricci WM, Tull F, Ray D, Boreelli T. Functional outcome after fracture of both bones of the forearm. *J Bone Joint Surg*. 2005; 87-B (Issue-3): 374-79.

35. Wang JP, Chuiu Fy, Chen CM et al. Surgical treatment of open diaphyseal fracture of both the radius and ulna. *J Chin Med Assoc.* 2005; 68(8): 379-82.
36. Refracture of Bones of the Forearm after the Removal of Compression Plates. PA Deluca, RW Lindsey and PA Ruwe. *J Bone Joint Surg Am.* 1988; 70:1372-1376.}
37. The use of semi-rigid carbon-fibre-reinforced plastic plates for fixation of human fractures-results of preliminary trials-keith tayton, british editorial society of bone and joint surgery-1982-vol. 64-b, no. I. 1982-pg 105-111.
38. Thakur A. J. Bone plates. Chapter-4 in the elements of fracture fixation, Churchill Livingstone, New Delhi, 1997: 57-79pp.
39. GW Bagby *J Bone Joint Surg Am.* 1977;59:625-631.Compression bone-plating: historical considerations
40. Texhammer R.: AO/ASIF Instrumentation. Chapter-6 in AO/ASIF Instruments and implants 2nd edn, Texhammer R and C. Colton, Berlin, Springer Verlag, 1994: 84-86.
41. Perren S. M. Basic Aspects of Internal Fixation. Chapter-1, in Manual of Internal Fixation, 3rd Edn., Allgower M., et al, Berlin, Springer Verlag,1991.1
42. Richards, Robin R., Chronic Disorders of the Forearm-Current Concepts Review *June 1996, Volume 78-A, Number 6 ;916-30*
43. William j. Larsen; human embryology 1 edition; page 281-286.
44. Gray. Henry: Osteology, forearm muscles in Gray's Anatomy Edt. Williams, Peter L et al., Norwich, Churchill Livingstone, 1989, 410-415pp.
45. EH Schemitsch and RR Richards .The Effect of Malunion on Functional Outcome after Plate Fixation of Fractures of Both Bones of the Forearm in Adults. *J Bone Joint Surg Am.* 1992; 74:1068-1078.

46. Mori.k; experimental study on rotation of the fore arm-functional anatomy of interosseous membrane. J.Japanese orthop assn. 1985:59:611-622
47. Morrey B F. A biomechanical study of normal functional elbow motion. JBJS. Jul 1981 : 63-A :872-877
48. Richards, R.R: Fractures of the shafts of the radius and ulna. Chapter-13 in Rockwood and Green's fractures in adults, Bucholz.R.W. And Heckman J.D, Charles M.C. Philadelphia-Lippincott Williams & Wilkins, 2001: 869-915.
49. S. Terry Canale, James H. Beaty, Campbell's operative orthopaedics.—11th Ed, vol 3:3425-3426. MOSBY ELSEVIER,Philadelphia, Pennsylvania 19103-2899
50. Smith H. and Sage F.P.Medullary fixation of forearm fractures. J. Bone Joint Surg. Am., Jan 1957; 39: 91 – 188
51. Hoppenfeld: The forearm. Chapter-4 in Surgical exposures in orthopaedics, 2nd Edn, Philadelphia; Lippincott Raven Publishers,1999:117-133.
52. Teipner, William A. and. Mast W. J. Internal Fixation of Forearm Diaphyseal fractures; double plating versus single compression plating, Orthop Clin of NAm, 1980: 11(3): 381-391.
53. A.K.Talwalkar. Treatment of simple fractures of radius and ulna with internal fixation without external support. Singapore medical journal. Vol 8, No 3, September 1967.

## ANNEXURE - I

### PROFORMA

Name :  
Age : Sex: I.P.No:  
Occupation : D.O.A:  
Address : D.O.S:  
Date of injury : D.O.D:

1. **COMPLAINTS:**
2. **MODE OF INJURY:**
3. **HISTORY OF PRESENTING ILLNESS:**
4. **PAST HISTORY:**
5. **FAMILY HISTORY:**
6. **GENERAL PHYSICAL EXAMINATION:**
  - a. pallor : cyanosis:
  - b. pulse : B.P:
7. **SYSTEMIC EXAMINATION:**
  - a. C.V.S: R.S:
  - b. P.A : C.N.S:
8. **LOCAL EXAMINATION:**

Inspection:

  - a. Attitude

- b. Swelling
- c. Loss of function
- d. Bruises/Laceration
- e. Associated soft tissue injury
- f. Deformity.

Palpation:

- a. Tenderness
- b. Abnormal mobility
- c. Crepitus
- d. Shortening
- e. Bony irregularity
- f. Swelling
- g. Wound

**9 MOVEMENTS:**

- a. Elbow : Flexion ; Extension  
Supination ; Pronation

**10 NEUROLOGICAL STATUS:**

**11 VASCULAR STATUS:**

**12 MUSCULAR STATUS:**

**13 INVESTIGATIONS:**

Blood: Hb%: TC: DC: ESR:

Urine: Albumin: Sugar: Microscopy:

BT: CT:

Blood grouping and typing:

RBS: Blood urea: Serum creatinine:

HIV: HbsAg:

ECG: in elderly

X-ray:

A.P & Lat:

No.:

Date:

Report:

**14 CLASSIFICATIONS:**

AO TYPE

TYPE- A	A1	A2	A3
TYPE- B	B1	B2	B3
TYPE- C	C1	C2	C3

ANAESTHESIA:

SURGERY:

DATE AND TIME:

DURATION:

APPROACH/INCISION AND PORTAL OF ENTRY:

TYPE OF PLATE:

SIZE OF PLATE:



BONE GRAFTING (Y/N)

**IMMEDIATE POST OPERATIVE CARE:**

**FOLLOW UP:**

DURATION	PAIN	TENDERNESS	X- RAY FINDINGS	MOVEMENTS
6 WK				WRIST:  FOREARM:  ELBOW:  SHOULDER:
12 WK				WRIST:  FOREARM:  ELBOW:  SHOULDER:
24 WK				WRIST:  FOREARM:  ELBOW:  SHOULDER:

**MOBILISATION/PHYSIOTHERAPY:**

**COMPLICATIONS:**

**SECONDARY PROCEDURES:**

**FRACTURE UNION CLINICAL/RADIOLOGICAL:**

**REMARKS:**

**ANDERSON CRITERIA:**

<b>RATING</b>	<b>OUTCOME</b>
Excellent	Union with <10° loss of elbow or wrist flexion or extension and <25% loss of forearm rotation.
Satisfactory	Union with <20° loss of elbow or wrist flexion or extension and <50% loss of forearm rotation.
Unsatisfactory	Union with >30° loss of elbow or wrist flexion or extension and >50% loss of forearm rotation.
Failure	Malunion, nonunion, or unresolved chronic osteomyelitis.

## **ANNEXURE – II**

### **CONSENT FORM**

**TITLE OF RESEARCH: SURGICAL MANAGEMENT OF DIAPHYSEAL FRACTURES OF BOTH BONES OF FOREARM IN ADULTS BY DYNAMIC COMPRESSION PLATES- A CLINICAL STUDY.**

Principle Investigator : Dr PRASHANTH P SHAH

P.G. Guide name : Dr ASHOK NAYAK M.S (ORTHO)

All aspects of this consent form are explained to the patient in the language understood by him/her.

#### **I) Informed part**

##### **i. Purpose of study**

I have been informed that this study will test the effectiveness of one particular method of open reduction and internal fixation in diaphyseal fractures of both bones of forearm. This method requires hospitalization.

##### **ii. Procedure**

I will be selected for the treatment after the clinical study of my age, type of fracture, condition of bone seen in radiograph and after study of fitness for anaesthesia and surgery .I will be admitted immediately. I will have to attend follow-up to OPD regularly. I will be assessed in physiotherapy department also.

### **iii. Risk and Discomfort**

I understand that I may experience some pain and discomfort during the post operative period. This condition is usually expected. These are associated with the usual course of treatment.

### **iv. Benefits**

I understand that my participation in this study will have no direct benefit to me other than the potential benefit of treatment which is planned to heal my fracture in the shortest possible period and restore my function.

### **v. Alternatives**

I understand that, the various alternative modes of treatment available to me in this fracture pattern with their merits and demerits have been explained to me.

### **vi. Confidentiality**

I have been assured that all information furnished to the doctor by me regarding my medical condition will be kept confidential at all times and all circumstances except legal matters.

### **vii. Requires for more information**

It has been made clear to me that I am free at all time under any circumstances to touch based with doctor by directly approaching or otherwise to satisfy any query , doubt regarding any aspect of research concerns.

**viii. Refusal or withdrawal of participation**

It has been made clear to me that participation in this medical research is solely the matter of my will and also that right to withdraw from participation in due course research at any time.

**II CONSENT BY PATIENT**

I undersigned, \_\_\_\_\_ have been explained by Dr ASHOK NAYAK in the language understood by me. The purpose of research, the details or procedure that will be implemented on me. The possible risks and discomforts of surgery and anaesthesia have been understood by me. I have also been explained that participation in this medical research is solely the matter of my will and also that I have the right to withdraw from this participation at any time in due course of the medical research.

Signature of participant/patient                      date:                      time:

Signature of witness:                                      date:                      time:

## KEY TO MASTER CHART

BB	Both bones forearm
CS	Compartment Syndrome
D/3	Distal third
DOPOI	Duration of post op immobilization in weeks
DOF	Duration of follow up in months
DOU	Duration of union in weeks
E	Excellent
F	Female
FP	Fracture pattern
FOH	Fall on an outstretched hand
F/E	Flexion extension loss
I.P.No	In patient number
Lt	Left
L/3	Lower third
M	Male
M/3	Middle third
MOI	Mode of injury
M.T	Metatarsal
P/3	Proximal third
R	Radius
Rt	Right

ROM	Range of motion
RTA	Road traffic accident
S	Satisfactory
SF	Site of Fracture
S/P	Supination pronation loss
Sl. No	Serial number
S.Inf	Superficial Infection
T/So	Tranverse/Short oblique
U	Ulna
#	Fracture