

# Olecranon Process Fracture in a Radial Club Hand Treated with Tension Band Wiring: A Case Report

Ramanagouda Biradar<sup>1</sup>, Arravind Pillai<sup>1</sup>, Ullas Shetty<sup>1</sup>

## What to Learn from this Article?

Tension band principle works well for transverse olecranon fractures even in the absence of radius.

## Abstract

**Introduction:** Radial club hand is rare deformity, and many patients do not receive treatment due to lack of awareness. None of the treatment options available can restore normality. Fractures of the olecranon process in radial club hand are rare probably due to limited use of the limb.

**Case Report:** We report the case of a 35-year-old male with radial club hand who presented with a transverse fracture of the olecranon process. The patient underwent open reduction and tension band wiring for the fracture. At 6 months follow-up, the fracture had united and the patient had a complete functional recovery.

**Conclusion:** Tension band wiring is an excellent option for treating olecranon fractures in patients with radial club hand despite the deformity and the absence of radius.

**Keywords:** Olecranon process fracture, radial club hand, tension band wiring.

## Introduction

Radial club hand or radial dysplasia (RD) is a deficiency along the preaxial or radial side of the extremity. Although the etiology of RD is not clear, several theories have been postulated as the cause of the disease, like maternal drug exposure, compression of the uterus and vascular injury, but the newer theory attributes it to a defect in the apical ectodermal ridge (AER) [1]. Typical deformities include forearm shortening, radial deviation of the wrist, and hypoplasia of the thumb [2]. The patients may also present with fixed extension deformities or absence of active motions which can cause severe disabilities. Various procedures have been mentioned, but surgery is aimed at cosmetic and functional improvement [3]. The Ulna also

may be deformed or bowed in RD, worsening the deformity. Fractures of the ulna in RD are rare. There are no guidelines for the treatment of a deformed elbow and whether tension band wiring works in the absence of radius has not been studied. We present a case of RD of left limb who presented with a post-traumatic fracture of the olecranon process which was successfully managed with tension band wiring.

## Case Report

A 35-year-old male patient presented with pain of acute onset of the left elbow following a fall. Examination revealed a short and atrophied forearm with a single bone and tenderness over the olecranon process. All

Access this article online

Website:  
www.jocr.co.in

DOI:  
2250-0685.574

## Author's Photo Gallery



Dr. Arravind Pillai

<sup>1</sup>Department of Orthopaedics, BLDEU's, Shri B. M. Patil Medical College, Vijayapur, Karnataka, India.

### Address of Correspondence

Dr. Arravind Pillai,  
Department of Orthopaedics, Shri B. M. Patil Medical College, Vijayapur - 586 103, Karnataka, India.  
E-mail: pillai.arravind@gmail.com

Copyright © 2016 by Journal of Orthopaedic Case Reports

Journal of Orthopaedic Case Reports | pISSN 2250-0685 | eISSN 2321-3817 | Available on www.jocr.co.in | doi: 10.13107/jocr.2250-0685.574

This is an Open Access article distributed under the terms of the Creative Commons Attribution Non-Commercial License (<http://creativecommons.org/licenses/by-nc/3.0>) which permits unrestricted non-commercial use, distribution, and reproduction in any medium, provided the original work is properly cited.

movements at elbow and forearm were restricted. A provisional diagnosis of RD was made with a traumatic event. Plain radiography confirmed the diagnosis of RD with a displaced transverse olecranon fracture (Fig. 1). The limb was immobilized with an above elbow splint and following routine investigations and preanesthetic checkup, was posted for surgery under the regional block.

### Surgical procedure

The olecranon was approached posteriorly. The fracture was exposed and reduced with small reduction forceps. Using a 2 mm drill, a hole was drilled about 5 mm away from the posterior cortex of ulna, 2 cm distal to the fracture site. A 20 gauge cerclage wire was passed through the hole to leave segments on either side of the holes. Two 2 mm K-wires were passed from the olecranon directed toward the anterior cortex. The cerclage wire was passed beneath the triceps tendon and the K-wires and tightened in figure of eight configurations. The protruding ends of the K-wires were cut before sinking them into the bone. Hardware position and reduction were confirmed under an image intensifier, and fracture stability and movements were checked.

Postoperatively, the limb was splinted with the elbow in flexion for 1 week and physical therapy was started as tolerated by the patient. During the 6 months follow-up, range of movement at elbow was 20-130°, which was comparable to the normal side (Fig. 2 and 3).

### Discussion

Club hand deformities may be classified as Radial and Ulnar. Radial club hand is a more common with an incidence of 1:30,000-1:100,000 live births. 50% of cases are bilateral. About 40% of patients with unilateral club hand and 27% with bilateral club hand have associated with congenital anomalies involving cardiac, genitourinary, skeletal and hematopoietic system [2, 4]. The etiology of RD is unclear. Kumar and Sumar attributed the anomaly to a defect in AER [1]. They observed that removal of a portion of AER in chick embryos has produced anomalies which are similar to the radial club hand.

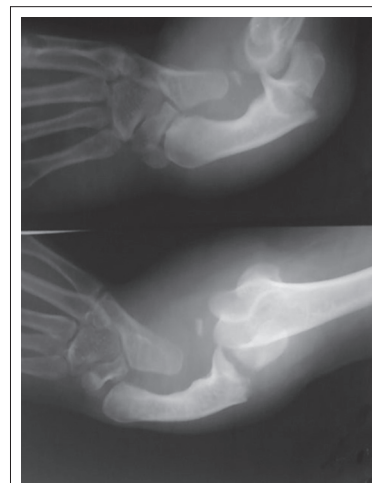Clinical presentation of radial club hand varies with the degree of radial deficiency and the presence of associated anomalies. Careful clinical examination is used to assess the degree of involvement. The deformity is usually noticed at birth. The neonate presents with a short forearm deviated radially with tight radial side soft tissue contractures. The thumb may be deficient to varying degrees. The fingers are stiff and elbow movements may also be restricted. In our case, the patient had a Type 3 RD, according to the classification of congenital RD is by Heikel [5] with partial absence of radius (Table 1). The function of the hand may be related to the amount of contractures, range of motion (ROM), and power of the upper limb. Patients with reduced ROM may use the whole limb to support or carry objects.

**Table 1: Classification of radial club hand according to Heikel.**

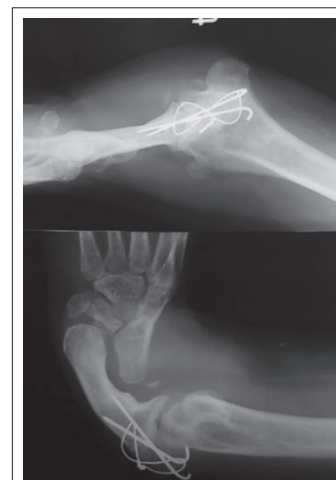Type 1	Mildest form with defective distal radial epiphysis
Type 2	Involves a limited growth of the radius on both its distal and proximal sides
Type 3	Absence of two-thirds of the radius, most commonly the distal side
Type 4	Complete absence of the radius along with a complete or a near complete absence of the thumb, which is the most common and most severe longitudinal deficiency

### Treatment options


Surgical therapy is performed around the age of one year in these children. Centralization remains the principal procedure to realign the carpus onto the distal ulna and is indicated in Types 2, 3, and 4 radial deficiencies.



**Figure 1:** Radiograph at the time of presentation.



**Figure 2:** Post-operative radiograph.



**Figure 3:** (a) Range of motion (ROM) at 6 months follow-up, (b) ROM at 6 months follow-up.

In resistant cases and those presenting late, stretching the soft tissue with distracter techniques using illizarov or mini external fixator may be required [6, 7]. In our case, the patient presented late and demanded treatment only for the fracture.

Tension band wiring was chosen as the treatment option after confirming with the patient about his functional range of movement before the fracture (20-130°), as the tension band wiring principle only exists during active extension in a range of 30-120° of flexion of the elbow [8]. Furthermore, postoperatively, we were able to attain full ROM which was comparable to the opposite side at 6 months follow-up. The tension band principle as applied to transverse olecranon fractures is based on the premise that distraction forces on the outer cortex of the ulna during elbow flexion are converted to compression forces on the articular surface of the olecranon at the fracture site. Hardware failure and secondary dislocations have been reported. Hardware failure was expected in this case due to the deformity and due to single bone articulating with the elbow, but we did not come

across these complications. In our case, tension band showed good results even when the bone in deformed and in the absence of the radius.

### Conclusion

Neglected cases of RD are high due to lack of awareness and financial constraints. Olecranon fracture in a neglected case of RD is rare and can be managed well with tension band wiring with a slight delay in exercise regimen.

### Clinical Message

Olecranon fractures in Radial club hand are not common. The deformity and absence of radius can increase the stress on the construct used for fixation during pronation and supination. Tension band wiring may be used in these cases with a good outcome.

### References

1. Kumar MK, Sumar SK. Radial club hand: A neglected case. *J Clin Diagn Res* 2011;5:1458-1460.
2. Salati SA, Rabah SM. Congenital isolated right radial club hand. *Libyan J Med* 2010;5.
3. Shariatzadeh H, Jafari D, Taheri H, Mazhar FN. Recurrence rate after radial club hand surgery in long term follow up. *J Res Med Sci* 2009;14(3):179-186.
4. Lourie GM, Lins RE. Radial longitudinal deficiency. A review and update. *Hand Clin* 1998;14(1):85-99.
5. Heikel HV. Aplasia and hypoplasia of the radius. *Acta Orthop Scand* 1988;39 Suppl:1.
6. Kessler I. Centralisation of the radial club hand by gradual distraction. *J Hand Surg Br* 1989;14(1):37-42.
7. Damore E, Kozin SH, Thoder JJ, Porter S. The recurrence of deformity after surgical centralization for radial clubhand. *J Hand Surg Am* 2000;25(4):745-751.
8. Brink PR, Windolf M, de Boer P, Brianza S, Braunstein V, Schwieger K. Tension band wiring of the olecranon: Is it really a dynamic principle of osteosynthesis? *Injury* 2013;44(4):518-522.

Conflict of Interest: Nil  
Source of Support: None

### How to Cite this Article

Biradar R, Pillai A, Shetty U. Olecranon Process Fracture in a Radial Club Hand Treated with Tension Band Wiring: A Case Report. *Journal of Orthopaedic Case Reports* 2016 Sep-Oct;6(4):66-68.