



International Journal of Orthopaedics Sciences

ISSN: 2395-1958
IJOS 2019; 5(1): 59-62
© 2019 IJOS
www.orthopaper.com
Received: 06-11-2018
Accepted: 10-12-2018

Dr. Vijaykumar Patil
B.L.D.E, Deemed to be
University, Shri B.M. Patil
Medical College and Research
Center, Vijayapura, Karnataka,
India

Dr. Santosh S Nandi
B.L.D.E, Deemed to be
University, Shri B.M. Patil
Medical College and Research
Center, Vijayapura, Karnataka,
India

Dr. Sandeep Naik
B.L.D.E, Deemed to be
University, Shri B.M. Patil
Medical College and Research
Center, Vijayapura, Karnataka,
India

Dr. Vinaykumar B
B.L.D.E, Deemed to be
University, Shri B.M. Patil
Medical College and Research
Center, Vijayapura, Karnataka,
India

Dr. Shreepad Kulkarni
B.L.D.E, Deemed to be
University, Shri B.M. Patil
Medical College and Research
Center, Vijayapura, Karnataka,
India

Dr. Rajesh K Patel
B.L.D.E, Deemed to be
University, Shri B.M. Patil
Medical College and Research
Center, Vijayapura, Karnataka,
India

Correspondence

Dr. Vijaykumar Patil
B.L.D.E, Deemed to be
University, Shri B.M. Patil
Medical College and Research
Center, Vijayapura, Karnataka,
India

Functional outcome of unstable comminuted intertrochanteric fractures in elderly treated with primary bipolar hemiarthroplasty

**Dr. Vijaykumar Patil, Dr. Santosh S Nandi, Dr. Sandeep Naik, Dr.
Vinaykumar B, Dr. Shreepad Kulkarni and Dr. Rajesh K Patel**

DOI: <https://doi.org/10.22271/ortho.2019.v5.i1b.13>

Abstract

Aims and Objectives: To study the functional outcome of unstable intertrochanteric fracture treated with bipolar cemented prosthesis and complications associated with it. Also to facilitate early mobilization, early weight bearing with rapid rehabilitation in elderly patient with unstable intertrochanteric fractures

Material and Methods: Prospective study of 31 cases presenting with unstable intertrochanteric fractures which satisfy inclusion and exclusion criteria admitted in shri B M Patil Medical College, Hospital, and Research center Vijayapura from year 2016- 2018 who are treated with Cemented Bipolar Prosthesis.

Results: In our study of 31 cases, there were 13 male and 18 female patients with mean age of 73.4 years. 84% of the cases admitted were due to trivial trauma, 16% due to RTA with left side being more common side affected. Mean duration of hospital stay was 11.03 days and mean time of full weight bearing was 3.97 days in our patients. One patient died on Postoperative day 5. 29% excellent, 32.3% good, 25% fair results obtained in our study according to Harris Hip Score.

Conclusion: Our study concludes that Cemented Bipolar Hemiarthroplasty in elderly patient with unstable intertrochanteric fracture reduces complications of prolonged immobilization, prolonged rehabilitation which are associated with internal fixation. Also reduces need for secondary surgery which required in cases of malunited fractures, non-union and implant failure. The procedure offered rapid mobilization, rapid return to pre injury level and improved quality of life.

Keywords: unstable intertrochanteric fractures, hemiarthroplasty, harris hip score

Introduction

Intertrochanteric fractures in elderly were a major cause of disability. Sedentary life and increased life span increased incidence of these fractures.

Trivial trauma in elderly is main cause for IT fracture where as high velocity trauma causes in younger patient.

Females are more prone to these fractures secondary to osteoporosis compared to males. "Approximately 15% to 20% of patients die within 1 year of fracture" [1, 2].

Unstability, osteoporosis and severe medical comorbidities in senile patient treatment is perilous. The spectra of treatment modalities starting from conservative to surgical intervention such as, advanced internal fixation have been employed since ages. But the problems remains an enigma unsolved till today. Before 1960 IT fractures treated conservatively, which resulted "As conservative methods resulted in advanced mortality rates and complications like decubitus ulcer, urinary tract infections, pneumonia, thromboembolic complications". "Intertrochanteric fractures with severe displacement and comminution are common in elderly patients. These patients have a poor bone quality and the fractures are often associated with complications such as nonunion, metal failure and femoral head perforation" [3, 4]. "The primary treatment goal is a stable fixation, early mobilization and immediate full-weight-bearing" [5]. Osteosynthesis gives good results in stable intertrochanteric fractures where as in unstable intertrochanteric fracture is challenging, with predictable good results, whereas the management of unstable intertrochanteric fractures is challenging, due to poor bone quality.

"The comminuted intertrochanteric fractures being in cancellous area, fixation of all fragments

is difficult.

The posteromedial void is generally present which makes the fracture very unstable” [6].

“Recent modality of fixation of these fractures is by 4th generation of intramedullary nails like the proximal femoral nails” [7] immobilisation is required even in this implants.

“Management of such cases with primary hemiarthroplasty permits early mobilization, thus avoiding most complications” [8] such patient are mobilised early.

Hemiarthroplasty has advantage of rapid return of function without pain.

“Hemiarthroplasty for intertrochanteric fractures has been described as early as 1973. Rosenfeld first introduced it by devising a prosthesis for head and neck replacement in trochanteric fractures, detailed the method of surgery and reported a good functional outcome. Studies have revealed that hemiarthroplasty in unstable IT fractures have given good results” [9, 10].

Methodology

Source of data

Data collected from patients presenting with unstable intertrochanteric fractures satisfying inclusion and exclusion criteria in B L D E University’s shri B.M. Patil Medical College and Research Center who are treated with Cemented

Bipolar Hemiarthroplasty.

Inclusion criteria

1. Patient with age group >60 years of either sexes who are able to walk before injury
2. Intertrochanteric fracture classified as unstable fracture according to Boyd and Griffin classification (type II, III, IV).

Exclusion Criteria

1. Polytrauma patients.
2. Patient <60 years of age.
3. Compound intertrochantric fractures.
4. Patients medically unfit for surgery.
5. Patients with immunocompromised status.

Results

Thirty one patients were enrolled in this study of them 26 sustained fractures after fall from a standing height, while 5 patients sustained road traffic accidents. The average age at surgery was 73.84 years (range, 65-90 years). There were 13 men and 18 women. The mean operative time was 100±10 minutes. There were two cases of superficial infection and one death.

Table 1: Functional results according to Harris hip score

Functional outcome	No. of Patients	%
Excellent	9	29.0
Fair	8	25.8
Good	10	32.3
Poor	3	9.7
Death	1	3.1
Total	31	100.0

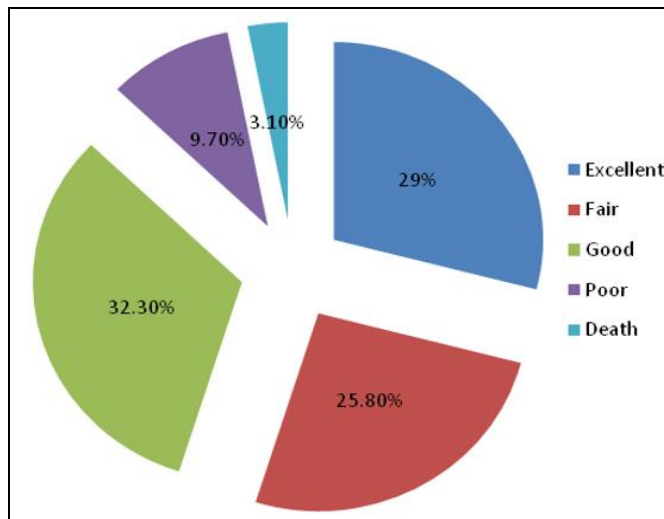


Fig 1: Functional Results According To Harris Hip Score

Discussion

The treatment of intertrochanteric fracture is still associated with some failures.

High stress concentration that is subject to multiple deforming forces and high incidence of complications reported after surgical treatment compels the surgeon to give a second thought regarding selection of proper implant. A large number of fixation implants has been devised and discarded. The treatment still merits the type of fracture and condition of the patient. Displaced, unstable, posteromedial comminuted intertrochanteric fracture in osteoporotic elderly patient is not

easy to treat.

Hemiarthroplasty has been used for unstable intertrochanteric fractures since 1971 [11] however less frequently as compared to femoral neck fractures [12]. Its initial use was as a salvage procedure for failed pinning or other complications [13]. Tronzo claimed to be the first to use long, straight-stemmed prosthesis for the primary treatment of intertrochanteric fractures [14]. Rosenfeld, Schwartz, and Alter reported good results with the use of the Leinbach prosthesis [15]. Since then there are multiple studies showing good results using this technique.

Bipolar Hemiarthroplasty having less complications than in unipolar implants like- loosening, dislocation, protrusion, and acetabular wear. Due to dual bearing surfaces in prosthesis good advantages such as sharing of the motion at the two surfaces and hence, it reduces the net wear at either surface, thus reducing erosion at the acetabular joint interface. In addition, the total range of motions at the joint is increased. In wide femoral canal Cemented fixation gives the implant good stability. an unstable intertrochanteric fractures, allowed early walking with full weight bearing and helped the patients to return to prefracture level of activity rapidly, preventing complications such as pressure sores, pneumonia, atelectasis and pseudoarthrosis”.

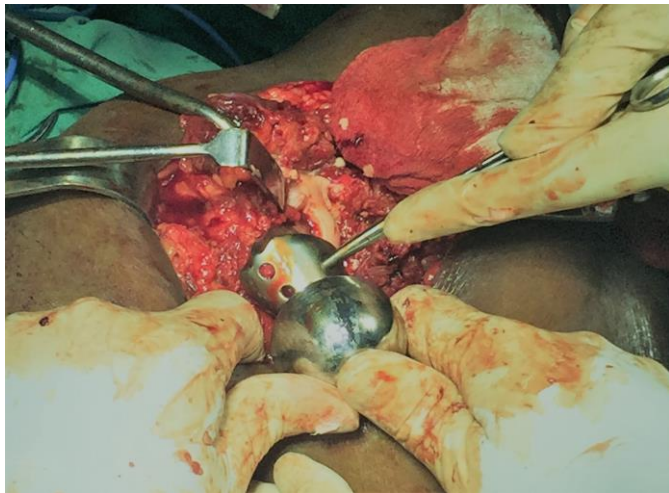

Fig 2: Intraop picture of Bipolar Prosthesis

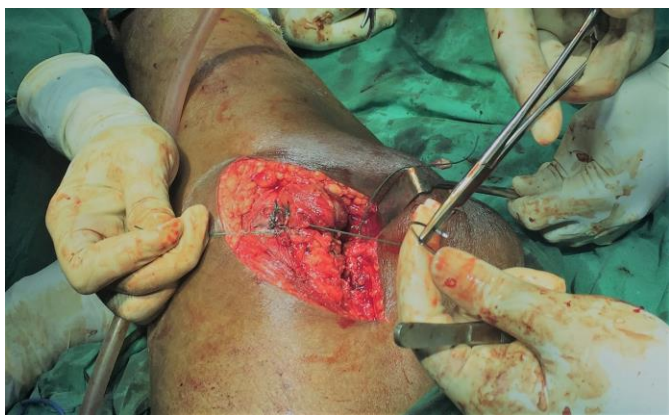

Fig 3: Greater Trochanter Reconstruction with Ethibond Sutures

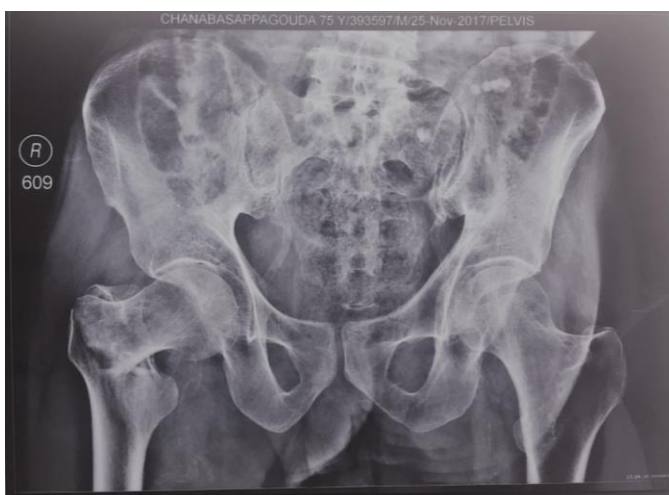

Fig 4: Pre-Operative 1

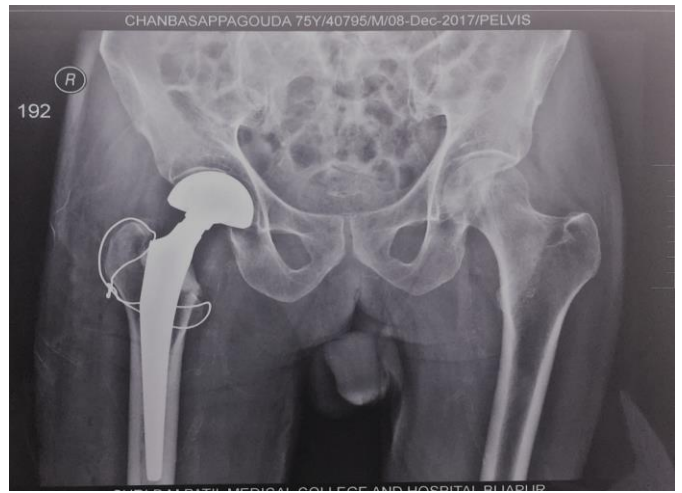

Fig 5: Post Operative 1

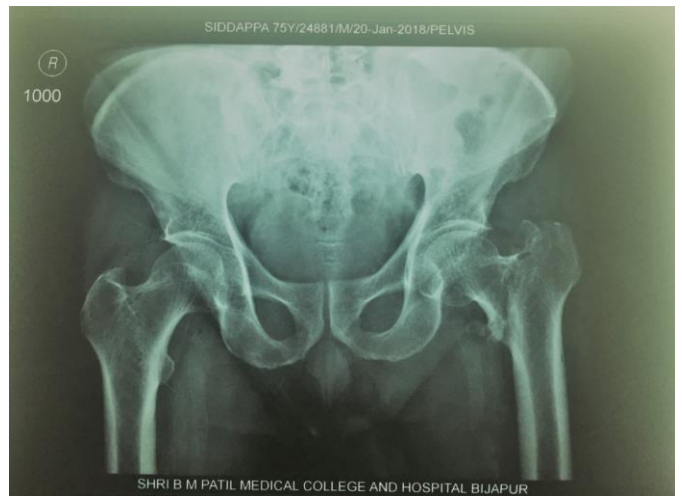

Fig 6: Pre-operative 2

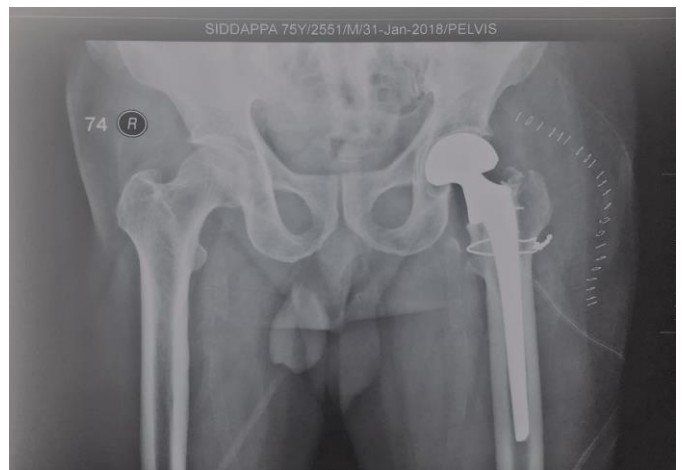

Fig 7: Post-Operative 2

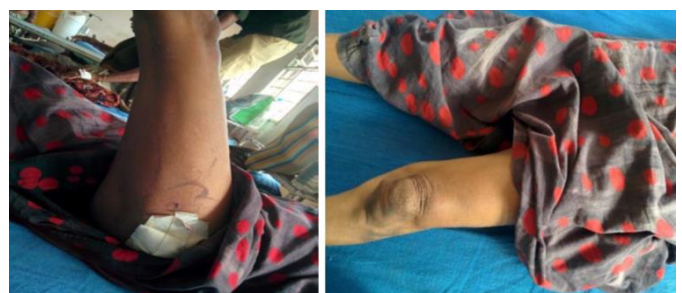

Fig 8: Flexion and Abduction on Post Op Day 3



Fig 9: Follow Up At 6 Weeks

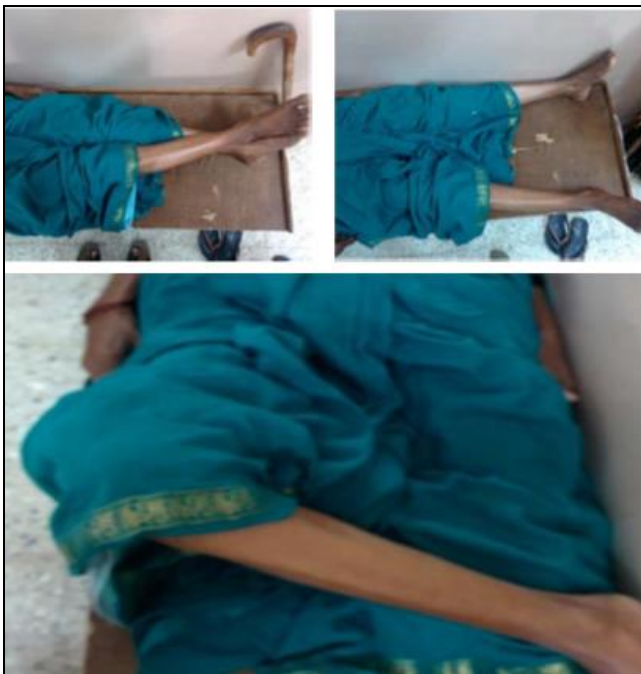

Fig 10: Movements at 6 Weeks of Follow Up

Conclusion

Intertrochanteric fractures of femur are very common among old age patients, females being more commonly affected. The most common mode of injury is domestic fall.

According to our results, we believe that Cemented Bipolar Hemiarthroplasty is of choice in freely mobile elderly patients above sixty years of age with an intertrochanteric femoral fracture.

In elderly patients with intertrochanteric fractures of the femur treated with hemiarthroplasty gave early mobilization, early return to pre injury level, superior the quality of life and gave a long term solution.

Postoperative early full weight bearing after Hemiarthroplasty avoids long-term immobilization, rehabilitation, deformities and need for revision surgeries.

References

1. Eiskjaer S, Otsgard SE, Jakobsen BW, Jensen J, Lucht U. Years of potential lost after hip fracture among postmenopausal women. *Actaorthop Scand.* 1992; 63(3):293-296.
2. Dahl E. Mortality and life expectancy after hip fractures. *Actaorthop Scand.* 1980; 51(1):163-170.
3. Haidukewych GJ, Israel TA, Berry DJ. Reverse obliquity fractures of the intertrochanteric region of the femur. *J Bone Joint Surg Am.* 2001; 83(5):643-50.
4. Kang SY, Lee EW, Kang KS *et al.* Mode of fixation failures of dynamic hip screw with TSP in the treatment of unstable proximal femur fracture: biomechanical analysis and a report of 3 cases. *J Korean Orthop Assoc.* 2006; 41(1):176- 80.
5. Koval KJ, Zuckerman JD. Hip fractures: II. Evaluation and treatment of intertrochanteric fractures. *J Am Acad Orthop Surg.* 1994; 2:150-56.
6. Grisso JA, Kelsey JI, Strom BL, and Chio GY. Risk factors for falls as a cause of hip fractures in women. *New England journal of medicine.* 1991; 324:1326-1331.
7. Meislin RJ, Zuckerman JD, Kummer FJ *et al.* A biomechanical evaluation of the gamma nail. *J Bone Joint Surg.* 1998; 70-A:239
8. Sturt green. Bipolar prosthetic replacement for the management of unstable intertrochanteric fractures in the elderly. *Clin Orthop Relat Res.* 1987; 224:169-177.
9. Haentjens P, Casteleyn P. Primary bipolar arthroplasty or total hip replacement for the treatment of comminuted intertrochanteric and sub trochanteric fractures in elderly patients. *Acta Orthop Belg.* 1994; 60:124-128.
10. Sancheti KH, Sancheti PK, Patil S, Dhariwal Q, Joshi R. Primary hemiarthroplasty for comminuted osteoporotic intertrochanteric fractures in the elderly: A retrospective case series. *Indian J Orthop.* 2010; 44(4):428-434
11. Stern MB, Angerman A. Comminuted intertrochanteric fractures treated with a Leinbach prosthesis. *Clin Orthop Relat Res.* 1987; 218:75-80.
12. Parker MJ, Handoll HH. Replacement arthroplasty versus internal fixation for extracapsular hip fractures. *Cochrane Database Syst Rev.* 2006; 2:CD000086.
13. Stern MB, Goldstein TB. The use of the Leinbach prosthesis in intertrochanteric fractures of the hip. *Clin Orthop Relat Res.* 1977; 128:325-31.
14. Harwin SF, Stern RE, Kulick RG. Primary Bateman-Leinbach Bipolar prosthetic replacement of the hip in the treatment of unstable intertrochanteric fractures in the elderly. *Orthopedics.* 1990; 13:1131-6.
15. Rosenfeld RT, Schwartz DR, Alter AH. Prosthetic replacements for trochanteric fractures of the femur. *J Bone Joint Surg Am.* 1973; 55:420.