

ORIGINAL ARTICLE

# Post-Operative Complications and Visual Outcome in Eye Camp Patients Undergoing Sutureless Cataract Surgery at a Base Hospital in Vijayapura District, South India

Sushma Hosamani, Vallabha K<sup>1</sup>, Vijaykumar Warad<sup>2</sup>

Department of Ophthalmology, Al-Ameen Medical College and Hospital, <sup>1</sup>Departments of Ophthalmology and Medicine, <sup>2</sup>Department of Medicine, Shri B. M. Patil Medical College, BLDE University, Vijayapura, Karnataka, India

## ABSTRACT

**Background:** Cataract is the principal cause of blindness in India, accounting for 62.6%. This problem can be tackled, and the backlog of cataract blind can be reduced by performing cataract operations on a large scale. Base hospital approach with screening camps has shown good visual outcome with lesser complications. **Aim and Objectives:** To study the profile of postoperative complications and visual outcome in eye camp patients undergoing cataract surgery at the base hospital. **Materials and Methods:** In this cross-sectional study, 413 patients were included following screening at community screening camps. Patients underwent sutureless small-incision cataract extraction with intraocular lens implantation under local anesthesia at the base hospital. Postoperative complications and visual outcome were recorded. **Results:** Immediate postoperative complications were corneal edema (9.44%), striate keratitis (6.77%), expected uveitis (5.56%), secondary glaucoma (2.66%), residual lens matter (2.66%), iris prolapsed (0.48%) and shallow anterior chamber (0.24%), hyphema (0.24%) and iris incarceration (0.24%). Endophthalmitis was reported in 0.48% (one grew citrobacter, rarely reported). Late complications included posterior capsular opacification (3.87%) noted and retinal detachment (0.48%) later. Majority 83.39% of the patients had postoperative best corrected visual acuity (BCVA) between 6/6 and 6/18, 13.42% had BCVA between 6/18 and 6/60, 3.19% had BCVA < 6/60 as at 6 months follow-up visit (overall percentage is 100%). **Conclusions:** The overall vision-threatening complications after cataract extraction in the base hospital are low. Our study reflects the efficacy of the base hospital approach, in terms of visual and surgical outcome, as an important aspect from the public health point of view, which can help in clearing the cataract backlog in developing countries like India.

**Keywords:** Cataract surgery, postoperative complication, postoperative visual outcome

## INTRODUCTION

Recent global estimates of visual impairment from the World Health Organization (WHO), reveal that 47.8%<sup>[1]</sup> of global blindness is due to cataract.<sup>[1]</sup> In South Asia region which includes India, 51% of blindness is due to

cataract.<sup>[1]</sup> A cataract is a significant and increasing global problem with vast economic and social implications.<sup>[2]</sup> It is the principal cause of blindness in India accounting for 62.6%.<sup>[3]</sup> It is projected that the number of about 20 million cataract blind as at 2002 will double by the year 2020.<sup>[4]</sup> High-volume surgery still has a role in reducing the cataract load in India.<sup>[5]</sup> By 2020, cataract surgical coverage in India is predicted to increase to 7.63

### Address for correspondence

Dr. Sushma Hosamani, Department of Ophthalmology, Al-Ameen Medical College and Hospital, Bijapur, Karnataka, India. E-mail: [drsushmaw@gmail.com](mailto:drsushmaw@gmail.com)

This is an open access article distributed under the terms of the Creative Commons Attribution-NonCommercial-ShareAlike 3.0 License, which allows others to remix, tweak, and build upon the work non-commercially, as long as the author is credited and the new creations are licensed under the identical terms.

For reprints contact: [reprints@medknow.com](mailto:reprints@medknow.com)

**How to cite this article:** Hosamani S, Vallabha K, Warad V. Post-operative complications and visual outcome in eye camp patients undergoing sutureless cataract surgery at a Base Hospital in Vijayapura District, South India. Niger J Ophthalmol 2015;23:16-21.

### Access this article online

#### Quick Response Code



#### Website:

[www.nigerianjournalofophthalmology.com](http://www.nigerianjournalofophthalmology.com)

#### DOI:

10.4103/0189-9171.164500

## Hosamani, *et al.*: Post-operative complication and visual outcome after sutureless cataract surgery

million/year.<sup>[1]</sup> This demonstrates significant progress in addressing surgical aspects; however, visual recovery after surgery is poor in about 25% of cases.<sup>[6]</sup> Various factors are implicated as outcomes varying according to community-based or hospital-based data, duration since surgery, conditions under which operations were conducted (excellent or less favorable), single or diverse surgeons. Therefore, this study seeks to determine the proportion of postoperative complications and effectiveness of base camps in terms of visual outcome following cataract surgery. It is only through an integrated approach that the challenge of creating widespread access to surgical services capable of delivering good quality visual rehabilitation will be met. The effective work of Aravind Eye Hospital System in South India, which is believed to be conducting nearly 7% of all eye surgeries performed in India and 2000 annual cataract surgeries exclusively free of cost at base hospitals is the testimony of this.<sup>[1]</sup> Base hospital approach is an important alternative to peripheral eye camps, and consists of screening of patients in screening camps, their transfer to the base hospital and subsequent surgery in the base hospital using permanent infrastructure already available. The advantages of base hospital approach stem from the utilization of optimal management for preoperative, operative and postoperative care for the patient.<sup>[7]</sup>

## MATERIALS AND METHODS

This cross-sectional study included cataract patients from peripheral screening camps and was conducted over a 19 months period from November 2011 to May 2013. All the patients who underwent cataract surgery were screened at various community-based screening camps (nine peripheral health center within 60 km from Vijayapur) and transferred to the base hospital. At the camps, torch light examination with loop and fundus, examination along with intraocular pressure (IOP) measurement, sac syringing, and urine sugar level testing was done, and a detailed history taken.

The inclusion criteria were senile mature, immature, and hypermature cataract while the exclusion criteria were traumatic cataract, cataract with diabetes mellitus, cataract with retinal diseases, congenital cataracts, complicated cataract, pseudoexfoliated cataract, and cataract with other ocular abnormalities. In addition, patients who could not complete the follow-ups visits or those requiring sutures were excluded.

During the study period, out of a total of 750 cataract patients who underwent screening and surgery at the base hospital, 413 patients met the inclusion criteria and were enrolled in the study and followed up for period of 6 months. Data regarding systemic/ocular illness,

previous ocular medications/surgery, long-term use of spectacles, and allergy to any drugs was recorded. Statistical analysis was done using percentage and graphical presentations.

At the base hospital, each patient was examined after taking a detailed history regarding their complaints. Preliminary examination of the eyes with torch light and loupe were done, and the eye with poorer vision was considered for eye surgery. Preoperative visual acuity was determined. Detailed slit lamp examination and fundus examination was done. IOP measurement was done using Schiottz tonometer, and sac syringing to test the patency of lacrimal passages was done in all cases. Keratometry readings were taken, A-scan for axial length and biometry was done to determine intraocular lens (IOL) power. Blood investigations such as total blood count, differential count, hemoglobin, and random blood glucose level were done in all cases. B-scan was done in all cases of mature cataracts where the fundus was not visualized.

Prophylactic topical antibiotic drops (ciprofloxacin eye drops) 4 hourly and a single dose oral antibiotic (tablet ciprofloxacin 500 mg) were given on the night preceding the surgical procedure. Most patients (97.1%) underwent small incision cataract surgery (SICS) either manual or phacoemulsification with posterior chamber intraocular lens (PCIOL) under operating microscope. Eight patients (2.6%) underwent SICS with anterior chamber (AC) IOL implantation, and one patient (0.3%) had SICS without implantation of the intraocular lens. Peribulbar anesthesia was given under strict aseptic conditions. The surgeries were performed by five different senior consultant ophthalmologists. Intraoperative complication if any and their management were noted. Subconjunctival dexamethasone and tobramycin administered at the end of the procedure. Average operating time was 10–15 min. Postoperatively all patients received oral antibiotics. Topical antibiotic steroid eye drops for 6 weeks in tapering dose along with flurbiprofen eye drops 8 hourly for 3 weeks. Follow-up visits were scheduled for the 1<sup>st</sup> day, 1<sup>st</sup> week, 6<sup>th</sup> week, 3<sup>rd</sup> month, and 6<sup>th</sup> month postoperatively. At every visit, slit lamp examination, IOP measurement using Perkins tonometer, and fundus finding were recorded, in addition to visual acuity and refraction. The study was approved by the Institute Review Board and the Ethics Committee of Shri B. M. Patil Medical College and Research Centre, and informed consent was obtained from all patients for all procedures performed.

Presenting vision was graded (based on the WHO recommendations for acceptable outcomes) after

Hosamani, *et al.*: Post-operative complication and visual outcome after sutureless cataract surgery

cataract surgery into good if it was 6/18 or better, borderline if <6/18–6/60, and poor outcome if <6/60, using Snellen visual acuity charts.

**RESULTS**

A total of 413 eyes of 413 patients who were screened at community-based screening camps and underwent cataract surgery were included in this study. Two hundred and sixty (63%) patients had a unilateral cataract, and 153 (37%) had bilateral cataracts. Figure 1 shows the age distribution of the patients. There were 282 female (68.37%) and 131 male (31.63%) patients.

Figures 2 and 3 present the type of cataract and distribution of immature cataract respectively. Preoperative visual acuity was counting fingers at < 3 m in 96.17%, 6/60 in 3.19%, and 6/36 in 0.64% of the patients.

Intraoperative complications were seen in 6.05% cases. Posterior capsule rupture without vitreous leak occurred in 2.42%, posterior capsule rupture with vitreous leak occurred in 1.21%. Other intraoperative complications were Descemet’s membrane detachment (0.72%), iridodialysis, premature entry, and iris tear in 0.48% cases.

The most frequently occurring complication during the immediate postoperative period in descending order was corneal edema (9.44%), striate keratitis (6.77%), uveitis (5.56%), secondary glaucoma and residual lens

matter (2.66%), iris prolapse (0.48%), shallow AC, hyphema and iris incarceration (0.24% each). There were two cases of endophthalmitis (0.48%). One was sterile, and the vitreous sample from another patient grew citrobacter (*Enterobacter amnigenus* biogroup II), a Gram-negative bacillus.

Postoperative complications at the end of 1<sup>st</sup> week included persistent uveitis (2.90%), corneal edema (2.42%), striate keratitis (1.45%), secondary glaucoma (1.21%) and one case each (0.24%) of displaced IOL, and optic capture. The most common late postoperative complication was posterior capsule opacification (3.87%) and the least common was cystoid macular edema and optic capture (0.24%) at the end of 6<sup>th</sup> week. Posterior capsular opacification was present in 3.87% at the end of 3<sup>rd</sup> month. Retinal detachment was noted in 0.48% at later follow-up visits.

Of the total patients included in the current study, 83.39% patients had best corrected visual acuity (BCVA) between 6/6 and 6/18, 13.42% had BCVA, between 6/18 and 6/60, 3.19% had BCVA <6/60, as at 6 months follow-up visit. Astigmatism (ATR) was present in the majority of patients and distribution is shown in Figure 4. With the rule, ATR occurred in 4.79% and against the rule ATR occurred in 68.05%.

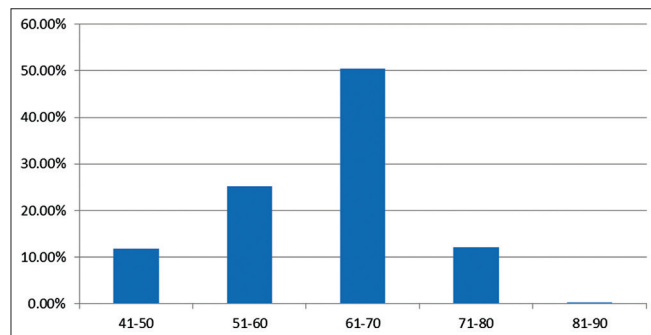


Figure 1: Age distribution

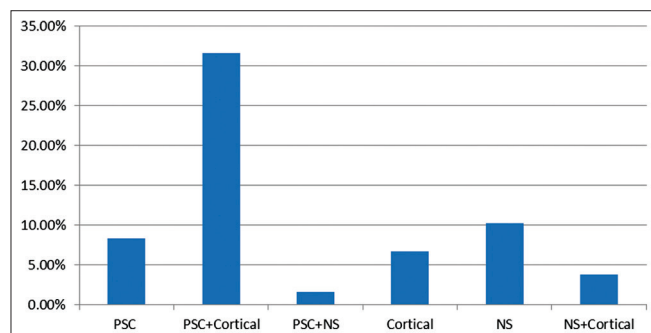


Figure 3: Distribution of type of immature cataract

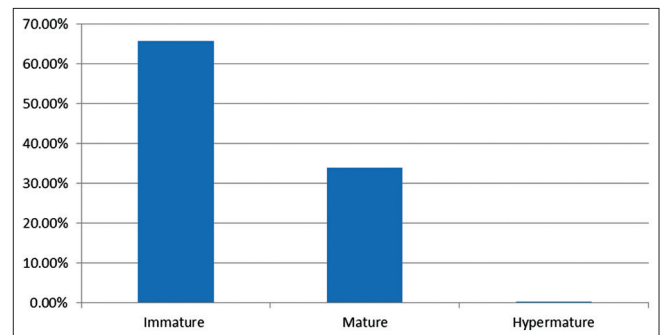


Figure 2: Type of cataract

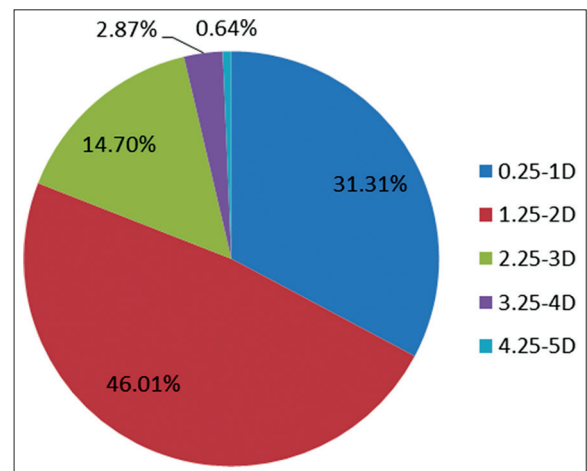


Figure 4: Postoperative astigmatism at end of 6 weeks

Table 1 shows the relation between intraoperative complications and BCVA. Most postoperative complications occurred in the patients in the age group between 61 and 70 years of age [Table 2]. Most postoperative complications were present in the combined type of immature cataract and mature type, followed by nuclear type. The causes of poor visual outcome pertaining to the anterior segment were two cases each of descemet's membrane detachment, aphakia, and posterior capsular opacification. There was one case each of displaced IOL and corneal opacity. Causes pertaining to the posterior segment were two cases of retinal detachment. Causes of poor outcome unrelated to cataract surgery were two cases of dry age-related macular degeneration (ARMD), one case each of optic atrophy, old choroidal neovascular membrane, and posterior staphyloma.

**Table 1: Distribution of BCVA to the intraoperative complications**

Intra-operative complications (total 27 cases)	Visual acuity		
	6/6-6/18	<6/18-6/60	<6/60
PCR	7	4	-
PCR+VL	2	-	3
Tunnel problem	1	2	-
Iris tear	2	-	-
Iridodialysis	2	-	1
DMD	1	-	2
Total	15	6	6

PCR: Posterior capsule rupture, PCR+VL: Posterior capsule rupture with vitreous leak, DMD: Descemet's membrane detachment

**Table 2: Distribution of postoperative complication and age**

Postoperative complications (131 cases)	Age (years) of the patient				
	41-50	51-60	61-70	71-80	>80
Corneal edema	2	9	24	5	-
Striate keratitis	-	3	19	3	-
Iritis	-	6	8	2	-
Secondary glaucoma	-	1	7	2	-
Residual cortex	-	2	5	2	-
Uveitis	-	2	1	-	-
Iris prolapse	-	-	4	-	-
Shallow AC	-	-	-	1	-
Hyphema	-	1	-	-	-
Endophthalmitis	1	-	1	-	-
Iris incarceration	-	-	-	-	-
Persistent iritis	-	-	-	-	-
Persistent uveitis	-	-	2	1	-
Displaced IOL	-	1	1	-	-
Optic capture	-	-	2	-	-
PCO	-	2	7	1	-
CME	-	-	1	-	-
RD	-	1	1	-	-
Total	3	28	83	17	0

AC: Anterior chamber, IOL: Intraocular lens, PCO: Posterior capsule opacification, CME: Cystoid macular edema, RD: Retinal detachment

## DISCUSSION

Recent studies demonstrate significant progress in addressing surgical aspects of the cataract backlog; however, visual recovery after surgery is poor in about 25% of cases.<sup>[8-10]</sup> The majority of the rural population is unable to access specialist care due to illiteracy, poor socioeconomic status, and lack of surgical facilities. Favorable results have been reported after camp based IOL implantation for age-related cataract<sup>[5]</sup> and this study highlights quality of vision, and early rehabilitation as two of the critical parameters that determine the success of modern cataract surgery with low intraoperative and postoperative complications in base hospitals in South India. Final corrected visual acuity is much better in the base hospital as compared to peripheral eye camps, and this affects the final visual outcome, with better and earlier visual rehabilitation.<sup>[11]</sup> One major drawback with surgeries at the base hospital is a higher loss of follow-ups compared to peripheral camps.<sup>[11]</sup>

On the other hand in base hospitals, all difficult cases are operated upon<sup>[11]</sup> while this does not happen in peripheral camps. However, complications are found in both settings.<sup>[11]</sup> Therefore, hospital base camps appear to be better than the peripheral camps in terms of outcome and quality of surgery. Venkatesh *et al.*<sup>[5]</sup> in 2003 reported an incidence of 1.9% of intraoperative complications which is comparable to our study. The incidence of posterior capsule rupture without vitreous leak was the most common intraoperative complication, and this is comparable to other series (1.0–4.3%).<sup>[6,7,12,13]</sup> Posterior capsule rupture occurred most commonly during nucleus delivery and irrigation aspiration. In the hospital-based study of 898 patients, Natchiar *et al.*<sup>[14]</sup> reported a similar incidence comparable to our study. Most postoperative complications were in the age group between 61 and 70 years of age; this could have been related to cataract prevalence in this pattern age group.

The most common immediate postoperative complication was primary corneal edema 9.44%, but majority resolved within the 1<sup>st</sup> week. A clinical trial in Pune had nine (4.5%) cases of postoperative corneal edema on the 1<sup>st</sup> day in the phaco arm, and four (2%) cases in the MSICS arm.<sup>[15]</sup> Striate keratitis (6.77%) was the second most common complication during the early postoperative day. Sudhakar *et al.*<sup>[16]</sup> in their study found a similar incidence (7.3%) of striate keratitis. In the various series of cataract surgeries conducted in rural camps by Anand *et al.*<sup>[6]</sup> and Verma *et al.*<sup>[13]</sup> Corneal edema constituted the major complication accounting for 23.3% and 43% respectively. Sudhakar *et al.*<sup>[16]</sup> and Venkatesh *et al.*<sup>[5]</sup> reported an incidence of 1.7% and



### Hosamani, *et al.*: Post-operative complication and visual outcome after sutureless cataract surgery

1.5% respectively. Hennig *et al.*<sup>[4]</sup> reported an incidence of 0.4% in their study. Postoperative uveitis was seen in 5.56%, which was mild in 3.96% and moderate in 1.60%. Sudhakar *et al.*,<sup>[16]</sup> Kratz *et al.*<sup>[17]</sup> and Venkatesh *et al.*<sup>[5]</sup> reported an incidence of 4.8%, 3.3%, and 1.5% respectively. Residual cortex was seen in 2.66% cases. Though this was higher than obtained by Venkatesh *et al.*<sup>[5]</sup> (0.2%), it did not have an effect on the final visual outcome, and none of the cases required resurgery. Iris prolapse was noted in two (0.48%) cases. Iris abscission with suturing was done in both of these cases. The incidence of iris prolapse was 1.3% and 0.5% in the various studies by Chitkara *et al.*<sup>[18]</sup> and Balmer *et al.*<sup>[19]</sup> Endophthalmitis occurred in 0.48% (two cases). One was sterile, and the vitreous sample from another patient grew citrobacter (*Enterobacter amnigenus* biogroup II), a Gram-negative bacillus which, to the best of our knowledge, has rarely been reported in the eye. *Pseudomonas* is the most common Gram-negative causative organism.<sup>[20,21]</sup> Postsurgical or posttraumatic infection with *Enterobacter cloacae* or *Enterobacter aerogenes* has been reported, mostly with dismal results.<sup>[22-24]</sup> A higher incidence was reported by Anand<sup>[6]</sup> (1.4%) and Verma *et al.*<sup>[13]</sup> (4.3%) in surgeries conducted in rural camps.

Shallow AC was noted in 0.24% of cases. Shallow AC was secondary to wound leak. AC was reformed, and suturing was done. Ravindra *et al.*<sup>[8]</sup> reported an incidence of 0.4% of wound gape. This is comparable with our study. The other complications included hyphema (0.24%) which got cleared in 1-week with oral and topical steroids. Venkatesh *et al.*<sup>[5]</sup> reported an incidence of 0.2% of hyphema. Iris incarceration was present in 0.24%, which was managed with pilocarpine eye drops and did not affect the final visual outcome. At the end of 1<sup>st</sup> week, corneal edema was present in 2.42% cases, persistent uveitis was seen in 2.90%. Secondary glaucoma was present in 1.45%. One case each (0.24%) was displaced IOL, optic capture, and residual cortex was noted. At the end of 6 weeks, fibrous type of posterior capsule opacification was seen in 3.87% cases. Incidence was less as the follow-up was for 6 months only. Sudhakar *et al.*<sup>[16]</sup> reported a higher incidence (11.5%). One case of cystoid macular edema and optic capture (0.24%) were noted. A similar incidence of pseudophakic cystoid macular edema (0.3%) was reported by Sudhakar *et al.*<sup>[16]</sup> At the end of 6<sup>th</sup> month, two cases (0.48%) were noted to have retinal detachment.

BCVA at the end of 6 months was 6/18 or better in 83.39%, <6/18–6/60 in 13.42%, and <6/60 in 3.19% patients. Venkatesh *et al.*<sup>[5]</sup> in 2002 in their study achieved BCVA of 6/18 or better in 94.4%, Ravindra *et al.*<sup>[8]</sup> in 1994 reported a BCVA of 6/18 or better in 80.7%, Hennig *et al.*<sup>[4]</sup> in

his study reported a BCVA of 6/18 or better in 96.2%. Ravindra *et al.*<sup>[8]</sup> in their comparative studies between camps and hospitals reported that good visual outcome (6/18 or better) was higher in hospitals than in camps. Cataract and ARMD may coexist, in which case the presence of macular disease may limit the final visual result after cataract surgery.<sup>[25]</sup>

## CONCLUSIONS

The overall vision-threatening complications after cataract extraction in the base hospital are very low with a good visual outcome. Our study reflects the efficacy and the outcome of hospital base eye camps in terms of visual outcome and postsurgical complications, as an important aspect from the diagnostic, therapeutic, and public health point of view.

## Financial support and sponsorship

Nil.

## Conflicts of interest

There are no conflicts of interest.

## REFERENCES

1. GVS Murthy, Gupta Sanjeev K. Current status of cataract blindness and Vision 2020: The right to sight initiative in India. *Indian J Ophthalmol* 2008;56:6:489-94.
2. Garry Brian, Hugh Taylor. Cataract blindness – challenges for the 21<sup>st</sup> Century. *Bulletin of the World Health Organization* 2001;79:249-56.
3. Park K, Park's Textbook of Preventive and Social Medicine, 18<sup>th</sup> ed. Banarasidas Bhanot, Jabalpur 2005:319-23.
4. Hennig A, Kumar J, Singh AK, Ansari A, Singh S, Gurung R, *et al.* World Sight Day and Cataract Blindness. *Br J Ophthalmol* 2002;86:830-31.
5. Venkatesh R, Muralikrishnan R, Balent LC, Prakash SK, Prajna NV. Outcomes of high volume cataract surgeries in a developing country. *Br J Ophthalmol* 2005;89:1079-83.
6. Anand R, Gupta A, Ram J, Singh U, Kumar R, Visual outcome following cataract surgery in visual Punjab. *Indian J Ophthalmol* 2000;48:153-58.
7. Khosla PK. *Community Ophthalmology: An Indian Perspective—Current Scientific Literature*. New Delhi 1992:113-16.
8. Ravindra MS, Rekha G. Rural eye camp versus Base Hospital Camp. *Indian Ophthalmology* 1996;303-04.
9. Stark WJ, Worthen DM, Holladay JR *et al.* The FDA report on intraocular lenses. *Ophthalmology* 1983;90:311-17.
10. McDonnell PJ, Zarbin MA, Green WR. Posterior capsule opacification in pseudophakic eyes. *Ophthalmology* 1983;90:1548-53.
11. Gogate P, Kulkarni A. Comparison of cataract surgery in a base hospital and in peripheral eye camps. *Community eye health* 2002; 15: 26-27.
12. Sugar HS: Prognosis in stripping of Descemet's membrane in cataract extraction, *Am J Ophthalmol* 1967;63:140-43.
13. Verma L, Gupta SK, Murthi GVS, Goyal M, Pant TD. A follow up study on visual outcome after camp based intracapsular cataract extraction. *J. Tropical Med and Int. Health* 1996;1:342-47.
14. Natchiar G, Robin AL, Nalgirkar AR, Krishnadas R. Posterior capsule tears during extracapsular cataract surgery in India. *Arch. Ophthalmol* 1993;111:706-8.

Hosamani, *et al.*: Post-operative complication and visual outcome after sutureless cataract surgery

15. Gogate PM, Kulkarni SR, Krishnaiah S, Deshpande RD, Joshi SA, Palimkar A, *et al.* Safety and efficacy of phacoemulsification compared with manual small incision cataract surgery by a randomized controlled clinical trial: Six weeks results. *Ophthalmology* 2005;112:869–74.
16. Sudhakar J, Ravindra RD, Natchiar G. Analysis of complication in 1000 cases of posterior chamber intraocular lens implantation. *Indian J. Ophthalmol* 1989;37:78-9.
17. Kratz RP, Mazzacco TR, Davidson B *et al.* The shearing intraocular lens: A report of 100 cases. *J. Am. Intraocular Implant Soc* 1981;7: 55.
18. Chitkara DK, Smerdon DL. Risk factors, complications and results in extracapsular cataract extraction. *J. Cataract Refract Surg* 1997;23: 570-4.
19. Balmer A, Andenmatten R, Hiroz CA. Complications of cataract surgery: Retrospective study of 1304 cases. *Klin-Monstbl-Augeneheilkd* 1991;198:344-6.
20. Kunitomo DY, Das T, Sharma S, Jalali S, Majji AB, Gopinathan U, *et al.* Microbiologic spectrum and susceptibility of isolates: Part I. Postoperative endophthalmitis. Endophthalmitis Research Group. *Am J Ophthalmol* 1999;128:240-2.
21. Irvine WD, Flynn HW Jr, Miller D, Pflugfelder SC. Endophthalmitis caused by gram negative organisms. *Arch Ophthalmol* 1992;110:1450-4.
22. Okhravi N, Ficker L, Matheson MM, Lightman S. Enterobacter cloacae Endophthalmitis: Report of Four Cases. *J Clin Microbiol* 1998;36:48-51.
23. Mirza GE, Karakucuk S, Doganay M, Caglayangil A. Postoperative endophthalmitis caused by an Enterobacter species. *J Hosp Infect* 1994;26:167-72.
24. Milewski SA, Klevjer-Anderson P. Endophthalmitis caused by Enterobacter cloacae. *Ann Ophthalmol* 1993;25:309-11.
25. Minassian DC, Reidy A, Desai P. The deficit in cataract surgery in England and Wales and the escalating problem of visual impairment: epidemiological modelling of the population dynamics of cataract. *Br J Ophthalmol* 2000; 84:4–8.