



Case Report

## ADENOCARCINOMA OF LUNG PRESENTING AS PATHOLOGICAL FRACTURE

Mahesh Kumar U<sup>1</sup>, Yelikar B R<sup>1\*</sup>, Savita Shetter<sup>1</sup> and Pankaj Pande<sup>1</sup>

\*Corresponding Author: **Yelikar B R**, ✉ [bldepathology@yahoo.com](mailto:bldepathology@yahoo.com)

The aim of the article is to present a case of pathological fracture which on evaluation by histopathology and immunohistochemistry was due to adenocarcinoma of lung. The skeletal system is the third most common site to be involved by metastatic tumor after the lungs and liver. By far the most common location for osseous metastases is the axial skeleton, followed by proximal femur and proximal humerus. Fractures after a minor or insignificant injury should always raise the suspicion of an underlying lesion. Since patients with more aggressive tumor types (lung) have a much shorter life expectancy than those with less aggressive types (prostate), early diagnosis and treatment is essential.

**Keywords:** Adenocarcinoma of lung, Immunohistochemistry, Pathological fracture

### INTRODUCTION

The skeletal system is the third most common site to be involved by a metastatic tumour after the lungs and liver. The development of bone metastasis is common in many cancers, occurring in virtually all patients with multiple myeloma, in 65%-75% of patients with advanced breast and prostate cancers, and in 30%-40% of patients with lung cancer (Torbert and Veillette, 2008). Metastasis to bone leads to severe skeletal complications like pathologic fracture, spinal cord compression, and hypercalcemia (Lipton, 2004) Fractures after a trivial trauma should always

raise the suspicion of metastasis to bone (Henry, 2009).

### CASE PRESENTATION

A 67-years old elderly male patient presented with pathological fracture of right femur with a minor injury. On evaluation patient is a smoker since last 40 years. He had on and off symptoms of fever, cough and respiratory dysfunction since last one year.

**Previous Investigations:** Chest X-ray reports were inconclusive. FNAC of cervical lymph node was suggestive of granulomatous inflammation.

<sup>1</sup> Department of Pathology, BLDE University, Shri BM Patil Medical College, Bijapur, Karnataka.

In Indian setup, tuberculosis is the commonest cause of granulomatous inflammation with typical clinical features of on and off fever and cough. So, he was treated for tuberculosis.

**Recent Investigations:** Chest X-ray revealed a mass in the right lower lobe of lung. PSA levels were within normal limits. Sputum examination was positive for malignant cells.

**On examination:** Patient had swelling and pain in the right sub- and inter-trochanteric regions of femur since one and half month. CT scan of femur showed pathological fracture with osteolytic cortical destruction.

Hemiarthroplasty with Austin Moore prosthesis was done and bone tissue was sent for histopathological examination.

Laboratory investigations (complete blood count, tumour markers – Carcinoembryonic

antigen, Prostate specific antigen, Alpha fetal protein) were within normal limits.

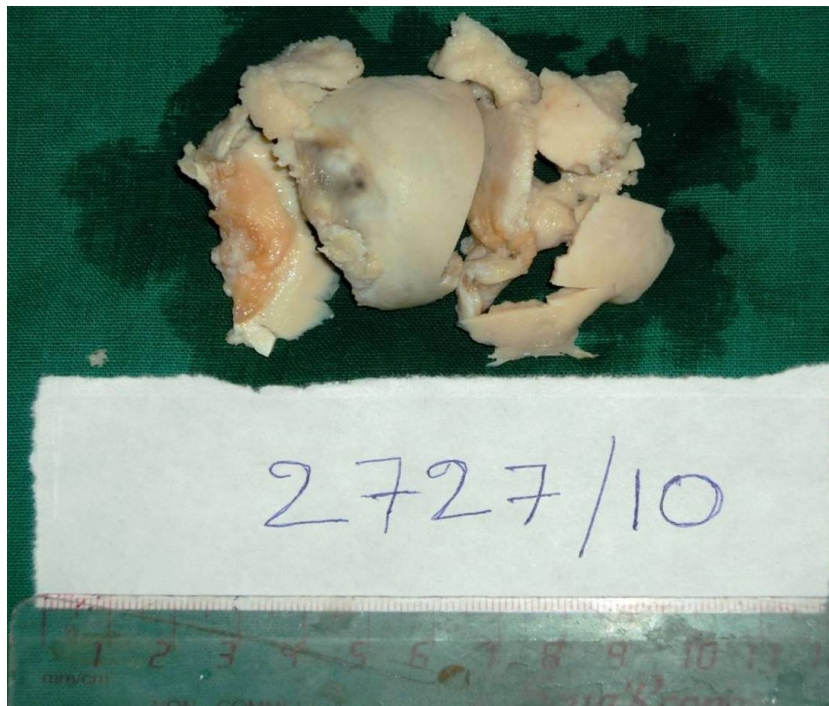## **PATHOLOGY**

**Gross:** We received head of femur measuring 4.5 x 4 x 2 cm with a fracture, which was friable (Figure 1).

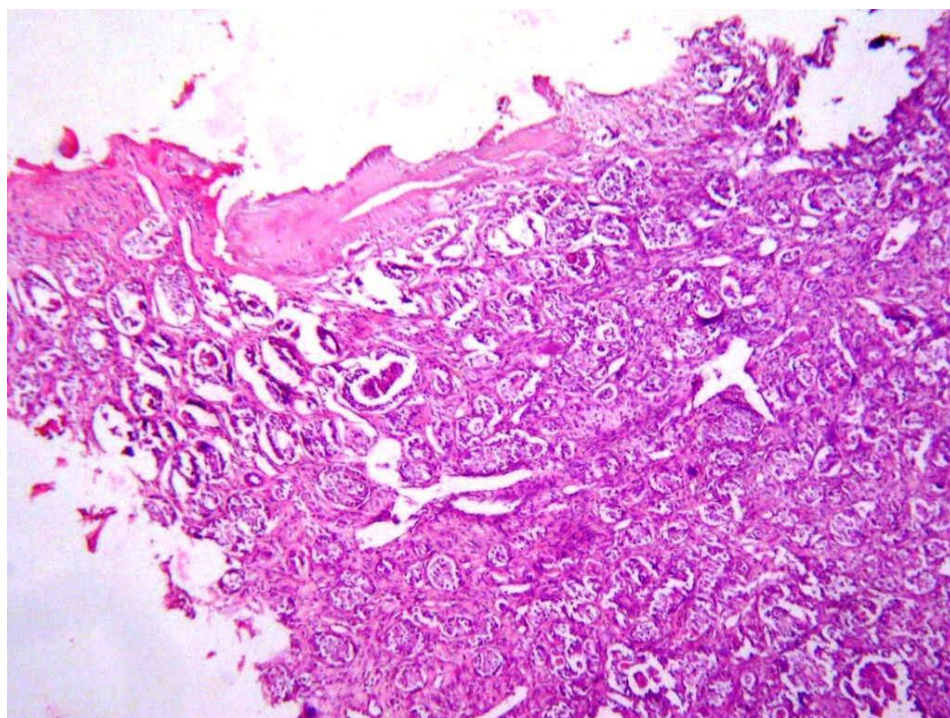
### **Microscopy**

Microscopy showed tumor tissue composed of tumour cells arranged in acinar pattern, tubular glands and singly scattered around the bony trabaculae (Figures 2 and 3). Individual tumor cells were large, pleomorphic, having high N: C ratio, hyperchromatic nuclei with prominent nucleoli and scant to moderate eosinophilic cytoplasm. Areas of hemorrhage and necrosis were noted with mixed inflammatory cell infiltrate.

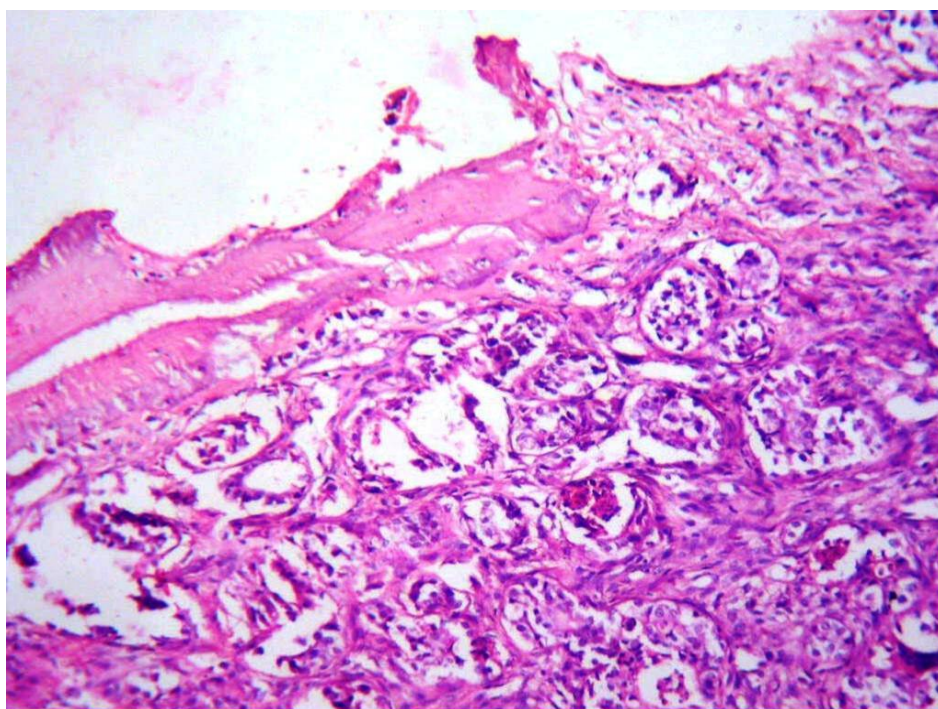
**Figure 1: Head of Femur Showing Pathological Fracture**



**Figure 2: Tumor Cells Arranged in Acinar Pattern (H&E, 10X)**



**Figure 3: Tumor Cells in Vicinity of Bony Trabaculae (H&E, 40X)**





**Immunohistochemistry (IHC):** Showed positivity for CK7 (Figure 4) while CK 20 was negative.

Based on clinical features, chest x-ray findings, histopathological findings and immuno histo chemical analysis, a diagnosis of metastatic adenocarcinoma of femur, primary from the lung was made.

## DISCUSSION

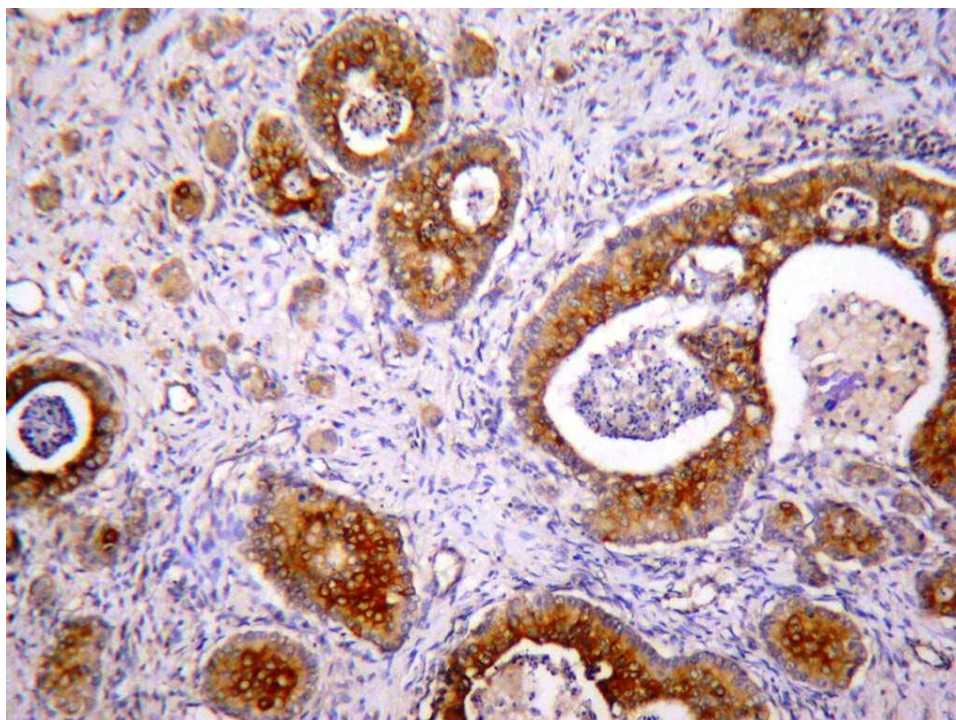
By far the most common location for osseous metastases is the axial skeleton, followed by the proximal femur and proximal humerus. Metastases from lung, renal, and thyroid tumors tend to be entirely lytic and our case also showed a lytic lesion. The majority of prostatic and breast bone metastases are blastic though lytic lesions do occur (Torbert and Veillette, 2008).

The laboratory workup should be done in a patient with bone metastases, if the primary

tumor has not already been diagnosed. A complete blood count (CBC) with a differential is important when working up any suspected malignancy. Elevated erythrocyte sedimentation rates (ESR) and c-reactive protein (CRP) levels signal that an inflammatory process is involved, but cannot consistently differentiate an infectious process from a malignancy (Torbert and Veillette, 2008).

Carcinoembryonic antigen (CEA) is a marker of adenocarcinomas such as colonic, rectal, pancreatic, gastric, and breast. Prostate specific antigen (PSA) levels can help diagnose prostate cancer. A thyroid panel can help eliminate the suspicion of a rare thyroid primary. Lactate dehydrogenase (LDH) isoenzymes 2 and 3 can suggest a diagnosis of lymphoma. To evaluate for liver cancer, alpha fetal protein (AFP) levels are often obtained in patients with hepatitis C or

**Figure 4: IHC Showing CK 7 Positivity (40X)**



those that are heavy drinkers (Torbert and Veillette, 2008).

A chemistry panel can be used to assess kidney function and allows calcium and phosphate levels to be followed to detect and avoid the development of malignant hypercalcemia. Urinary N-telopeptides serve as an indicator for bone collagen breakdown, which parallels tumor burden, and can provide a baseline to evaluate treatment progress (Torbert and Veillette, 2008).

High quality, plain radiographs (anteroposterior and lateral views) that shows the involved bone including one joint proximal and distal are the standard for initial assessment of metastatic bone disease. Pelvic radiographs should include an anteroposterior view and Judet (obturator and iliac oblique) views of the pelvis. A significant amount of bone must be destroyed before a lesion will appear lytic on radiographs. Therefore, a patient with a malignancy and bone pain often requires further evaluation despite normal appearing plain radiographs (Torbert and Veillette, 2008).

Adenocarcinoma of lung is a malignant epithelial tumor with glandular differentiation or mucin production by the tumor cells, and is the most common type of lung cancer in women and non-smoker's cancers (Kumar *et al.*, 2010). Patients with more aggressive tumor types (lung) succumb have a much shorter life expectancy than those with less aggressive types (prostate) (Torbert and Veillette, 2008).

Recently, Chhieng *et al.* (2007) described that an adenocarcinoma was likely a primary lung tumor when it was of the CK7 positive/CK20 negative and TTF-1 positive phenotype (Naka N *et al.*, 2007).

The goals of surgery for impending or pathologic fracture are to provide pain relief and a stable, durable construct that will allow the patient to ambulate shortly after surgery and will last for the life of the patient. Given the frequent large amount of bone loss, the degree of osteoporosis in the elderly, and the decreased ability of bone to heal at the tumor site, this is often quite a challenge. Thus the techniques used in these patients differ from those used in young trauma patients in which fixation is placed as a temporary stabilizing measure while fracture healing occurs. The idea in the fixation of metastatic pathologic fractures is to reinforce or replace the compromised bone with a rigid and durable construct. This typically requires plates or intramedullary rods with the addition of bone cement to fill the bone defects. If the fracture is near a joint, and stable and durable fixation cannot be achieved by the described methods, joint arthroplasty may provide a more durable construct and may require less operative time and blood loss (Torbert and Veillette, 2008).

Patients with pathologic fracture of a weight bearing limb should be treated surgically because of severe pain, gait disability and decreases in activities of daily living (ADL) and quality of life (QOL). Recent advances in cancer treatment cause the prolonged survival and increase the prevalence of bone metastasis. Consequently, orthopaedic surgeons have been further involved in the diagnosis and treatment of the metastatic bone tumors (Naka N *et al.*, 2007).

The immunohistochemical results (CK 7 was positive and CK 20 was negative) strongly suggested that the origin of bone tumor in this case was from lung cancer. In addition to bone, the brain and adrenal glands are known to be

common sites of metastatic spread from lung cancer.

We hope that this case report will alert surgeons to think of bone metastases in a case of pathological fracture.

## CONCLUSION

Metastatic adenocarcinomas to bone were highly aggressive and presents with osteolytic lesions. Therefore metastatic deposits should always be kept as a differential diagnosis in all cases presenting with pathological fractures and showing osteolytic features.

## ACKNOWLEDGMENT

The authors wish to thank Dr. Surekha Arakeri U Professor, Department of Pathology and Dr. Ramu Royal, Post graduate student, Department of Pathology, BLDE University for helping in immunohistochemistry and manuscript preparation.

## REFERENCES

1. Torbert J T and Veillette C (2008), Metastatic Bone Lesions (Pathological Fractures), [Online] Feb 2, 2008, available at <http://www.orthopedia.com/x/J4FF>
2. Lipton A (2004), "Pathophysiology of Bone Metastases: How This Knowledge May Lead to Therapeutic Intervention", *J. Support Oncol.*, Vol. 2, No. 3, pp. 205-220.
3. Henry (2009), "Metastatic Tumors in Bone – Introduction" [Online], Aug 9, 2009, available at <http://www.bonetumor.org/metastatic-tumors-bone-introduction> Husain AN.
4. Kumar V, Abbas A K, Fausto N, Aster J C (Eds.) (2010), *Robbins and Cotran Pathologic Basis of Disease*, 8<sup>th</sup> Edition, Elsevier, pp. 677-736, New Delhi.
5. Naka N et al. (2007), "Acute Adrenal Crisis After Oorthopedic Surgery for Pathologic Fracture", *World Journal of Surgical Oncology*, Vol. 5, p. 27.