

## How safe are titanium clips for appendiceal base in laparoscopic appendicectomy?

Aparajita Saha\*, Girish K. Kullooli, Tejaswini Vallabha and Vikram Sindgikar

Department of General Surgery, BLDEA (DU) Shri B.M. Patil Medical College Hospital and Research Centre, Solapur Road, Vijayapur-586103 Karnataka, India

Received: 24<sup>th</sup> December 2019; Accepted: 15<sup>th</sup> September 2020; Published: 01<sup>st</sup> October 2020

**Abstract:** *Background:* The most important step in appendectomy is the closure of the stump. There a lot of variations to appendiceal stump closure as newer methods have been introduced although a consensus has not been reached as to which is best method. *Aim:* The aim of the study was to evaluate the safety and ease of use of titanium clips versus conventional knotting for appendiceal stump closure in laparoscopic appendicectomy. *Methods:* A total of 90 patients were included in this study, 45 in each group. The patients were divided into two groups- The first group included patients undergoing Endoclip closure (EC) and the second group included patients undergoing suturing (S). *Results:* In this study majority of patients belonged to the age group of less than 20 years, that is 57.8% in EC group and 40% in S group. In study group mean time of surgery was found to be 57.20+/-1.254 minutes. In control group it was 66.89+/-1.72 9minutes. P value was found to be significant. There were no intra operative or post-operative complications noted in both groups. Post-operative pain was comparable among both the groups. *Conclusion:* It can be concluded that titanium endoclips can be safely used for closure of appendiceal stump. It has several advantages like shorter time of surgery and lesser learning curve.

**Key words:** Appendiceal Stump, Laparoscopic Appendicectomy, Titanium Clips

### Introduction

Acute Appendicitis is the most common surgical condition requiring emergency intervention. Incidence of this condition is about 8%. Commonly it presents in the age group between 10-20years [1]. A male preponderance exists, with a male to female ratio of 1.4:1 [2]. Since appendicitis can progress very rapidly to a lot of complications like gangrene, perforation prompt intervention has to be undertaken to reduce morbidity and mortality [2].

Laparoscopic appendicectomy was first performed 39 years ago on 30<sup>th</sup> May 1980 by Dr Semm, a gynaecologist [3]. Also, laparoscopic approach can be done to rule out other diagnoses co existing with appendicitis, in females for pelvic and gynaecological pathologies and obese patients [4]. The most important step in appendectomy is the closure of the stump as postoperative complications may occur if there is inadequate closure. Complications like faecal fistulas, peritonitis followed by sepsis causes

severe morbidity [5]. There a lot of variations to appendiceal stump closure as newer methods have been introduced like endoloop, double endoloop, ultrasonically activated scalpel, knotting, bipolar coagulation, metal clip, hem o lock clip and linear endostaplers [1].

In various studies it has been proven that the newer techniques are easier to use, reduces operative time with less learning curve and hence best for beginners [6-10], although experienced surgeons prefer knotting to ligate the base due to inflammation or friability [4]. One of the novel techniques for appendiceal stump closure is by titanium clip. It is made of pure titanium, biocompatible, with a high closing force. The clips have parallel ends which helps the tissue adaptation to be good. Also, after closure the tissue gets compressed and hence there is very less axial displacement. As a result of the pyramid shaped inner surface it ensues a strong grip with the underlying tissues and thus prevents

slippage [4]. This study was done to evaluate the safety and ease of use of titanium clips versus conventional knotting for appendiceal stump closure in laparoscopic appendicectomy.

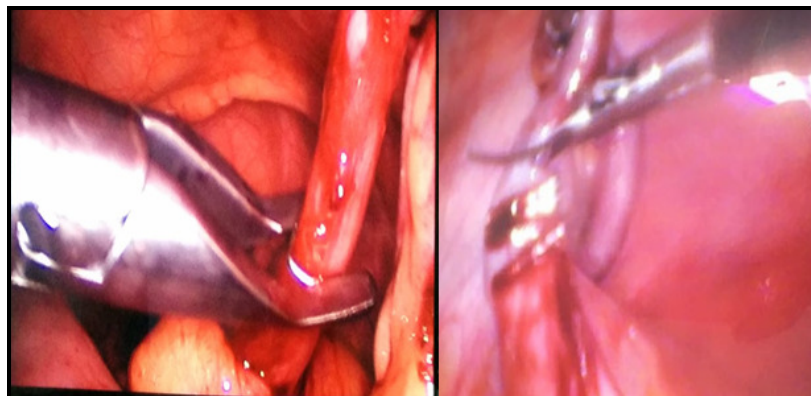
**Material and Methods**

A total of 90 patients were included in this study, 45 in each group. The patients were divided into two groups- The first group included patients undergoing Endoclip closure (EC) and the second group included patients undergoing suturing(S). Patients were allotted to either of the group to ensure that the two groups are adequately matched with respect to age, sex ratio and mean body mass index. Patients with complicated


appendicitis (perforated/ gangrenous appendicitis), bleeding disorders, not fit for general anesthesia were excluded from the study.

Diagnosis of appendicitis was made with respect to history (right iliac fossa [RIF] pain, vomiting, nausea, anorexia, and fever) and clinical signs (McBurney’s point tenderness, rebound tenderness), and laboratory tests (elevated leukocyte count) and confirmed by ultrasound abdomen and pelvis revealing either probe tenderness in the RIF or an aperistaltic, tubular appendix.

**Fig-1:** Application of titanium endoclips over appendix base for EC group



**Fig-2:** Titanium Clips



Routine pre and post-operative care were followed. Patients were kept in supine position and general anesthesia given. Pneumoperitoneum created with Veress needle through umbilical

port. Two 5 mm ports are placed over right iliac region and left iliac region with one 10mm port over umbilical were placed. The mesoappendix was skeletonized from the tip

to the base using cautery. The base of the appendix was then isolated. For Roeder’s knot group 2 knots 5 mm apart at base of appendix were applied. For Endoclip group 3 clips are applied (fig 1, 2). For the endoclip group after application of clips a 5mm scope was inserted through the 5mm port and appendix delivered out through the 10mm port. Operative findings and time were noted from skin incision to skin closure. Total number of days in hospital were noted. First follow up was done on 7<sup>th</sup>-10<sup>th</sup> post op day for suture removal and wound assessment followed by a subsequent follow up at 2 months.

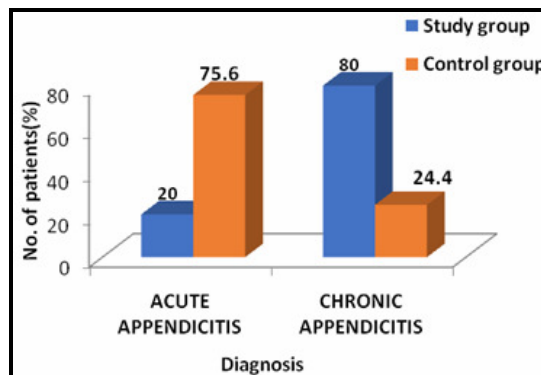
**Statistical Analysis:** Categorical variables were compared using chi square test, and quantitative variables were compared using Independent t test & Mann Whitney U test.

**Results**

In this study majority of patients belonged to the age group of less than 20 years, that is 57.8% in EC group and 40% in S group. Mean age was

21.56+/-12.48 years in the study group. In the control group it was found to be 24.02+/-11.58. Among 45 patients, 26(57.8%) were males in study group. In control group 25(55.6%) were males. Diagnosis of acute appendicitis was made in 20% in study while 75.6% in control group (fig 3). Chronic appendicitis was seen in 80% in study and 24.4% in control group. P value was found to be highly significant (table 1).

**Fig-3:** Diagnosis



Diagnosis	Study		Control		Chi square test	P value
	No. of patients	%age	No. of patients	%age		
Acute Appendicitis	9	20.0	34	75.6	X <sup>2</sup> =27.833	P<0001 HS
Chronic Appendicitis	36	80.0	11	24.4		
Total	45	100.0	45	100.0		

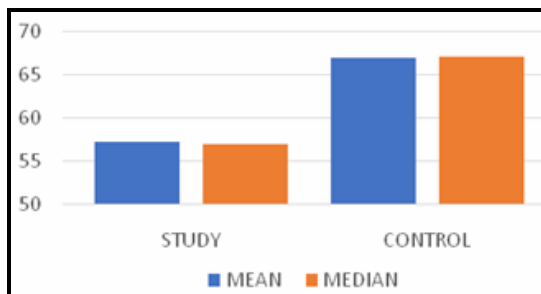
HS: Highly significant

In study group majority of patients had ultrasound findings of appendix base to be 7-8mm (31.11%) while in control group majority had more than 10mm (66.67%). P value was found to be highly significant. In study group mean time of surgery was found to be 57.20+/-1.254minutes (fig 4).

In control group it was 66.89+/-1.729minutes (table 2). P value was found to be significant. There were no intra operative or post-operative complications noted in both groups. Post-operative pain was comparable among both the groups. Mean length of hospital stay in study group was 3.53 and 3.42 in controls. Suture

removal was done on the 7<sup>th</sup> post-operative day. Follow up at 2 months was uneventful for all patients.

**Fig-4:** Time of Surgery



Variables	Study Group		Control Group		Mann Whitney U test	P value
	Mean (Median)	±SD	Mean (Median)	±SD		
Time of surgery (MIN)	57.20(57)	1.254	66.89(67)	1.729	U=0.00	<b>P&lt;0.001 HS</b>
NS: Not significant HS: Highly significant						

### Discussion

The most important step in appendectomy is closure of stump as complications may happen (like faecal fistula, peritonitis) due to inadequate closure [5]. There a lot of studies comparing methods for stump closure proving that these novel techniques have lesser learning curve, time saving and hence good for beginners [6-10]. But a consensus as to which method is best has not been reached yet. Although in a study by Kazemier et al. it has been proven that there is an advantage of stapling over loop ligatures with respect to infections. Titanium clips are the most commonly used clips in minimally invasive surgery because they are easy to use, safe, and inexpensive; however, they have not been regularly used for appendiceal stump closure [1].

In our study maximum percentage of appendicitis was seen in age group of less than 20years, 57.8 % in study and 40% in control group. The mean age was 21.56+/-12.48 in study group while it was 24.04+/-11.580 in control group. In a study by Nikhil Dixit it was reported that 18-30 years age group had the maximum presentation of appendicitis, in study group it was 70% and control group 63.33% [1]. In this study it was found that most of the patients in both study and control group were males. That is in study group it was 57.8 % and control group 55.6%. However, a study by Nikhil Dixit and colleagues showed female dominance ,that is,53.33 % in control group and 56.67% in study group, although it was not found to be statistically significant(p=0.795) [1]. In a study by Ates et al also showed majority of patients being males [11].

In our study majority of patients were found to have acute appendicitis in control group (75.6%). Whereas most of the patients in study group had chronic appendicitis (80%). It was found to be highly significant. In another study the incidence of acute appendicitis was found to be more in

both study and control, 83.33% in study and 80% in control [1]. Maximum percentage of patients belonged to 7-8mm appendix base range, 26.67% in study group. While in control group it was seen that most patients had a base range of more than 10 mm, that is about 66.67%. P value was found to be significant. A study by Noh Hyuck Park and co-workers in 2011 suggested that the mean outer diameter of more than 6mm is suggestive of appendicitis [12]. Also, the diameter of appendix base according to ultrasound or ct scan corresponds to the grade of inflammation and hence is a decisive factor for the use titanium clips [13].

The mean duration of surgery for study group was found to be 57.20+/-1.254 minutes. In control group it was found to be 66.89+/-1.729 minutes. P value was found to be highly significant. In a study by Nikhil Dixit and colleagues showed similar results of lesser mean duration of surgery for patients with titanium clip application (59.20+/-10.33minutes) as compared to knotting (68.47+/-6.30 minutes) [1]. In another study by Beldi G et al showed comparable time of surgery (46.3–64.9 min [14]. Findings of this study were also comparable when metal clips were used instead of intracorporeal knotting techniques in two recent small randomized trials with shorter operation time [5, 15].

In this study there were no intra operative complications. In a study by Nikhil Dixit et al showed similar results [1]. In a study by M Nadeem et al, it has shown similar results that post-operative pain was not statistically significant among both groups [4]. In this study none of the patients had surgical site infections. In another study by Rickert et al reported one case of surgical site infection, which was treated conservatively with antibiotics [13]. Mean duration of stay was

3.53 in study group and 3.42 in control which was not significant. According to the results of this study titanium clips are safe to use with shorter time of surgery and lesser learning curve. Hence this novel technique can be used as a safe alternative to Roeder's knotting for appendiceal stump closure.

### Conclusion

It can be concluded that titanium endoclips can be safely used for closure of appendiceal stump. It

has several advantages like shorter time of surgery and lesser learning curve.

### Acknowledgement

I would like to acknowledge the immense help received from my mentors in the Department of General Surgery, BLDEA (DU) Shri B.M. Patil Medical College Hospital and Research Centre, Solapur Road, Vijayapur.

**Financial Support and sponsorship:** Nil

**Conflicts of interest:** There are no conflicts of interest.

### References

- Dixit N, Gogate AS. A comparison of titanium clips versus roeder's knot tying suture in laparoscopic appendiceal stump closure: A randomised controlled trial study in KLES Dr Prabhakar Kore Charitable Hospital, Belgaum. *Indian J Health Sciences*. 2016; 9:49-55.
- Humes DJ, Simpson J. Acute appendicitis. *Br Med J*. 2006; 333:530-534.
- Semm K. Endoscopic Appendectomy. *Endoscopy*. 1983; 15:59.
- Nadeem M, Khan SM, Ali S, Shafiq M, Elahi MW, IHussain AF. Comparison of extracorporeal knot tying suture and metallic endo clips in laparoscopic appendiceal stump closure in uncomplicated acute appendicitis. *International J Surgery open*. 2016 ;2:11-14.
- Caglià P, Tracia A, Spataro D, Borzì L, Lucifora B, Tracia L, et al. Appendix stump closure with endoloop in laparoscopic appendectomy. *Ann Ital Chir*. 2014; 85:606-609.
- Delibegovic S, Matovic E. Hem-o-Lok plastic clips in securing of the base of the appendix during laparoscopic appendectomy. *Surg Endosc*. 2009; 23:2851-2854.
- Strzalka M, Matyja M, Rembiasz K. Comparison of the results of laparoscopic appendectomies with application of different techniques for closure of appendicular stump. *World Journal of Emergency Surgery*. 2016; 11:4.
- Gomes CA, Junior CS, de Peixoto RO, Bastos Netto JM, Gomes CC, Gomes FC. Appendiceal stump closure by metal endoclip in the management of complicated acute appendicitis. *World Journal of Emergency Surgery*. 2013; 8:35.
- Patryk M. Laparoscopic appendectomy using a single polymeric clip to close the appendicular stump. *Langenbecks Arch Surg*. 2010; 395:1077-1082.
- Hanssen A, Plotnikov S, Dubois R. Laparoscopic appendectomy using a polymeric clip to close the appendicular stump. *JSLs* 2007; 11:59-62.
- Ates M, Dirican A, Ince V, Ara C, Isik B, Yilmaz S. Comparison of intracorporeal knot-tying suture (polyglactin) and titanium endoclips in laparoscopic appendiceal stump closure: A prospective randomized study. *Surg Laparosc Endosc Percutan Tech*. 2012; 22:226-31.
- Park NH, Oh HE, Park HJ, Park JY. Ultrasonography of normal and abnormal appendix in children. *World J Radiol*. 2011; 3(4):85-91.
- Rickert A, Bönninghoff R, Post S, Walz M, Runkel N, Kienle P. Appendix stump closure with titanium clips in laparoscopic appendectomy. *Langenbecks Arch Surg*. 2012; 397:327-331.
- Beldi G, Vorburger SA, Bruegger LE, Kocher T, Inderbitzin D, Candinas D. Analysis of stapling versus endoloops in appendiceal stump closure. *Br J Surg*. 2006; 93:1390-1393.
- Akbiyik F, Senel E, Bayram-Kabacam G, Demirkan H, Atayurt H, Tiryaki T. A comparison of polymer clips and endoloop applications for securing the appendiceal stump during laparoscopic surgery in children. *Surg Laparosc Endosc Percutan Tech*. 2011; 21:349-352.

**Cite this article as:** Saha A, Kullolli GK, Vallabha T and Sindgikar V. How safe are titanium clips for appendiceal base in laparoscopic appendectomy? *Al Ameen J Med Sci* 2020; 13(4):286-290.

This is an open access article distributed under the terms of the Creative Commons Attribution-Non Commercial (CC BY-NC 4.0) License, which allows others to remix, adapt and build upon this work non-commercially, as long as the author is credited and the new creations are licensed under the identical terms.

\*All correspondences to: Dr. Aparajita Saha, Senior Resident, Department of General Surgery, BLDEA (DU) Shri B.M. Patil Medical College Hospital and Research Centre, Solapur Road, Vijayapur-586103 Karnataka, India. Email: aparajitasaha6@gmail.com