



## International Journal of Orthopaedics Sciences

E-ISSN: 2395-1958  
P-ISSN: 2706-6630  
IJOS 2021; 7(2): 53-58  
© 2021 IJOS  
[www.orthopaper.com](http://www.orthopaper.com)  
Received: 12-02-2021  
Accepted: 27-03-2021

**Dr. Siddhant Sanjay Gandhi**  
Junior Resident, Department of  
Orthopaedics, BLDE Deemed to  
be University, Shri BM Patil  
Medical College Hospital and  
Research Center, Vijayapura,  
Karnataka, India

**Dr. Santosh S Nandi**  
Professor and Unit Chief,  
Department of Orthopaedics,  
BLDE Deemed to be University,  
Shri BM Patil Medical College  
Hospital and Research Center,  
Vijayapura, Karnataka, India

**Dr. Sandeep Naik**  
Associative Professor,  
Department of Orthopaedic,  
BLDE Deemed to be University,  
Shri BM Patil Medical College  
Hospital and Research Center,  
Vijayapura, Karnataka, India

**Dr. Shreepad Kulkarni**  
Assistance Professor,  
Department of Orthopaedic,  
BLDE Deemed to be University,  
Shri BM Patil Medical College  
Hospital and Research Center,  
Vijayapura, Karnataka, India

**Dr. Gireesh Khodnapur**  
Assistance Professor,  
Department of Orthopaedic,  
BLDE Deemed to be University,  
Shri BM Patil Medical College  
Hospital and Research Center,  
Vijayapura, Karnataka, India

**Corresponding Author:**  
**Dr. Siddhant Sanjay Gandhi**  
Junior Resident, Department of  
Orthopaedics, BLDE Deemed to  
be University, Shri BM Patil  
Medical College Hospital and  
Research Center, Vijayapura,  
Karnataka, India

### A clinical study of functional outcome of unstable intertrochanteric fractures treated with proximal femur nail anti rotation system II

**Dr. Siddhant Sanjay Gandhi, Dr. Santosh S Nandi, Dr. Sandeep Naik, Dr. Shreepad Kulkarni and Dr. Gireesh Khodnapur**

**DOI:** <https://doi.org/10.22271/ortho.2021.v7.i2a.2613>

#### Abstract

**Introduction:** Unstable, Comminuted intertrochanteric fractures continue to pose a challenge to the orthopaedic surgeon because of severe osteoporosis and medical disorders that increase the risks associated with surgery and anaesthesia. To overcome problems like lateral wall impingement and prominence of the proximal end of the nail, the PFNA-II was introduced in 2008. The PFNA II design modifications include the flat lateral shape of the proximal portion and a decrease in the mediolateral bending angle from 6° to 5°. The purpose of the study is to confirm that the PFNA II eliminates the problem of lateral wall impingement experienced with previous intramedullary nailing systems and provides stable fracture fixation with positive functional outcome.

**Materials and methods:** This study was conducted on 52 patient of which 32 were available till follow up of 6 months. All patients were diagnosed with unstable intertrochanteric fracture of femur and underwent closed reduction internal fixation with proximal femoral nail anti-rotation system II. Functional outcome was assessed with Modified Harris Hip Score and radiological outcome was assessed with TAD score and implant related complications.

**Results:** Fracture union was appreciated on an average 4 months of postoperative period. 4 patient had superficial infection while 1 patient had deep infection. Only 1 patient had cut off of helical blade. According to modified Harris hip score, excellent to good outcome was noted in more than 80% of patient.

**Conclusion:** From our study, we conclude that PFNA II can be a reliable and implant of choice for the management of unstable intertrochanteric fracture with high rates of union, restoring the anatomical alignment with less chances of implant failure and reduced chance of implant failure.

**Keywords:** Intertrochanteric fracture, internal fixation, PFNA II

#### Introduction

Intertrochanteric fractures commonly occur in elderly patients with osteoporosis and its incidence will continue to rise due to the increasing life expectancy [1]. Nearly nine of 10 hip fractures occur in patients older than 65 years old. Operative treatment of hip fractures was introduced in the 1950s. Many methods have been recommended for the treatment of intertrochanteric fractures. Implants may be either extra-medullary or intramedullary in nature [2].

Treatment of intertrochanteric fractures in elderly patients is a huge challenge for many trauma surgeons, mainly because many such patients have severe osteoporosis and medical disorders that increase the risks associated with surgery and anaesthesia [3].

PFNA was designed by AO in 2004, is an intramedullary device with a helical blade rather than a screw for better purchase in the femoral head [2]. Although it is known PFNA system provides high union rates with low major complication rates, geometric discrepancies exist between the proximal femur and PFNA system. This geometric mismatch is associated with lateral cortical impingement, which causes lateral cortical fracture and intraoperative loss of reduction when inserting the PFNA [4].

PFNA II devices have been introduced as an improved PFNA design to overcome these problems. The PFNA II design modifications include the flat lateral shape of the proximal portion and a decrease in the mediolateral bending angle from  $6^{\circ}$  to  $5^{\circ}$  [4].

The purpose of the study is to confirm that the PFNA II eliminates the problem of lateral wall impingement experienced with previous intramedullary nailing systems and provides stable fracture fixation with positive functional outcome.

### Materials and Methods

It was a Prospective Cross-Sectional Study at the end of the study period, results of 32 patients formulated and conclusion was driven. With 95% confidence level and margin of error of  $\pm 15\%$ , a sample size of 32 subjects allowed the study to determine "the functional outcome of unstable intertrochanteric fractures treated with proximal femur nail anti rotation system II" with finite population correction (N=120). By using the formula:

$$n = z^2 p(1-p)/d^2$$

Where, Z = z statistic at 5% level of significance, d is margin of error, p is anticipated prevalence rate (50%).

If the p-value was  $< 0.05$ , then the results were considered to be statistically significant otherwise it was considered as not statistically significant. Data were analyzed using SPSS software v.23 (IBM Statistics, Chicago, USA) and Microsoft office 2007.

### Method of collection of data

This study is conducted between 1st November 2018-31st may 2020 among patients admitted in Department of Orthopaedics in BLDE (Deemed to be university) Shri B.M. Patil Medical College, Hospital and Research Centre, Vijayapura who are diagnosed with unstable inter-trochanteric fracture of femur. 32 patients were assessed by clinical examination, history taking, clinical and radiological examination. The patients were informed about study in all respects and informed written consent was obtained.

All patients underwent closed reduction internal fixation with proximal femoral nail anti-rotation system II and were followed up on 6<sup>th</sup> weeks, 3<sup>rd</sup> months, 6<sup>th</sup> months.

### Inclusion criteria

Patient aged 50 years and above, closed unstable intertrochanteric fracture of femur according to AO classification, patients willing for treatment and giving informed and written consent.

### Exclusion criteria

Patients with poly trauma, pathological fractures, associated neurovascular injury, patients medically unfit for surgery, immunocompromised status, non-union or mal-union cases.

Routine standardised protocols for investigation and interventions were followed on admission of patient.

There is no animal experiment involved in this study.

### Investigations

- X-ray of affected femur AP & Lateral views.
- X-ray pelvic with both hip joints AP view

Multiple surgeons were involved in the surgeries in this study. Delay in the time of surgery after admission was usually attributable to poly-trauma or poor medical condition of the patient.

After radiological investigation bucks traction was applied to

affected extremity. Pain management with intravenous analgesics was done.

### Pre-operative planning

- Nail diameter was determined by measuring width of inner cortex of the femur at the level of isthmus as it is the narrowest part of medullary cavity. This measurement is taken on an x-ray of affected femur using a software in department of radiology.
- Angle between neck and the shaft was measured on unaffected side. This measurement was taken on an AP x-ray using a transparent goniometry device.

### Implant details

PFNA II implant is made up of either 316L stainless steel. It consists of an intra-medullary nail, helical blade, distal locking bolts and top screw.

NAIL: Nail has various lengths, diameters and angles.

- Length: 170 mm, 200 mm, 240 mm and Long PFNA-340 to 420 mm. (With increment of 40 mm)
- Diameter: 9,10,11,12 mm
- Neck shaft angle range:  $130^{\circ}$  and  $135^{\circ}$ .

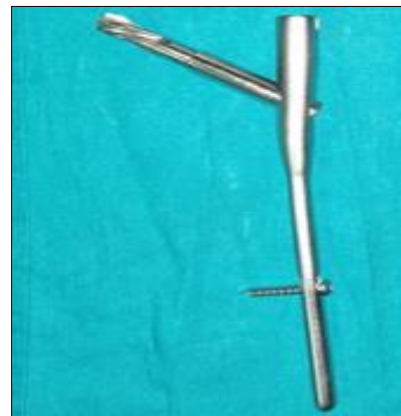

Fig 1: Show the surgery tools

The nail is having 16.5 mm proximal diameter which increases the stability of the implant. There is  $5^{\circ}$  mediolateral valgus angle, which prevent lateral wall fractures and varus collapse. The long nails have an anterior curvature of 1.5m radius to match the anatomic anterior femoral bowing.

Proximally the nail has 1 hole for the insertion of the 11 mm helical blade with internal locking system. The helical blade provides intra-operative telescopic compression of 5 mm under c-arm guidance, which allows compression at fracture site and prevent rotation.

Distally, Short nail has one hole for insertion of 4.9 mm locking screws, of which can be used either for 900 static locking, oblique locking, dynamic locking with the help of a jig. Long nail has 2 holes of which 1 is used for static locking and 2nd one is used for dynamic locking.

### Procedure

Closed reduction internal fixation was carried out in all patient on traction table. Closed reduction was attempted with traction and manipulation of the limb under c-arm guidance. Incision of 5cms was taken longitudinally from 1 cm proximal to the tip of the greater trochanter extending upwards.

Entry point was made with bone awl immediately lateral to tip of the greater trochanter in antero-posterior view and along the central axis of femur in lateral view. Proximal metaphyseal trochanteric reaming done with reamer of size 17 mm over guide wire. Medullary canal reaming done using flexible reamers starting from 8 mm diameter with subsequent

increments of 0.5 mm up to 1 mm greater than the nail diameter selected for insertion. Under the image intensifier, the selected nail was inserted manually using slight rotator movements of the insertion handle to such a depth that it allowed the helical blade to be placed through the junction of middle and lower third of femoral neck. Lateral cortex was opened with the 10 mm drill bit inserted over the guide wire placed for helical blade. Then unlocked PFNA II blade was inserted through fracture site by applying gentle blows with the hammer under guidance of image intensifier. Locking of PFNA II blade is then carried with turning impactor clockwise. Distal locking is then carried out with bolt and followed by top screw fixation. Isometric and range of motion exercises were begun from post-operative day 1 or day 2. Post-operative AP and cross table lateral view x-rays were taken on day 3. Sterile dressing was done on post-operative day 3, day 6, day 10. Sutures were removed between postoperative day 10 and 12.

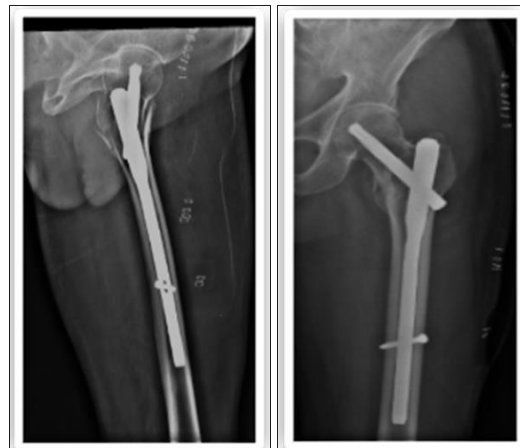

Fig 3: 3 Months post opp

**Follow up**

All the patients were followed up on 6<sup>th</sup> week, 3<sup>rd</sup> month, 6<sup>th</sup> month.

Clinically patients were evaluated by presences of fresh complaints, general physical examination, local examination and Modified Harris Hip Score.

Radiologically patients were evaluated by presence of implant and fracture related complication and TAD score.

**Case No. 1**

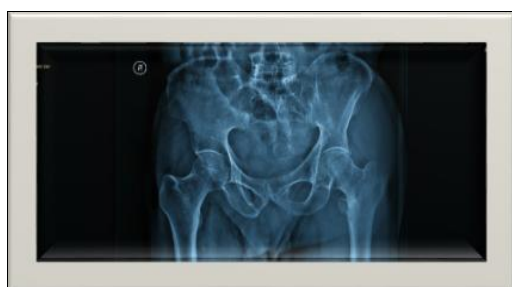

Fig 2: Preoperative radiograph

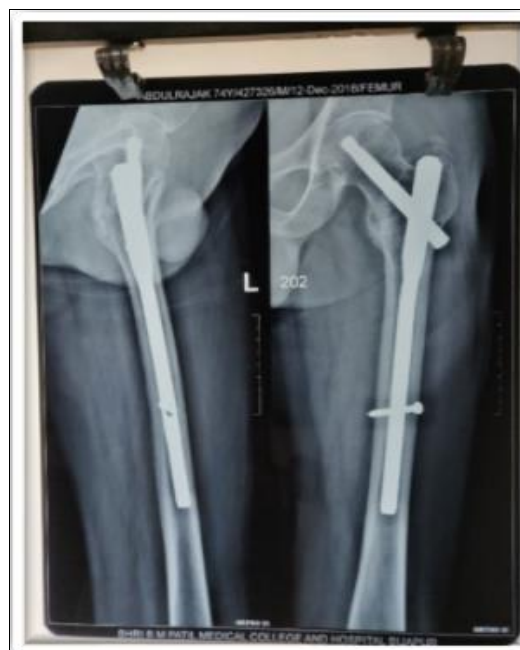

Fig 4: 6 Month post-operative

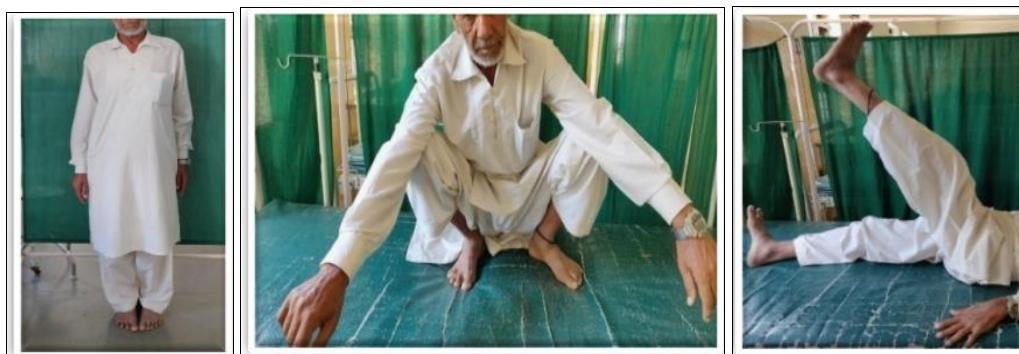

Fig 5: Clinical outcome images

**Case No. 2**

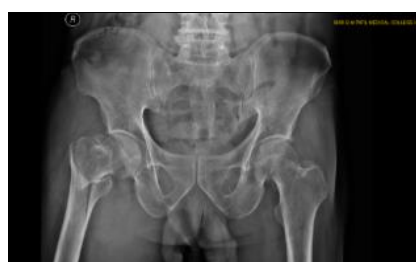
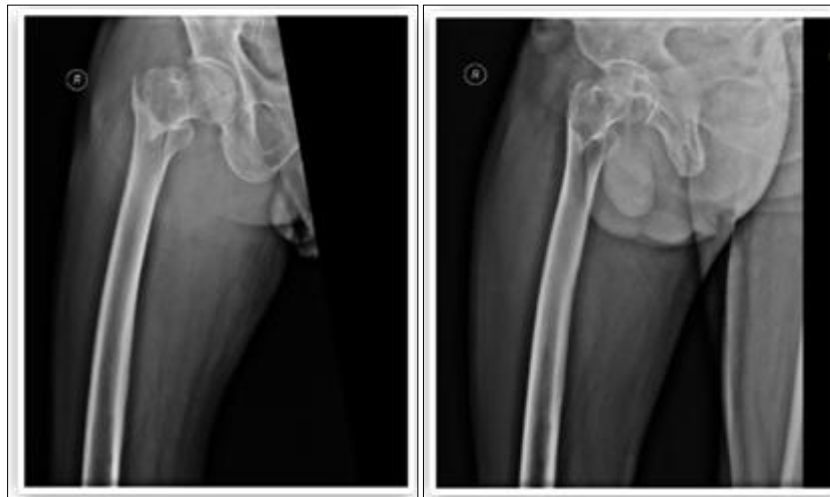
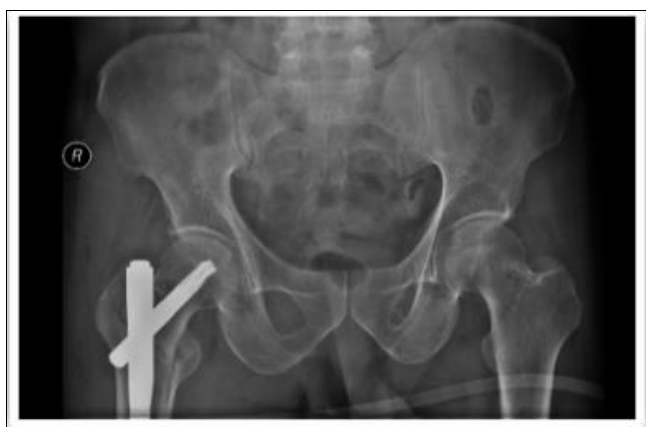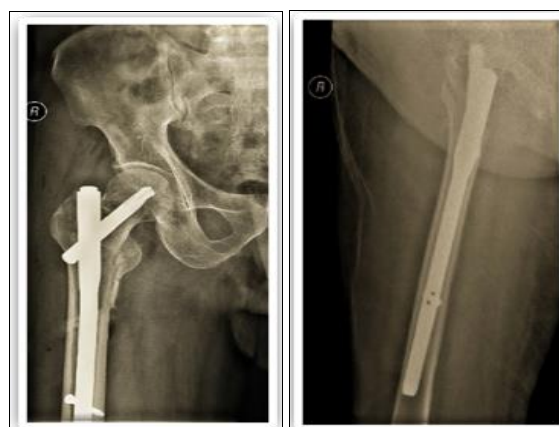Fig 6: Pre-operative pelvic with both hip joint X-ray



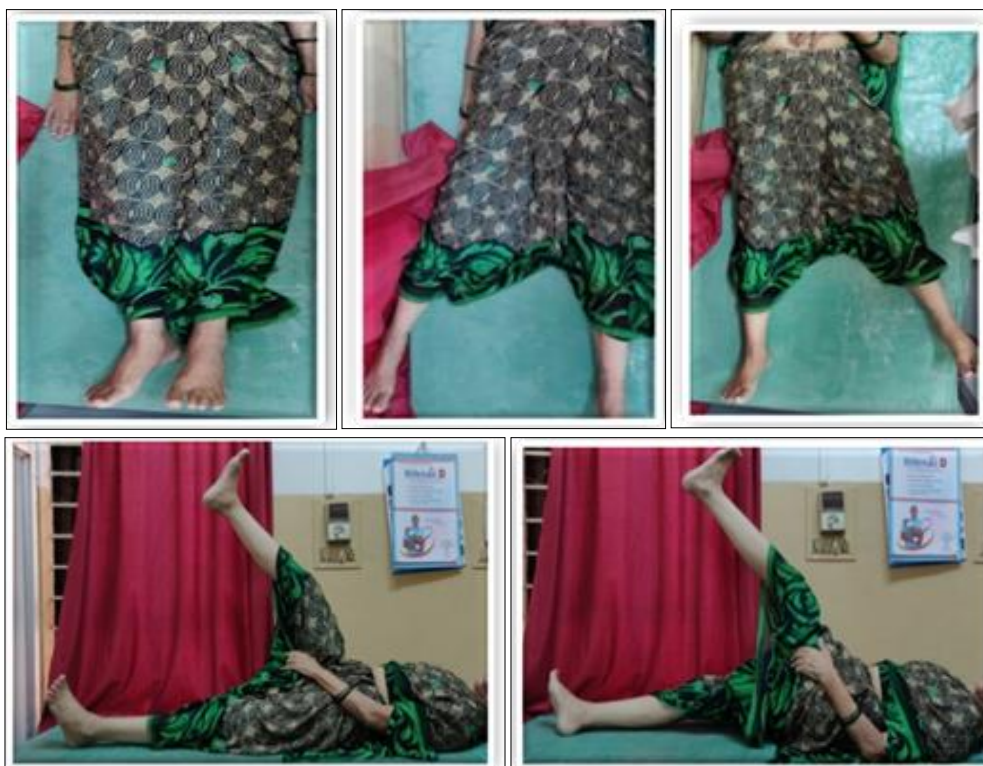**Fig 7:** Pre-operative femur with hip joint AP-LAT X-ray



**Fig 8:** Immediate post-operative image



**Fig 9:** Post-operative 6 Month X-ray



**Fig 10:** Post-operative clinical outcome

**Results and Discussion**

In this study, 56.3% of patient were in the age group of 61 years to 70 years. Their mean age was found to be 68.5 years.

Out of 32 patient 22 were female and 10 were male. Higher incidence of trochanteric fracture was found be noted in female population. Out of 32 patient, 20 patient had suffered

fracture of hip due to self-fall (trivial trauma) and 12 patient had suffered hip fracture due to road traffic accident (RTA). All the 32 patient had suffered unstable inter-trochanteric fracture. According to AO fracture classification 18 patients had 31A2 type and 14 patients had 31A3 type of fracture. Mean intra-operative time required for surgery was found to be 68 minutes.

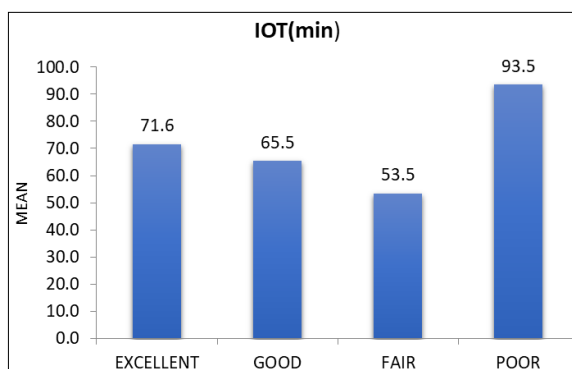


Fig 11: Change in mean IOT (Intraoperative time) according to result

Full weight bearing mobilization was started according to pain and signs of union confirmed on X-ray. 21 patients (65.7% patients) had started bearing full weight by 4th and 5th month. Mean time after surgery for full weight bearing mobilization was found to be 4.4 months.

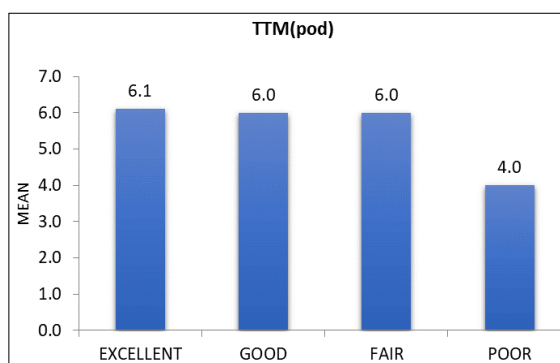


Fig 12: Change in mean TTM according to result

4 patients had superficial infection which was treated with I.V. antibiotics according to culture sensitivity report. One patient had deep infection which was treated with surgical debridement and I.V. antibiotics for 1 week followed by oral antibiotics.

One patient suffered loss of reduction due to blade cut-off through head in 2nd month of postoperative period. This patient had undergone implant removal procedure followed by total hip replacement.

Mean Harris Hip Score was calculated as 85.1.

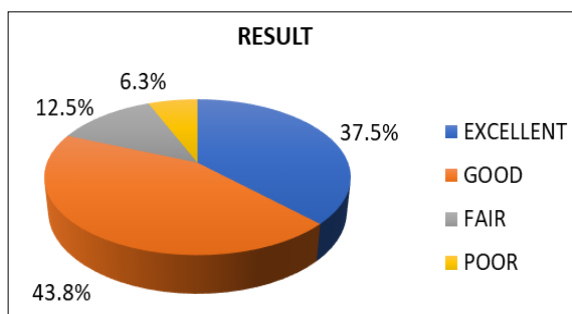


Fig 13: Results

Table 1: Change in mean HHS according to result

Parameters	Result				P value
	Excellent	Good	Fair	Poor	
HHS	92.3±1.2	83.7±2.5	77±2	68±0	<0.001*

Mean TAD score was found to be 24.8 (19 to 28).

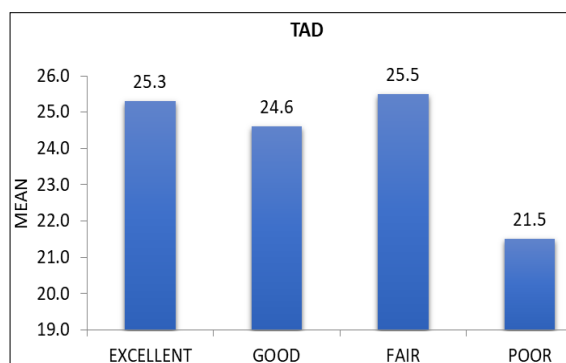


Fig 14: Change in mean TAD according to result

Discussion

Peri-trochanteric fractures are most common in elderly population. As the average life expectancy is increasing, incidence of hip fracture is rising. Owing to the osteoporosis and associated co-morbid conditions, management of hip fractures in older population has always been difficult for an average orthopedic surgeon. Intramedullary devices are used widely because of their mechanical and biological advantage. Helical blade produces better purchase in osteoporotic cancellous area of femoral head. This is achieved by radial compaction of surrounding cancellous bone around the helical flanges, providing more back out residence. It is found that there is less reaming of bone stock with helical blade compared to screw. There is no need of additional application of de-rotation screw because of the olive shape of proximal part of helical blade.

PFNA2 was introduced with flattened lateral wall and reduced medio-lateral angle from 6° to 5° [4]. These characteristic changes reduced the problem of lateral wall impingement which was seen with other older implants. Using this device very few studies have been carried out in Indian population.

None of the patients included in this study had suffered lateral wall impingement or fracture during the procedure. We had not encountered any cases of iatrogenic femoral shaft fracture. All surgeries were carried out by surgeon of our university. Mean intra-operative time was found to be 68 minutes with minimum time noted was of 34 minutes.

This reduced intra operative time period had reduced anaesthetic complication and blood loss. Also, increased time period of operation owing to difficulty fracture pattern morphology were statistical related to poor functional outcome (p-value: 0.046).

Most of the patients were allowed toe-touch mobilization by 5<sup>th</sup> to 7<sup>th</sup> day of post-operative period. Time of starting toe-touch mobilization was not related to function outcome statistically (p-value: 0.210).

Full weight bearing mobilization was allowed in all at the time of appearance of signs of union on X-ray. Most of the patient had started full weight bearing by 3-4 months.

These values were also not related to clinical outcome at 6 months follow up (P=0.321)

Radiological outcome was assessed on the basis of TAD score and complications related to fracture reduction and implant failure.

On 6 months of follow-up we have encountered one case of

screw cutoff from superior aspect of head and neck.

This patient had TAD score of 19 mm on immediate postoperative x-ray radiograph.

Patient was then managed with implant removal and total hip replacement surgery.

This confirms the association of TAD score with prognosis.

George A Macheras MD retrospectively reviewed 108 patients of unstable intertrochanteric fractures treated with PFNA I and PFNA II. Aruthur had concluded that patients treated with PFNA II had reduced intraoperative time, blood loss, time of mobilization. Functional outcome assessed using Harris hip score turned out to be between 72 to 89 points which is comparable with our study<sup>[5]</sup>.

Ming Hui Li studied 163 elderly people with unstable intertrochanteric fracture treated with PFNA2. It comprised of 69 men and 94 women with mean age of 74.7 years. Statistical analysis of this study revealed an average operation time of 45.7min (35-100 min) was required. Mean Harris hip score was 85.6 +/- 7.5 points, which included 41 excellent cases (25.15%), 92 good cases (56.44%), 26 fair cases (15.95%) and 4 poor cases (2.45%). All these data's were comparable with our study<sup>[3]</sup>.

G.N. Kulkarni studied 42 patients between the age group of 35 years to 90 years with mean age of 61 years diagnosed with unstable intertrochanteric fracture. All patients were treated with Closed Reduction Internal Fixation with PFNA II. On follow up of 15.3 months, excellent to good results were found in 78% cases as assessed by Hams hip score which is comparable with our study (HHS: 81.3)<sup>[1]</sup>.

## Conclusion

In our study we had collected data from 32 patients. These 32 patients were diagnosed with unstable inter-trochanteric fracture and were treated with Proximal Femoral Nail Anti-rotation System II.

Proximal femoral nail anti-rotation system II is a newer version of cephalomedullary implants used for intertrochanteric fracture. After statistically computing, analysing results of our study we have come to following conclusions.

- Unstable intertrochanteric fracture have higher incidence in geriatric population.
- In most of the cases, low energy trauma (self-fall) was found to be the cause of the fracture.
- Even though learning curve of this procedure is high with the experience gained from each case, intra-operative time, intra-operative blood loss, radiation exposure, anaesthetic complications are markedly reduced.
- Helical blade should be placed at the junction of upper 2/3<sup>rd</sup> and lower 1/3<sup>rd</sup> of neck and center position in head of the femur.
- This geometric mismatch which was associated with previous implants causing lateral cortical impingement leading to lateral cortical fracture and intraoperative loss of reduction were overcome in newer PFNA II implant modification.
- Post-operative time at which the toe-touch mobilization and full weight bearing mobilization is started does not significantly affect the functional out come after 6 months of surgery.

## Reference

1. Kumar GK, Sharma G, Khatri K, Farooque K, Lakhota D, Sharma V *et al.* Treatment of unstable intertrochanteric fractures with proximal femoral nail

anti-rotation II: our experience in Indian patients. The open orthopaedics journal 2015;9:456.

2. Sadic S, Custovic S, Jasarevic M, Fazlic M, Smajic N, Hrustic A *et al.* Proximal femoral nail antirotation in treatment of fractures of proximal femur. Medical archives 2014;68(3):173.
3. Li M, Wu L, Liu Y, Wang C. Clinical evaluation of the Asian proximal femur intramedullary nail anti-rotation system (PFNA-II) for treatment of intertrochanteric fractures. Journal of orthopaedic surgery and research 2014;9(1):112.
4. Shin WC, Seo JD, Lee SM, Moon NH, Lee JS, Suh KT. Radiographic outcomes of osteosynthesis using proximal femoral nail anti-rotation (PFNA) system in intertrochanteric femoral fracture: has PFNA II solved all the problems? Hip & Pelvis 2017;29(2):104-12.
5. Macheras GA, Koutsostathis SD, Galanakos S, Kateros K, Papadakis SA. Does PFNA II avoid lateral cortex impingement for unstable peritrochanteric fractures? Clinical Orthopaedics and Related Research® 2012;470(11):3067-76.