

Case Report

Necrotizing fasciitis of bilateral breast - A rare presentation

Savitri Mallikarjun Nerune

Department of Pathology, BLDE (DU) Shri B. M. Patil Medical College, Vijayapura, Karnataka, India

Abstract

Necrotizing fasciitis (NF) is a progressive infection of skin and soft tissues that can involve anterior abdominal wall, perianal region, scrotum, and extremities, but bilateral breast involvement is extremely rare. To prevent morbidity and mortality, early diagnosis and proper treatment are essential. We report a case of NF of the bilateral breast in a 20-year-old female patient who presented with sudden onset of pain and blackish discoloration of skin of both the breasts.

Keywords: Antibiotics, debridement, polymicrobial infection

Address for correspondence: Dr. Savitri Mallikarjun Nerune, Department of Pathology, BLDE (DU) Shri B. M. Patil Medical College, Vijayapura, Karnataka, India.

E-mail: savitri.nerune@bldedu.ac.in

Submitted: 04-Aug-2021 **Accepted:** 17-Aug-2021 **Published:** 22-Dec-2021

INTRODUCTION

Necrotizing fasciitis (NF) is a rapidly spreading progressive infection of the fascia with necrosis of subcutaneous tissues and associated with systemic toxicity. It can occur at various sites such as the scrotum, perianal region, anterior abdominal wall, and extremities.^[1,2] NF of the bilateral breast is a very rare condition.^[3] It usually affects lactating and postmenopausal women.

NF of the breast is a fulminating condition that can lead to sepsis, multiorgan dysfunction syndrome, and eventually death. It has a very high mortality rate. It requires early diagnosis and treatment with debridement, antibiotics, and frequently mastectomy.^[3,4] Here, we present a case of NF of the bilateral breasts in a 20-year-old lactating female who presented with fever and generalized weakness with sudden onset of pain and discoloration of skin in bilateral breasts.

CASE REPORT

A 20-year-old lactating female, P₁L₁ presented with sudden onset of pain and blackish discoloration of the skin of both breasts for the past 2 days associated with fever and generalized weakness. There was no history of swelling, nipple discharge, and trauma. There was no family history/past history of a thromboembolic episode.

On examination, the patient was fully conscious and oriented. She was febrile with a blood pressure of 90/44 mmHg and a pulse rate of 130/min. On local examination, both breasts were enlarged, warm, and tender. There was blackish discoloration of the skin of both breasts extending up to nipple-areolar complex associated with blebs in the left breast measuring 3 cm × 2 cm and the surrounding skin was erythematous and inflamed. There was no pus discharge. Her investigations showed: Hb - 10.7 gm%, total white blood cell count - 16,400/cumm, platelet

Access this article online	
Quick Response Code:	Website: www.ijcpc.org
	DOI: 10.4103/ijcpc.ijcpc_8_21

This is an open access journal, and articles are distributed under the terms of the Creative Commons Attribution-NonCommercial-ShareAlike 4.0 License, which allows others to remix, tweak, and build upon the work non-commercially, as long as appropriate credit is given and the new creations are licensed under the identical terms.

For reprints contact: WKHLRPMedknow_reprints@wolterskluwer.com

How to cite this article: Nerune SM. Necrotizing fasciitis of bilateral breast - A rare presentation. *Int J Clinicopathol Correl* 2021;5:82-4.

count - 1.5 lakhs/cumm, blood glucose level - 98 mg%, serum sodium - 132 mEq/l, serum potassium - 3.7 mEq/l. C-reactive protein was 156 mg/l. The patient's laboratory risk indicator for necrotizing fasciitis (LRINEC) score was 8 points. HIV, HBsAg, and HCV tests were negative.

The patient was started with broad-spectrum intravenous (IV) antibiotics and with a provisional diagnosis of NF; surgical debridement was done. Intraoperatively, necrosis and ulceration of the skin along with necrosis of bilateral breast tissue were noted. Necrosed skin, breast tissue, and slough were removed and sent for histopathological examination.

On gross examination, the specimen showed multiple fibrofatty tissue masses covered with skin. The ulcer was noted on skin measuring 4.5 cm × 3 cm. Largest tissue mass measured 11 cm × 9 cm × 3 cm and smallest 2 cm × 2 cm. Multiple sections were given and slides were stained with H and E stain. On microscopic examination, multiple sections studied showed tissue lined by stratified squamous epithelium with focal ulceration of epithelium. Subepithelium showed fibrocollagenous tissue and proliferation of acini and lobules with acute inflammatory cell infiltrate comprised neutrophils and nuclear debris infiltrating into acini and lobules [Figure 1]. Necrosis of fibrocollagenous tissue and lobules were noted [Figure 2]. Inflammatory cell infiltrates in adipose tissue and congested and dilated blood vessels were also noted, so diagnosis offered was necrotizing fasciitis of bilateral breasts. Tissue culture examination showed *Streptococcus pyogenes* organisms sensitive to bacitracin. The patient was started with injectable bacitracin but succumbed to death on 3rd postoperative day due to sepsis.

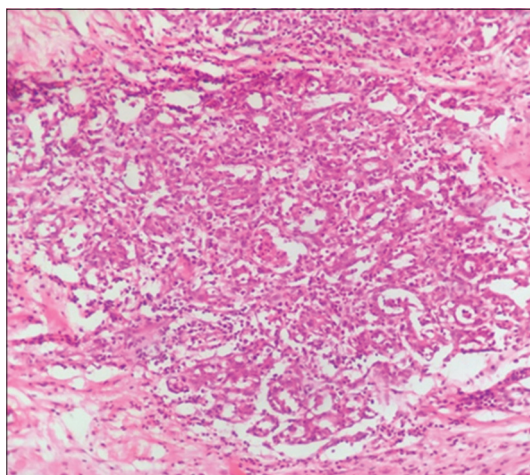


Figure 1: Photomicrograph showing acute inflammatory cell infiltrate comprised neutrophils and nuclear debris infiltrating into acini and lobules (H and E, ×100)

DISCUSSION

NF was first identified in 500 BC when a clinical description of a complication of erysipelas disease, resembling the current description of NF, was reported by Hippocrates. In 1952, Wilson first defined the entity necrotizing fasciitis as necrosis of the fascia and subcutaneous tissue sparing the muscle. In the late 1980s, Stevens diagnosed 11 patients of NF among 20 patients who presented with streptococcal shock. This disease was popularized by media as “Flesh-eating bacteria” syndrome.^[4] First case of NF of the breast was reported by Shah *et al.* in 2001.^[1] It commonly involves scrotum (Fournier's gangrene), perineal region, anterior abdominal wall (Meleney's ulcer), and extremities.^[1,2]

NF is seen in patients suffering from chronic renal failure, chronic alcohol disease, peripheral vascular disease, diabetes mellitus, hypertension, liver cirrhosis, and HIV and can occur after trauma, in IV drug abusers and patients on oral contraceptive pills and corticosteroids.^[5,6] In the present case, there was no history of chronic renal failure, chronic alcohol disease, peripheral vascular disease, diabetes mellitus, hypertension, and liver cirrhosis. The patient was not immunocompromised, and there was no history of oral contraceptive pills and corticosteroids. NF usually affects lactating and postmenopausal women.^[3] In the present case, there was history of lactation and unnoticed trauma during lactation might have developed NF.

NF can be classified into four types. Type I is the most common polymicrobial type caused by anaerobes. Type II is monomicrobial, caused by beta-hemolytic *Streptococcus A* (*S. pyogenes*) and *Staphylococcus aureus*. Type III is monomicrobial, caused by *Clostridium* species

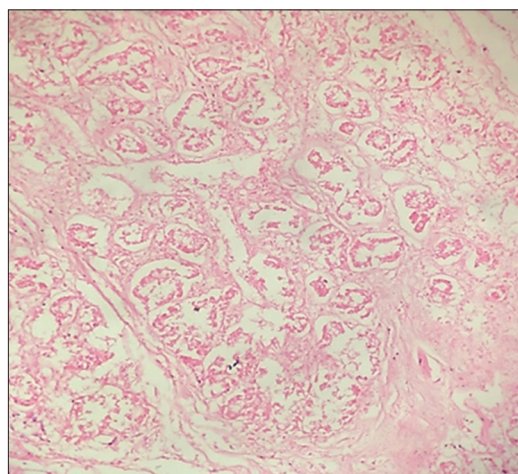


Figure 2: Photomicrograph showing necrosis of fibrocollagenous tissue and lobules (H and E, ×100)

Table 1: Laboratory risk indicator for necrotizing fasciitis score

Variable	Score
C-reactive protein	
<150	0
≥150	4
WBC (cells/mm ³)	
<15	0
15-25	1
>25	2
Hb (g/dL)	
>13.5	0
11-13.5	1
<11	2
Sodium (mmol/L)	
≥135	0
<135	2
Creatinine (mcg/L)	
≤141	0
>141	2
Glucose (mmol/L)	
≤10	0
>1	1

Hb: Hemoglobin, WBC: White blood cell count

or Gram-negative bacteria. Type IV is caused by fungal infections such as *Candida* species and *Zygomycetes*.^[6] In the present case, the causative organism was *S. pyogenes*.

The patients with NF commonly presents with erythema, skin induration, edema, fever, and pain, which mimics simple cellulitis and abscess delaying the diagnosis. Diagnosis of NF is suspected when the patient presents with pain out of proportion to severity of the lesion, or there is no response to broad-spectrum IV antibiotics.^[7]

Histopathology of the excised tissue in the NF of the breast shows necrosis and inflammation of the skin and breast parenchyma, many bacterial organisms within the necrotic zones, and neutrophilic infiltrate with no evidence of neoplasia.^[8] In the present case, histopathological examination showed ulceration, necrosis, and inflammation of the skin along with necrosis of the breast parenchyma with neutrophilic infiltrate. There was no evidence of malignancy, so diagnosis of NF was done.

The diagnosis of NF can be suspected clinically based on LRINEC proposed by Wong *et al.*^[6,7] [Table 1]. LRINEC is a tool based on a set of laboratory values where score of 6 or more helps in differentiating NF from other soft tissue infections. LRINEC score of indexed case was 8 points favoring the diagnosis of NF. Other diagnostic modalities in patients with LRINEC score of >5 includes computed tomography or magnetic resonance imaging, finger test, and frozen section biopsy.^[6]

Management includes early and aggressive treatment with broad-spectrum antibiotics, extensive surgical debridement and resuscitation.^[4] Prognosis is bad as it can lead to significant morbidity and mortality. The present case also succumbed to death on 3rd postoperative day due to sepsis.

Financial support and sponsorship

Nil.

Conflicts of interest

There are no conflicts of interest.

REFERENCES

1. Yaji P, Bhat B, Harish E. Primary necrotising fasciitis of the breast: Case report and brief review of literature. *J Clin Diagn Res* 2014;8:D01-2.
2. Pote MP, Kelkar PV, Bhople L, Patil A. Necrotizing fasciitis of the breast: A rare presentation in post-partum mother. *IOSR JDMS* 2013;11:16-8.
3. Rehman T, Moore TA, Seoane L. *Serratia marcescens* necrotizing fasciitis presenting as bilateral breast necrosis. *J Clin Microbiol* 2012;50:3406-8.
4. Singh G, Bharpoda P. Necrotizing fasciitis of breast. *Internet J Med Update* 2013;8:79-80.
5. Wani I, Bakshi I, Parray FQ, Malik AA, Wani RA, Shah M, *et al.* Breast gangrene. *World J Emerg Surg* 2011;6:29.
6. Misiakos PE, Bagias G, Patapis P, Sotiropoulos G, Kanavidis P, Misiakos A. Current concepts in the management of necrotizing fasciitis. *Front Surg* 2014;1:1-10.
7. Naqvi AG, Malik AS, Jan W. Necrotizing fasciitis of the lower extremity: A case report and current concept of diagnosis and management. *Scand J Trauma Resusc Emerg Med* 2009;17:1-7.
8. Yang B, Connolly S, Ball W. Necrotizing fasciitis of the breast: A rare primary case with conservation of the nipple and literature review. *JPRAS* 2015;6:15-9.