

Recurrent palmar erythematous plaques with pseudovesicles: Sweet's syndrome affecting palms only

Arun Inamadar 

Department of Dermatology,
Venereology & Leprosy, Shri BM
Patil Medical College, Vijayapur,
Karnataka, India

Correspondence to

Dr Arun Inamadar;
aruninamadar@gmail.com

Accepted 5 May 2022

DESCRIPTION

A woman in her 40s presented with eruptions mainly on the hands. The lesions were painful large erythematous plaques with oedematous skin looking like 'psuedovesicles' over palmar aspects of both the hands ([figure 1](#)). The patient also had joint pain. There was history of such episodes since 1 year and partial relief with treatment offered by different consultants. Lesions were associated with mild febrile episodes. Complete haemogram revealed neutrophilia, raised ESR and normal serology for ANA screening. Biopsy for histopathology study revealed infiltration of the dermis, predominantly by neutrophils. A diagnosis of neutrophilic dermatosis was made without any clearly discernible distinction between Sweet's syndromes. Once the treatment with dapsone was started the lesions subsided within a week time ([figure 2](#)).

Sweet's syndrome is a reactive dermatosis characterised by sudden onset of fever, leukocytosis and raised erythematous plaques infiltrated with neutrophils. The diagnosis of Sweet's syndrome was based on a set of criteria that requires the presence of two major and at least two minor criteria.¹ In the index both the major criteria (abrupt onset of tender erythematous plaques and nodules with pseudovesicles and predominantly neutrophilic dermal infiltrate without leukocytoclastic vasculitis) plus minor criterion (raised total leucocyte count, neutrophilia, raised ESR and fever) were present.

Usually the dorsa of the hands are frequently affected, the palmar involvement in the index case appears to be unusual. There are very few reports of palmoplantar involvement.²⁻⁴ Rare presentation and dramatic response to benign treatment with dapsone is the reason to report this index case.

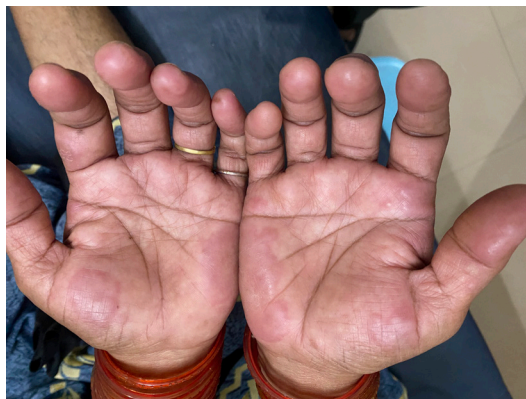

Figure 1 Erythematous plaques over both palms with few lesions over digits showing oedema (pseudovesicles).

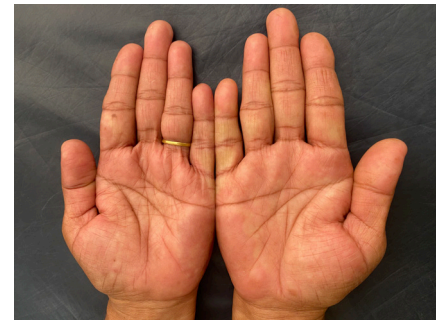


Figure 2 Complete clearance of lesions after a week treatment with dapsone.

Learning points

- ▶ This case highlights the difficulties in clearly distinguishing forms of neutrophilic dermatosis, adding to the notion of a continuum in neutrophilic disease.
- ▶ Although the dorsa of the hands are frequently affected, the palmoplantar involvement appears to be unusual.
- ▶ 'Pseudovesicles' should point out towards ruling out Sweet's syndrome.

Contributors Dr AI is sole author in planning, data collection, manuscript writing of the case.

Funding The authors have not declared a specific grant for this research from any funding agency in the public, commercial or not-for-profit sectors.

Competing interests None declared.

Patient consent for publication Consent obtained directly from patient(s).

Provenance and peer review Not commissioned; externally peer reviewed.

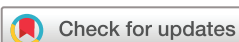Case reports provide a valuable learning resource for the scientific community and can indicate areas of interest for future research. They should not be used in isolation to guide treatment choices or public health policy.

ORCID iD

Arun Inamadar <http://orcid.org/0000-0002-8877-3723>

REFERENCES

- 1 von den Driesch P. Sweet's syndrome (acute febrile neutrophilic dermatosis). *J Am Acad Dermatol* 1994;31:535-56.
- 2 Sommer S, Wilkinson SM, Merchant WJ, et al. Sweet's syndrome presenting as palmoplantar pustulosis. *J Am Acad Dermatol* 2000;42:332-4.
- 3 Brajon D, Cuny JF, Barbaud A. Dermatosé neutrophilique des mains [Neutrophilic dermatosis of the hands]. *Ann Dermatol Venerol* 2011;138:673-6.
- 4 Bubna AK, Veeraraghavan M, Anandan S, et al. Palmoplantar Pseudovesicles: an unusual presentation of sweet's syndrome. *Indian J Dermatol* 2015;60:94-6.



© BMJ Publishing Group Limited 2022. No commercial re-use. See rights and permissions. Published by BMJ.

To cite: Inamadar A. *BMJ Case Rep* 2022;15:e250709. doi:10.1136/bcr-2022-250709

Copyright 2022 BMJ Publishing Group. All rights reserved. For permission to reuse any of this content visit <https://www.bmj.com/company/products-services/rights-and-licensing/permissions/>
BMJ Case Report Fellows may re-use this article for personal use and teaching without any further permission.

Become a Fellow of BMJ Case Reports today and you can:

- ▶ Submit as many cases as you like
- ▶ Enjoy fast sympathetic peer review and rapid publication of accepted articles
- ▶ Access all the published articles
- ▶ Re-use any of the published material for personal use and teaching without further permission

Customer Service

If you have any further queries about your subscription, please contact our customer services team on +44 (0) 207111 1105 or via email at support@bmj.com.

Visit casereports.bmj.com for more articles like this and to become a Fellow