

Content available at: <https://www.ipinnovative.com/open-access-journals>

IP International Journal of Medical Paediatrics and Oncology

Journal homepage: <https://www.ijmpo.com/>

## Case Report

# Acute ileocolitis as a presentation of Sars Cov-2 infection in children- A case report

Ranjima M Mahesh<sup>1</sup>, Raghavendra H Gobbur<sup>1,\*</sup>

<sup>1</sup>Dept. of Pediatrics, Shri B.M.Patil Medical College Hospital & research Centre, Bijapur, Karnataka, India



### ARTICLE INFO

#### Article history:

Received 16-11-2021

Accepted 13-12-2021

Available online 22-12-2021

#### Keywords:

COVID19

Ileocolitis

meningoencephalitis

cerebellar ataxia

Kawasaki disease

### ABSTRACT

As COVID-19 continues to spread in India and other countries, the impact of the disease among children, initially considered less important, is becoming more relevant. The extent of the diversity of clinical presentation of COVID-19 in children are still unclear. We have already seen a new clinical picture of SARS-CoV-2 in children manifesting as a hyper-inflammatory syndrome, with multi-organ involvement similar to Kawasaki Disease and with potential evolution to a shock syndrome. This represented a new phenomenon affecting previously asymptomatic children with SARS-CoV-2 infection. COVID-19 may also manifest as viral hepatitis, acute pancreatitis, acute liver injury, acute kidney injury, ARDS, Sepsis, septic shock and meningo-encephalitis and cerebellar ataxia. The Multisystem Inflammatory Syndrome in Children (MIS-C) associated with SARS-CoV-2 infection occurs weeks after infection and may evolve unnoticed. MIS-Cs pathophysiology remains unclear. However, it appears to be a postinfectious hyperimmune response that may occur during or following asymptomatic or symptomatic infection. COVID-19 infection in children may lead to a potentially life threatening condition that we may not be aware of. We are in need of reporting of the diverse presentation of SARS CoV-2 virus in children. Here we describe a case of a previously normal 14-year-old boy who manifested with severe pain abdomen after SARS CoV-2 infection and was diagnosed as Acute Ileocolitis secondary to COVID-19. Child improved with steroid therapy and was asymptomatic after 3 weeks of treatment.

This is an Open Access (OA) journal, and articles are distributed under the terms of the [Creative Commons Attribution-NonCommercial-ShareAlike 4.0 License](https://creativecommons.org/licenses/by-nc-sa/4.0/), which allows others to remix, tweak, and build upon the work non-commercially, as long as appropriate credit is given and the new creations are licensed under the identical terms.

For reprints contact: [reprint@ipinnovative.com](mailto:reprint@ipinnovative.com)

## 1. Introduction

SARS-CoV-2 is a new virus that is responsible for COVID-19, a global pandemic that has already claimed the lives of almost half a billion people. SARS CoV-2 is known to cause gastrointestinal problems in children like diarrhea, vomiting, abdominal pain, hepatitis, pancreatitis<sup>1</sup> etc. Here we report a novel case of SARS CoV-2 virus causing acute severe ileocolitis in a 14-year-old child. Diffuse inflammatory infiltrates of the submucosa of a segment of the intestine characterize the inflammation of the alimentary tract.<sup>2</sup> The inflammatory response could spread to the serosal membrane and Peritonitis, or septicemia may also

develop post infection with the virus.<sup>3</sup>

## 2. Case Presentation

A 14-year-old previously healthy child presented to pediatric OPD with complaints of on and off abdominal pain for 2 weeks. Diffuse, dull-aching intermittent pain, mild to moderate in intensity, 3-4 episodes per day, each episode lasting for 5-10 minutes, aggravated after having food. No fever. No nausea. No vomiting. No loose stools. No H/O burning micturition. No chronic cough. No H/O gastrointestinal disease or weight loss. On clinical examination child was afebrile, temperature 98°F, RR-18/min, PR- 84/min, BP-110/70 mm, SpO<sub>2</sub>-99%. Child was conscious and alert. There was no throat

\* Corresponding author.

E-mail address: [ranjima.ranjan@gmail.com](mailto:ranjima.ranjan@gmail.com) (R. H. Gobbur).

congestion, no lymphadenopathy, no edema. The heart rate and rhythm were normal. Normal vesicular breath sounds heard bilaterally without added sounds. The abdomen was soft, not distended, non-tender, no organomegaly. The clinical possibilities considered were chronic appendicitis, chronic pancreatitis, abdominal tuberculosis, viral hepatitis, enterocolitis and COVID infection.

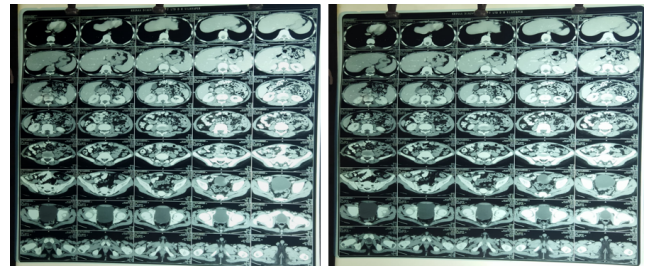
### 2.1. Evaluation during hospitalization

Blood work revealed evidence of inflammation including elevated C-reactive protein, erythrocyte sedimentation rate, procalcitonin, d-dimer, ferritin, and neutrophils, and reduced lymphocyte. Infectious evaluation was positive for COVID-19.

The initial investigations were as follows-Total leukocyte count-8980, neutrophils-69%, lymphocytes- 18%, platelet count-5.3 lakh, hemoglobin-8.8, PCV-28.8, CRP-16.9(>10-positive), D-Dimer-279, COVID- IgM and IgG- Positive. IgM- 2.5 and IgG- 1.8 (>1 Positive), HIV, HBsAg- negative, urine routine-normal. Peripheral smear showed microcytic hypochromic anemia with thrombocytosis. CBNAAT of gastric aspirate was done to rule out abdominal tuberculosis-reported negative. Chest x-ray was normal. USG abdomen and pelvis showed caecum and terminal ileal loop wall thickening and adjacent mesenteric lymphadenopathy, possibly enterocolitis. CT scan of abdomen showed diffuse wall thickening of right ileocolic junction and distal ileum with adjacent discrete lymph nodes.

**Table 1:** Laboratory results

Characteristics	Reported Values
White blood cell count	8980
Neutrophil count	69
Lymphocyte count	18
Hemoglobin	8.8
PCV	28.8
Platelet count	5.1Lakhs
RDW	18.4
MCV	69.7
MCH	21.3
MCHC	30.6
C-Reactive Protein	17
ESR	21
D-Dimer	279
Serum ADA	38
Serum creatinine	0.4
Serum calcium	8.6
Dengue NS1, IgM, IgG	Negative
HIV	Negative
HBsAg	Negative
Hepatitis A virus spot test	Negative
SARS CoV-2 Antibody IgM	Positive
SARS CoV22 Antibody IgG	Positive



**Fig. 1:** CT scan of abdomen showing diffuse wall thickening of right ileocolic junction and distal ileum

### 2.2. Treatment

Considering the clinical findings, blood investigation reports and ultrasonography findings, child was treated with intravenous fluids maintenance and intravenous ofloxacin and metronidazole injection for 5 days. Child was also started on steroids, Tab. prednisolone 2mg/kg/day was given for 2 weeks. After the initiation of steroids child showed improvement and got discharged on 8<sup>th</sup> day. Child was asymptomatic at 2 weeks follow-up visit.

### 3. Discussion

Inflammation of the alimentary tract is a unique presentation of the novel SARS-CoV-2 virus. Historically, this inflammation is hypothesized to be of bacterial origin, but its portal of entry and the pathogenesis remains unclear.<sup>3</sup> Our patient did not report any chronic gastrointestinal symptoms, and stool studies were also normal. Mimics of inflammatory bowel disease (IBD) include not only infectious causes of colitis, but also vascular diseases, radiation-related injuries, drug induced inflammation, and monogenic disorders in very-early-onset refractory IBD. A superinfection with cytomegalovirus or *Clostridium difficile* can aggravate intestinal inflammation in IBD, especially in patients who are immunocompromised.<sup>4</sup> Our patient had a negative comprehensive infectious evaluation (Table 1), except for positive COVID-19 IgM and IgG which indicated a COVID infection that lead to the presentation. This case highlights the rare presentation of COVID-19 in which child presented only with on and off abdominal pain and was diagnosed as COVID-19 associated ileo colitis.

The SARS-CoV-2 virus is an enveloped, single-stranded virus, and the angiotensin-converting enzyme 2 (ACE2) receptor is considered as the major receptor for the viral spike protein and critical for infectivity.<sup>2</sup> The ACE2 protein is found at high levels in the colon, biliary system, and liver, and viral RNA shedding occurs in the GI tract.<sup>4</sup> These data indicates that the SARS-CoV-2 may have tropism for the GI tract and liver, and they can be the sites of active viral replication causing either direct or indirect tissue injury.<sup>4</sup>

#### 4. Conclusion

COVID-19 added another dimension to gastro-intestinal diseases. The primary clinical manifestation of COVID-19 infection in children is not necessarily a pulmonary disease in all cases. The involvement of multiple organ systems, including the gastrointestinal (GI) tract, liver, and pancreas are also common.<sup>3</sup> This is one of the rare, reported case of ileocolitis secondary to asymptomatic COVID-19 infection. It is prudent for pediatricians and pediatric gastroenterologists during the COVID-19 era to be aware of this unique presentation of the novel virus to avoid unnecessary invasive surgical intervention in cases of acute abdomen presentation in children. Given the ongoing emergency of GI manifestations of the disease, a high index of suspicion should be kept for COVID-19 in all children presented with GI symptoms.

#### 5. Conflict of Interest

The author declares no potential conflicts of interest with respect to research, authorship, and/or publication of this article.

#### 6. Source of Funding

None.

#### References

1. Balasubramanian S, Rao NM, Goenka A, Roderick M, Ramanan AV. Coronavirus Disease 2019 (COVID-19) in Children - What We Know So Far and What We Do Not. *Indian Pediatr.* 2020;57(5):435–42.
2. Matsuda EM, Santos S, Castejon MJ, Ahagon CM, Campos IB, Brígido L, et al. COVID-19 in children: a case report of Multisystem Inflammatory Syndrome (MIS-C) in São Paulo, Brazil. *The Brazilian journal of infectious diseases: An official publication of the. Braz J Infect Dis.* 2020;24(6):580–2. Available from: <https://doi.org/10.1016/j.bjid.2020.09.002>.
3. Li Y, Li C, Wang J, Zhu C, Zhu L, Ji F, et al. A case series of COVID-19 patients with chronic hepatitis B virus infection. *J Med Virol.* 2020;92(11):2785–91. doi:10.1002/jmv.26201.
4. Zou X, Fang M, Li S, Wu L, Gao B, Gao H, et al. Characteristics of Liver Function in Patients With SARS-CoV-2 and Chronic HBV Coinfection. *Clin Gastroenterol Hepatol.* 2021;19(3):597–603. doi:10.1016/j.cgh.2020.06.017.

#### Author biography

**Ranjima M Mahesh**, Post Graduate

**Raghavendra H Gobbur**, Professor and Unit Chief

**Cite this article:** Mahesh RM, Gobbur RH. Acute ileocolitis as a presentation of Sars Cov-2 infection in children- A case report. *IP Int J Med Paediatr Oncol* 2021;7(4):218-220.