

Unusual presentation of fungal keratitis with endothelial plaque

Rekha Ramesh Mudhol , Nikhita Anil Sankolli 

Shri B M Patil Medical College Hospital and Research Centre, Department of Ophthalmology, BLDE Deemed to be University, Vijayapura, Karnataka, India

Correspondence to
Dr Nikhita Anil Sankolli;
nikhit1995@gmail.com

Accepted 23 August 2022

DESCRIPTION

Fungal keratitis manifests clinically as epithelial ulcer, pseudopodia, corneal immune ring, hypopyon and endothelial plaque.¹ It is an uncommon presentation that indicates severe infection with penetration of fungal elements into the anterior chamber.²

A man in his 30s visited the outpatient department following trauma to the right eye with sugarcane leaf 4 days ago while working on the farm. He presented with redness, watering, throbbing pain and blurred vision in the right eye. He did not have any comorbidity. The best corrected visual acuity was 6/18. On slit-lamp examination, we noted circumciliary congestion, 6×4 mm white stromal infiltration situated paracentrally extending to the periphery at six o'clock with feathery margins, and three satellite lesions peripheral to the lesion. It was associated with 1×2 mm endothelial plaque. There was no epithelial defect on fluorescein staining. The surrounding corneal stroma revealed mild keratitis (figures 1 and 2).

Based on clinical evaluation and KOH (Potassium hydroxide) mount report, fungal keratitis with endothelial plaque was diagnosed. He was treated with oral Itraconazole 100 mg two times per day, topical Natamycin 0.5% eye drops, Voriconazole 1% eye drops and Homatropine 2% eye drops. The patient was followed up every day for 3 days and later for 1 week; during these follow-ups, clinical reduction in the size of infiltrate and stromal oedema (figure 3) attests to it. At 1-month

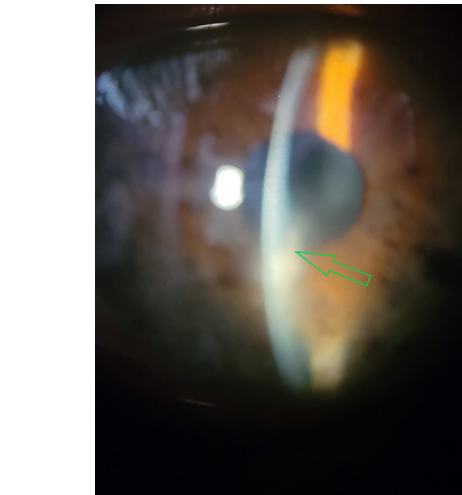


Figure 2 Slit-lamp microscopic image of the right eye taken at presentation showing endothelial plaque (green arrow).

follow-up, the patient was completely asymptomatic, with improvement in vision to 6/9 was noted with the presence of macular grade opacity measuring 2×3 mm paracentrally at six o'clock position (figure 4).

Fungal corneal ulcers are expected to be prevalent more in areas where agriculture is the principal occupation among the population.³ Goel *et al* concluded that sugarcane injuries are more common among farmers.⁴ Krishnaiah *et al*, in their study, found that injury with vegetable matter such as a thorn, branch of a tree, plant secretion, etc (45.3%) was the primary cause of trauma reported in fungal keratitis.⁵ Qi *et al* found that endothelial plaques signify hyphae-infiltrating Descemet's membrane, which is usually associated with poor response to medical treatment and worsening visual

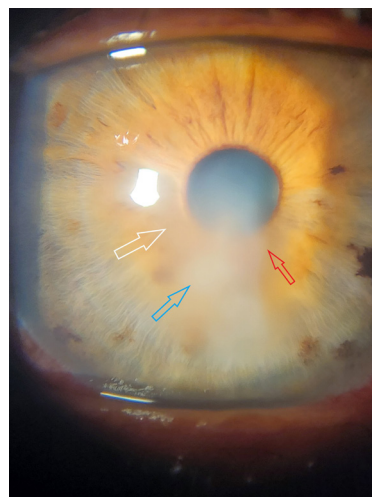


Figure 1 Slit-lamp microscopic image of the right eye taken at presentation showing 6×4 mm white stromal infiltrate (blue arrow) with feathery margin (red arrow) and satellite lesion (white arrow).

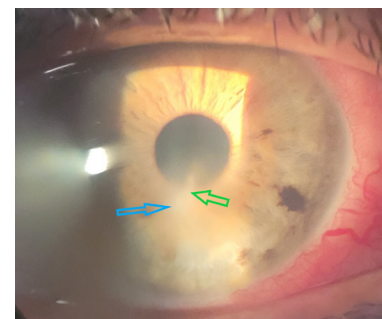
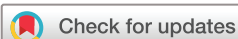

Figure 3 Image taken at 1-week follow-up showing a remarkable reduction in stromal infiltrate (blue arrow) and endothelial plaque (green arrow).



© BMJ Publishing Group Limited 2022. No commercial re-use. See rights and permissions. Published by BMJ.

To cite: Mudhol RR, Sankolli NA. *BMJ Case Rep* 2022;**15**:e252212. doi:10.1136/bcr-2022-252212

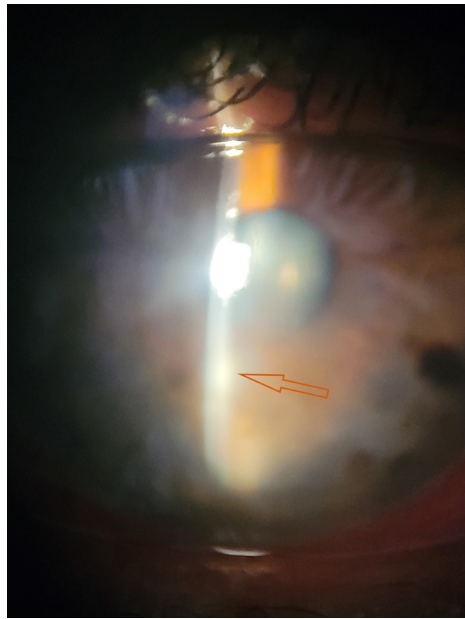


Figure 4 Image taken at 1-month follow-up showing 2×3 mm paracentral macular grade opacity (orange arrow).

prognosis.⁶ Endothelial plaque is an uncommon presentation more specifically related to fungal keratitis, with 7.5% in a study by Upadhyay *et al.* It requires aggressive treatment and surgical intervention. It is associated with poor visual prognosis.^{6,7} The newer modalities in diagnosing endothelial plaques are anterior segment optical coherence tomography and *in vivo* confocal microscopy.⁸ In the present study, we identified endothelial plaque by slit-lamp examination. The aggressive topical medication helped early healing of keratitis with minimal residual opacity.

Hence, we conclude that this is an uncommon case of fungal keratitis with an endothelial plaque and no epithelial defect, which showed remarkable improvement without surgical intervention.

Contributors RRM was involved in clinical evaluation, investigation and management. NAS was involved in literature search and drafting the manuscript.

Funding The authors have not declared a specific grant for this research from any funding agency in the public, commercial or not-for-profit sectors.

Competing interests None declared.

Patient consent for publication Obtained.

Provenance and peer review Not commissioned; externally peer reviewed.

Case reports provide a valuable learning resource for the scientific community and can indicate areas of interest for future research. They should not be used in isolation to guide treatment choices or public health policy.

Patient's perspective

Prior to being injured by a sugarcane leaf while working on the farm four days ago, my vision had been quite stable. However, after the injury, I experienced redness, wetness, pain, and blurred vision. This affected my day-to-day operations. I consulted the ophthalmologists, who informed me that I have an uncommon infection presentation that needs fast and rapid treatment. I adhered completely to the recommendations and followed up frequently. My vision had much improved during the follow-up appointment after a month, and I could now perform my everyday tasks with ease. I've been told to use safety glasses in order to avoid similar situations in the future.

Learning points

- ▶ The early presentation of an endothelial plaque, which is a definite sign of fungal keratitis, can help ophthalmologists to suspect fungal keratitis.
- ▶ The presentation of an endothelial plaque indicates the need for aggressive treatment to prevent vision-threatening complications of fungal keratitis.
- ▶ Sugarcane leaf injury is commonly associated with fungal keratitis, and a detailed assessment of the patient can help in the early diagnosis and treatment.

ORCID iDs

Rekha Ramesh Mudhol <http://orcid.org/0000-0002-7262-0175>

Nikhita Anil Sankolli <http://orcid.org/0000-0003-4344-0762>

REFERENCES

- 1 Jongkhajornpong P, Nimworaphan J, Lekhanont K, *et al.* Predicting factors and prediction model for discriminating between fungal infection and bacterial infection in severe microbial keratitis. *PLoS One* 2019;14:e0214076.
- 2 Takezawa Y, Suzuki T, Shiraishi A. Observation of retrocorneal plaques in patients with infectious keratitis using anterior segment optical coherence tomography. *Cornea* 2017;36:1237–42.
- 3 Ravinder K, Madhav MV, Archana J. Clinical evaluation of corneal ulcer among patients attending teaching hospital. *Diabetes* 2016;6:7–5.
- 4 Goel R, Malik KPS, Goel A, *et al.* Agriculture related corneal injuries. *Nep J Oph* 2013;5:45–9.
- 5 Krishnaiah S, Nirmalan PK, Shamanna BR, *et al.* Ocular trauma in a rural population of southern India: the Andhra Pradesh eye disease study. *Ophthalmology* 2006;113:1159–64.
- 6 Qi X, Liu T, Du M, *et al.* Endothelial plaques as sign of Hyphae infiltration of descemet's membrane in fungal keratitis. *J Ophthalmol* 2020;2020:1–6.
- 7 Upadhyay P, Gupta N, Bahadur H. Study of clinico-etiological profile of fungal keratitis in tertiary care hospital in North India. Available: Researchgate.net
- 8 Ang M, Baskaran M, Werkmeister RM, *et al.* Anterior segment optical coherence tomography. *Prog Retin Eye Res* 2018;66:132–56.

Copyright 2022 BMJ Publishing Group. All rights reserved. For permission to reuse any of this content visit <https://www.bmj.com/company/products-services/rights-and-licensing/permissions/>
BMJ Case Report Fellows may re-use this article for personal use and teaching without any further permission.

Become a Fellow of BMJ Case Reports today and you can:

- ▶ Submit as many cases as you like
- ▶ Enjoy fast sympathetic peer review and rapid publication of accepted articles
- ▶ Access all the published articles
- ▶ Re-use any of the published material for personal use and teaching without further permission

Customer Service

If you have any further queries about your subscription, please contact our customer services team on +44 (0) 207111 1105 or via email at support@bmj.com.

Visit casereports.bmj.com for more articles like this and to become a Fellow