

How to Cite:

Inginshetty, N. M., Bulagond, A., Bagewadi, R. M., Rajesh, G., & Venkat, M. (2022). Surgical management of intertrochanteric fractures of femur with Proximal Fixation Nail Anti-Rotation-II. *International Journal of Health Sciences*, 6(S5), 11100–11110.
<https://doi.org/10.53730/ijhs.v6nS5.11995>

Surgical management of intertrochanteric fractures of femur with Proximal Fixation Nail Anti-Rotation-II

Nagesh M Inginshetty

Senior Resident, Department of Orthopedics, BLDE, Deemed to be University, Shri B M Patil Medical College Hospital and Research Centre, Vijayapura

Anil Bulagond

Associate Professor, Department of Orthopedics, BLDE, Deemed to be University, Shri B M Patil Medical College Hospital and Research Centre, Vijayapura

R M Bagewadi

Assistant Professor, Department of Orthopedics, BLDE, Deemed to be University, Shri B M Patil Medical College Hospital and Research Centre, Vijayapura

G Rajesh*

Assistant Professor, Department of Orthopedics, BLDE, Deemed to be University, Shri B M Patil Medical College Hospital and Research Centre, Vijayapura
Corresponding author email: rajeshreddyc605@gmail.com

Mallipudi Venkat

Junior Resident, Department of Orthopedics, BLDE, Deemed to be University, Shri B M Patil Medical College Hospital and Research Centre, Vijayapura,

Abstract---Background: Intertrochanteric Femur Fractures are usually complicated with associated co-morbidities like osteoporosis, diabetes, hypertension, renal failure. In such circumstances, nonoperative treatment is mainly reserved for poor medical candidates and non-ambulant patients with minimal discomfort after fracture. Objective: To study the management of intertrochanteric fractures with proximal femoral nail anti-rotation-II. Material and Methods: Present study was conducted on the patients admitted in at BTGH attached to MR medical college, Kalburgi & Shri B M Patil Medical College Hospital and Research Centre, Vijayapura, with diagnosis of intertrochanteric fractures from October 2017 to April 2019. A total of 21 cases were taken in our study. Results: Majority of the cases i.e., 12(60%) were in the age group of 61- 80 years, followed by 3 cases in the age group 41-60 years. The mean age was 69 years. Majority of the patients were males 13 (65%) and 7 (35%) were females. We took less

number of exposures time in case of comminuted fractures where reduction was not a problem. Blood loss was more in open reductions. The HARRIS HIP SCORE grading was done and 2 patients were graded excellent, 16 as good, 2 as fair and none as poor. Conclusion: PFN A-II is a significant advancement in the treatment of trochanteric fractures which has the unique advantage of closed reduction, preservation of fracture hematoma, minimal soft tissue damage during surgery, early rehabilitation, and early return to work.

Keywords--Intertrochanteric fractures, Harris Hip Score, Proximal femoral nail Anti-rotation-II.

Introduction

Fracture is one of the most devastating injuries in the elderly. The incidence of these fractures increases with advancing age.¹ These patients are more limited to home ambulation and are dependent in basic and instrumental activities of daily living. 50% of fracture around hip patients in elderly is of trochanteric fracture and these 50% of fracture are unstable type of trochanteric fractures. Today operative treatment has largely replaced conservative measures and the goal of treatment is to achieve accurate or acceptable. Anatomical and stable reduction with rigid internal fixation in order to achieve early mobilization of patients and prevent complications of prolonged recumbence. Despite marked improvements in implant design, surgical technique and patient care, intertrochanteric fractures continue to consume a substantial proportion of our healthcare resources and remain a challenge to date.² Complications with intertrochanteric fractures arise primarily from fixation rather than union or delayed union. because the intertrochanteric area is made up of cancellous bones.³

Among all these factors, surgeon can only control the quality of the reduction, choice of implant and its placement. There is a wide variety of treatment options for these fractures. The sliding hip screw device has been used for more than a decade for the treatment of these fractures which may not be an ideal implant in all cases.^{4,5}

Although PFN is more popular implant, it comes with its own set of disadvantages, where it has two screws comparing to PFNA-II which has got only one helical blade and other disadvantages are z effect and reverse z effect. PFNA-II utilizes a helical blade instead of the conventionally used two screws. The helical blade is believed to provide stability, compression as well as rotational control of the fracture. Theoretically it compacts the bone during insertion into the neck and hence has higher cut out strength as compared to other devices. The differences are that mediolateral angle is reduced from 6 degrees to 5 degrees. Hence there is less chance of implant failure especially in elderly, osteoporotic bones.

Thus, PFN Anti-rotation-II is a modification of the conventional PFN which reduces even the minimal complications associated with Conventional PFN, also providing additional advantages.

Material and Methods

The present prospective study was obtained from the patients admitted in at BTGH attached to MR Medical College, Kalburgi & Shri B M Patil Medical College Hospital and Research Centre, Vijayapura, with diagnosis of intertrochanteric fractures from October 2017 to April 2019. 21 cases were taken in our study and the patients were informed about the study in all respects and informed consent was obtained from each patient.

After the patient with intertrochanteric fracture was admitted to hospital all the necessary clinical details were recorded in proforma prepared for this study. After the completion of the hospital treatment patients were discharged and called for follow up at outpatient level, at regular intervals for serial clinical and radiological evaluation.

Inclusion criteria:

- Adult patients aged more than 18 years.
- Fractures of the proximal femur with fracture line running along the intertrochanteric line with or without comminution with an intact lateral wall
- Unstable fractures with reverse obliquity
- Unstable fractures with posteromedial comminution

Exclusion criteria:

- Osteoarthritis changes of hip prior to injury.
- Patients less than 18 years of age.
- Lateral wall comminution
- Any other fracture of bone in an ipsilateral limb
- Medically unfit patients

Immobilization of affected extremity in BB splint by skin traction and if surgery is delayed then skeletal traction is used.

Management of associated injuries to vital organs like chest, abdomen head injury etc. After stabilization of vitals radiographs of the affected extremities were carried out. The fracture pattern was grouped according to classification/inclusion criteria.

Patients admitted with intertrochanteric fracture were examined and investigated with X-ray of pelvis with both hips AP and Lateral view (whenever possible)

Blood and urine examinations were ordered

Serum Creatinine

Urine: Albumin, Sugar, Microscopic examination

X-ray: Pelvis with both hips AP view, Involved hip with femur AP and Frog leg views

Chest X ray PA view in necessary patients.

All the patients were evaluated for associated medical problems and were referred to respective department and treated accordingly. Associated injuries were evaluated and treated simultaneously. The patients were operated on elective basis after overcoming the avoidable anaesthetic risks. Specific investigations of all associated medical illness were carried out. Preop anaesthetic fitness & physician fitness done. Adequate blood reserved in bloodbank. Shaving of affected

extremity, written informed consent of patient & relatives for internal fixation taken. All the patients were kept fasting overnight. Study of fracture anatomy was done according to classification. Clinical and radiological measurement of proper nail size was carried out. Indwelling urinary catheterization was done either pre op or post op.

Pre op planning

1. Determination of nail diameter: Nail diameter was determined by measuring diameter of the femur at the level of isthmus on an AP X ray.
2. Determination of the neck shaft angle: Neck shaft angle was measured in unaffected side in AP X ray using goniometer.
3. Length of the nail: A standard length of 170mm was used in all our cases.

Implant details

Proximal femoral nail anti-rotation-II consists of 11mm helical blade with internal locking system, 4.9mm distal locking screw and an end cap. Proximal femoral nail anti-rotation-II is made up of titanium alloy which comes in following sizes.

1. Length: Standard PFNA-II- 170,240 mm, Long PFNA-II- 260-420 mm
2. Diameter: 9, 10,11,12 mm
3. Neck shaft angle range: 130, 135 degrees.

The nail is having 16.5 mm proximal diameter. This increases the stability of the implant. There is 5 degree mediolateral valgus angle, which prevents varuscollapse of the fracture even when there is medial comminution. The distal diameter is tapered to 9 to 12mm which also has grooves to prevent stress concentration at the end of the nail. Proximally it has 1 hole is for the insertion of the 11mm helical blade with internal locking system by which intra-operative compression can be achieved on operative table under c-arm guidance, which helps to prevent rotation. Distally nail has one hole for insertion of 4.9mm locking screws, of which can be used either for static locking or dynamic locking with the help of a jig.

In our study we used a standard length PFNA-II of 170mm with distal diameter of 9,10,11,12 mm, the proximal diameter of the nail is 16.5mm. The helical blade diameter is of 11mm. Distal locking with 4.9 mm cortical screws either in static mode or in dynamic mode. The nail is universal with 5 degrees mediolateral angulation and with a neck shaft angle of 130/135 degrees. The patient is placed in supine position on fracture table with adduction of the affected limb by 10-15 degrees and closed reduction of the fracture was done by the traction and internal rotation. The unaffected leg is flexed and abducted as far as possible or kept in wide abduction. The image intensifier was positioned so that anterior-posterior and lateral views of hip and femur could be taken. Open reduction is performed if closed reduction failed. The patient is then prepared and draped as for any standard hip fracture fixation Prophylactic antibiotic is given in all patients 30mins before surgery.

Approach

The tip of greater trochanter was located by palpation in thin patients and in obese patients, we used image intensifier. 5cms longitudinal incision was taken proximal from the tip of the greater trochanter. A parallel incision was made in fascialata and gluteus medius was split in line with the fibres. Tip of greater trochanter is exposed, in unstable fractures stabilization of fracture is achieved by two 3mm k-wires placed in anterior and posterior part of neck.

Determination of entry point and insertion of guide wire

In AP view on c-arm, the entry point is on tip or slightly lateral to the tip of greater trochanter. In lateral view, guide wire position is confirmed in the center of the medullary cavity. Medullary canal entered with a curved bone awl, the guide wire is inserted into the medullary canal.

Reaming

After confirmation of correct placement of guide wire, entry reaming can be done for easier passage of nail. Using a cannulated flexible reamer proximal femur is reamed in increments of 0.5mm upto 1mm greater than nail diameter starting from 8mm diameter.

Insertion of nail

After confirming satisfactory fracture reduction, an appropriate size nail as determined preoperatively is assembled to insertion handle and inserted manually. This step is done carefully without hammering by slight twisting movements of the hand until the hole for helical blade is at the level of lesser trochanter. Open reduction is performed in case satisfactory reduction is not possible by closed means.

Insertion of the guide wire for helical blade

This is inserted with the help of aiming device fixed to the insertion handle. A 2.8 mm guide wire is inserted through the drill sleeve after a stab incision. This guide wire is inserted 5mm deeper than the planned screw size. The guide wire is advanced in to the femoral head at least 4mm superior to the calcar to a level 10mm below the sub chondral bone. The final position of the guide wire should be in the lower half of the neck in AP view and in the center of the neck in lateral view.

Insertion of the Helical Blade

Drilling is done over 2.8mm guide wire with lateral cortex reamer, then with the help of conical reamer it is reamed until subchondral level then with the help of depth gauge length is measured after maintaining TAPD distance, then unlocked helical blade is mounted on to the screw driver then it is inserted into the femoral neck and head over the guide wire then its position is confirmed under C-ARM guidance, and finally after reaching satisfactory position the unlocked helical

blade now will be locked by turning the screw driver towards clockwise direction visualizing under C- ARM. At the end of locking of the helical blade the screw driver will automatically fall off.

Distal locking

Distal locking is usually performed with one cortical screw. A drill sleeve system is inserted, mounted onto the jig through a stab incision. A drill hole is made with 4mm drill bit through both cortices. Locking screw is inserted and position confirmed with image intensifier.

Closure

After fixation is over, lavage is given using normal saline and incision is closed in layers. Suction drain is used in case open reduction is performed. Sterile dressing applied over wound and compression bandage given. Post operative protocol was followed

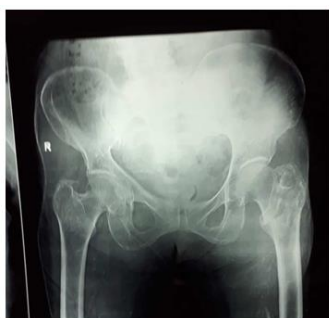Discharge

Patients were discharged from the hospital when they were able to ambulate independently with or without walking aids.

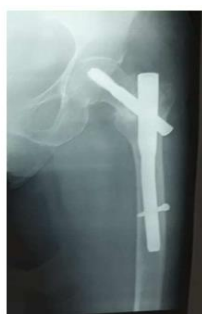Follow up

Clinical follow up at 6 weeks, 3 months, 6 months, regarding disability and functional outcome. At every visit patient was assessed clinically regarding hip and knee function, walking ability, fracture union, deformity and shortening. X-ray of the involved hip with femur was done to assess fracture union and implant bone interaction.

Case1-76Yearold female, Inter-Trochanteric Fracture



Preop x-ray



3months postop



Clinical photos

Results

Majority of the cases i.e., 12(60%) were in the age group of 61- 80 years, followed by 3 cases in the age group 41-60 years. The youngest patient was 21 years and eldest patient was 85 years. The mean age was 69years. In the present series,

males were more commonly involved. Majority of the patients were males 13 (65%) and 7 (35%) were females. 13 cases (43.3%) affected were due to slip and fall.

Table 1: Mode of Injury

Mode Of Injury	Number of cases	Percentage
Road traffic student (RTA)	2	10%
Trivial fall	18	90%

Table 2: Boyd and Griffin classification

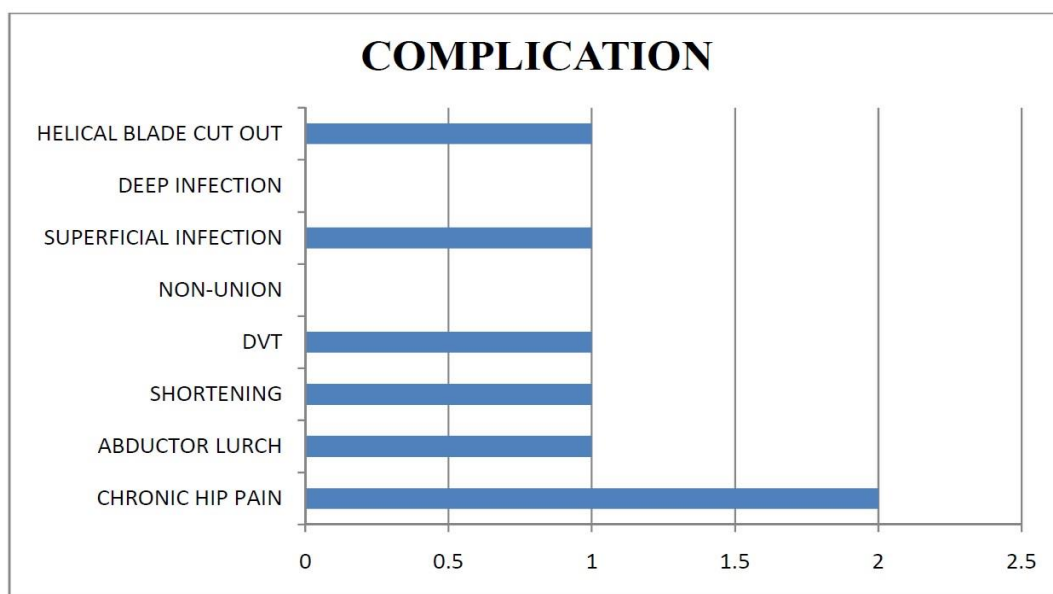
Type of fracture	Number of cases	Percentage
Type 1	5	13.3%
Type 2	9	66.7%
Type 3	3	10%
Type 4	3	10 %

In our study, we considered various intraoperative parameters such as duration of radiographic screening- more number of C-ARM exposure in case of comminuted fractures with difficult reduction. We took less number of exposures time in case of comminuted fractures where reduction was not a problem. Blood loss was more in open reductions (counted by soaked mops)

Table 3: Intraoperative details

Mean duration of screening (in shots)	23.5
Mean duration of operation (in minutes)	54.25
Mean blood loss (in milliliters)	117

The complications which occurred in the study and the number of patients affected are charted below. Superficial infection occurred in 1 female patient which resolved with antibiotics, abductor lurch occurred in 1 female and 1 male patient long term hip pain occurred in 2 patients (female-2). 1 case of helical screw cut-out in female due to severe osteoporotic and she was advised for revision surgery but patient refused for surgery and 1 case of DVT it was managed by conservative, there were no case of revision surgery, malunion, non-union or deep infection in our study.



Graph 1: Distribution of Complications

Patients were evaluated clinically and radiologically at 6 weeks, 3 months, and 6 months. During follow up the Harris Hip Score was evaluated at 3 months and 6 months post operatively. Various parameter like pain, limp, use of support, distance walked, stair climbing, sitting, absences of deformity, range of motion were evaluated using Harris HipScore. The HARRIS HIP SCORE grading was done and 2 patients were graded excellent, 16 as good, 2 as fair and none as poor.

Table 4: Harris HIP Score

	No. of cases	Percentage
Excellent	2	2%
Good	16	80%
Fair	2	2%
Poor	0	0%

Table 5: Summary of Results

Average Operating Time	54.25 min
Average Blood Loss	117 ml
Abductor Lurch	1 case
Post-op hip pain	2
Helical blade cut-out	1
Average Fracture Union	14.1 weeks
Average Image Intensifier shots	23.5 Shots
Average Harries Hip score at 6months	83.9

Discussion

PFN A-II is an effectively designed intramedullary load – sharing device. It incorporates the principles and theoretical advantages of the Zicker Nail, Dynamic hip screw locked intramedullary nail, with modifications for Asian population. Biomechanically PFN A-II, just like the conventional PFN, is stiffer, it has shorter moment arm i.e., from the tip of helical blade to the center of femoral canal whereas the DHS has a longer moment arm undergoes significant stress on weight bearing and hence higher incidence of Lag screw cut out and varusmalunion. The larger proximal diameter (16.5 mm) of the PFN A-II compared with PFN (15 mm) gives additional stiffness to the nail. Minimal blood loss, shorter operative time, early weight bearing, less chances of implant failure, minimal fluoroscopy time, easier helical blade insertion (compared with cumbersome lagscrew and derotation screw), lesser chances of post op hip pain, better performance than any other implant in elderly osteoporotic patients are all advantage of PFN AII.

In the current study the union rate was 100%. There were no cases of preoperative and postoperative femoral fractures. There were no cases of varusmal- union. The average blood loss in patients treated with the PFN A-II nail was 117ml, ranging from 50 to 250 ml. The results were comparable with Leventkarapinar et al⁶. study. Average operating time in our series was 54.25 minutes. In our initial cases operating time was on the higher range (Range 40 – 90 min). With experience the operating time reduced. The operating time were more in. type 3 and 4 of Boyd and Griffin types compared with other types.

Results were comparable to the series of Yu.W.Zhang et. al⁷ and J Zou et.al⁸. The use of image intensifier was 23.5 shots in patients treated with the PFN, which was comparable with the above mentioned studies. In our study it ranged from 16– 34 shots. Fluoroscopy was more needed in type 3 & 4 Boyd and griffins classification. The time to union was 14.01 weeks in our study ranging from 12 to 16 weeks. This was comparable to Levent karapinar et.al.⁶ The average HARRIS HIP SCORE⁹ in our patients was 74.8 (at the end of three months) and 83.9 (at the end of six months). Most of them were graded as “good” as per HARRIS HIP SCORING. Fair scores were seen with higher age group and higher Boyd and Griffin types. Even other studies mentioned above in comparison have higher exposure fluoroscopy and greater blood loss in types 3 and 4 of Boyd and Griffin. The complications in our study included, superficial infection (which settled subsequently with Intravenous antibiotics and debridement respectively), abductor lurch, dvt, post-op Hip pain. These were also present in other studies of PFN A-II with comparable rates.

A major complication of screw cut out was reported in other studies in few cases. Two cases of helical blade cut out (out of 42 patients) was reported by Levent karapinar et al⁶. Our study had 1 case of complication screw cut out at follow up of 6 months due to severe osteoporotic. Yet, our sample size is inadequate to report this complication. There were no cases of non-union reported in our study comparable to Levent karapinar et al⁶ wherein there was no reported cases of non-union. Studies which reported non-union were highlighting those higher types (type 3 and, 4) showed tendency towards non-union.

Peroperative and postoperative Femoral fractures have been documented in patients treated with the PFN and PFN A-II. Multiple factors have been implicated like implant design and operative technique. Decreases in implant curvature, diameter, over reaming of femoral canal by 1.5 to 2mm, insertion of the implant by hand and meticulous placement of the distal locking. Screws without creating additional stress risers decreases the complication rate of femoral shaft fracture (I.B. Schipper et al 2004)¹⁰. Patients with narrow femoral canal and abnormal curvature of the proximal femur are relative contra-indications to intramedullary implants (Halder et al ¹¹1992). We have followed these recommendations in our series. Hence in our series we don't have encountered any preoperative and postoperative femoral shaft fractures. A larger cohort of patients is necessary to document the incidence of preoperative and postoperative femoral shaft fractures, which is a limitation of our study.

In short, the PFN A-II is a better implant with specific design superior to conventional PFN and with distinct advantages over other implants to treat intertrochanteric fractures. With adequate surgical technique, the advantages of the PFN A-II increases and the complication rate decreases.

Conclusion

Intramedullary nailing with the PFN A-II has distinct advantages over Conventional PFN or DHS like shorter operating time and lesser blood loss for elderly, osteoporotic unstable trochanteric fractures. Early mobilization and weight bearing is allowed in patients treated with PFN A-II thereby decreasing the incidence of bedsores, uraemia and hypostatic pneumonia. The operative time is much lower compared with other procedures which also contributes with lesser blood loss. The incidence of postoperative femoral shaft fractures, Non-union rates in PFN A-II can be reduced by good preoperative planning and correct surgical technique, adequate reaming of the femoral canal, insertion of implant and meticulous placement of distal locking screws.

References

1. Akıncı O, Akalın Y, Reisog˘lu A, Kayalı C. Comparison of long-term results of dynamic hip screw and AO 130 degrees blade plate in adult trochanteric region fractures. *Acta OrthopTraumatolTurc.* 2010;44(6):443–51.
2. Chaniago, W. F. (2021). Work culture of the government of Teluk Ambon district in providing administrative services to the community in the era of COVID-19. *International Research Journal of Management, IT and Social Sciences*, 8(6), 661-668. <https://doi.org/10.21744/irjmis.v8n6.1959>
3. Cooper, G. Campion, G. Campion, and LJ 3rd Melton. "Hip fractures in the elderly: a world-wide projection." *Osteoporosis international.* (1992): 285-289. Simmermacher RK, Bosch AM, Van der Werken C.
4. Haidukewych G, Israel A, Berry D. Reverse obliquity fractures of the intertrochanteric region of the femur. *J Bone Joint Surg Am.* 2001;83:643–50. Kashid MR et al. *Int J Res Orthop.* 2016 Dec;2(4):354-3
5. Halder SC. The Gamma nail for peritrochanteric fractures. *J Bone Joint Surg Br.* 1992;74(3):340-4.

6. Halder, S. C. "The Gamma nail for peritrochanteric fractures." *The Journal of bone and joint surgery. British volume* 74.3 (1992): 340-344.
7. Karapinar, Levent, et al. "Proximal femoral nail anti-rotation (PFNA) to treat peritrochanteric fractures in elderly patients." *European Journal of Orthopaedic Surgery & Traumatology* 22.3 (2012): 237-243.
8. Merta, I. N., & Suderana, I. W. (2020). COVID-19 pandemic handling community social and cultural sector stimulus efforts. *International Journal of Social Sciences and Humanities*, 4(3), 1-12. <https://doi.org/10.29332/ijssh.v4n3.434>
9. Pain, I. "Harris Hip Score."
10. Schipper, I. B., et al. "Treatment of unstable trochanteric fractures: randomized comparison of the gamma nail and the proximal femoral nail." *The Journal of bone and joint surgery. British volume* 86.1 (2004): 86-94.
11. Suryasa, I. W., Rodríguez-Gámez, M., & Koldoris, T. (2021). Get vaccinated when it is your turn and follow the local guidelines. *International Journal of Health Sciences*, 5(3), x-xv. <https://doi.org/10.53730/ijhs.v5n3.2938>
12. Xu YZ, Geng DC, Mao HQ, Zhu XS, Yang HL. A comparison of the proximal nail antirotation device and dynamic hip screw in the treatment of unstable peritrochanteric fracture. *J Int Med Res*. 2010;38(4):1266-75.
13. Zhang, Kairui, et al. "Proximal femoral nail vs. dynamic hip screw in treatment of intertrochanteric fractures: a meta-analysis." *Medical science monitor: international medical journal of experimental and clinical research* 20 (2014): 1628.
14. Zhou, Jia-Qian, and Shi-Min Chang. "Failure of PFNA: helical blade perforation and tip-apex distance." *Injury* 43.7 (2012): 1227-1228.