

Content available at: <https://www.ipinnovative.com/open-access-journals>

Indian Journal of Clinical and Experimental Ophthalmology

Journal homepage: [www.ijceo.org](http://www.ijceo.org)

## Original Research Article

## A profile of ocular trauma in patients attending tertiary care center, North Karnataka

Piyushi Sao<sup>1,\*</sup>, Vallabha K<sup>1</sup><sup>1</sup>Dept. of Ophthalmology, Shri B M Patil Medical College, Vijayapura, Karnataka, India

## ARTICLE INFO

## Article history:

Received 07-03-2022

Accepted 20-06-2022

Available online 06-10-2022

## Keywords:

Bett classification

Open globe injury

Close globe injury

Ocular trauma score

## ABSTRACT

**Background:** Visual deprivation is one of the most significant deficits recorded by humans. One can say ocular trauma is as old as human civilization. The ocular deformity is very evident in all facial injuries. Despite having a significant socio-economic impact, very little data is available on ocular trauma's magnitude & risk factors.

**Aims & Objective:** To investigate the distribution of ocular injuries in and around the Vijayapura District.

**Materials and Methods:** From November 2019 to April 2021, the research was carried out at Tertiary care hospital in north karnataka. A total of 100 patients attending casualty and outpatient departments with a history of both mechanical and non-mechanical trauma were included. All cases were subjected to a thorough ocular examination of the anterior and posterior regions. Investigations were conducted wherever they were required.

**Results:** Ocular trauma was more common in males (83%) and in the 20-30 year age group. In mechanical injury, close globe injuries included 18% contusion and 20% lamellar laceration. 16% were penetrating injuries, 6% were rupture, and 34% were adnexal injuries in open globe injury. 83% of cases were from a rural background, and 17% were from an urban background. Majority of patients presented within 6 hours of trauma to our center. The most commonly affected structures were the eyelid and adnexa in this study.

**Conclusion:** Road traffic accidents were the most common cause of ocular trauma. This necessitates the implementation of improved road safety measures in this region.

This is an Open Access (OA) journal, and articles are distributed under the terms of the [Creative Commons Attribution-NonCommercial-ShareAlike 4.0 License](https://creativecommons.org/licenses/by-nc-sa/4.0/), which allows others to remix, tweak, and build upon the work non-commercially, as long as appropriate credit is given and the new creations are licensed under the identical terms.

For reprints contact: [reprint@ipinnovative.com](mailto:reprint@ipinnovative.com)

## 1. Introduction

Ocular trauma is a preventable public health issue that is the leading cause of blindness in children, ophthalmic morbidity, and monocular blindness worldwide.<sup>1</sup> One in every twenty patients who visits an ophthalmologist has an eye injury.<sup>2</sup>

Ocular injury etiologies vary across nations, regions of the world, and demographic or socio-economic strata. Ocular injuries vary significantly in type and complexity. Despite causing structural and functional visual loss, ocular trauma has profound social, economic, occupational,

and medico-legal consequences. Early detection and intervention are the key to trauma management and prevention of further complications.<sup>3–5</sup> Remote trauma and difficulty acquiring an accurate history might make epidemiological investigations challenging. Prevention strategies for ocular trauma necessitate an understanding of the cause or mechanism of injury, which may allow for better resource allocation to prevent such injuries. The crux of preserving visual function in individuals with ocular damage is accurate surgery timing and the logical use of medications and surgical methods. Whether the trauma is minor or severe, in an urban or rural setting, or involving an adult or child, the patient must be medically stabilized and the eye thoroughly assessed.<sup>6,7</sup>

\* Corresponding author.

E-mail address: [piyushi.sao@gmail.com](mailto:piyushi.sao@gmail.com) (P. Sao).

## 2. Materials and Methods

This prospective cross-sectional study was carried out in a tertiary care hospital from October 2019 To April 2021. A total of 100 cases with a history of both mechanical and non-mechanical trauma attending the casualty and outpatient departments were considered. The following parameters were analyzed: sex, age, patients' occupation, residence, financial status, time of the inflicted injury, place and way of inflicting the injury, and visual acuity on admission. In addition, the type of injury was analysed, i.e., contusion, lamellar laceration, mixed, penetrating, perforating, I.O.F.B.(intra ocular foreign body), or rupture with all resulting complications. A full history of the trauma, its nature, and its circumstances was gathered.

After explaining to the patient about the study and obtaining the patient's willful consent, a standardized proforma was completed for each patient documenting the history, clinical findings, and the investigations done. Clinical examination included Visual acuity as measured by Snellen's chart, comprehensive Slit Lamp examination, and fundus examination with an indirect ophthalmoscope were all performed. Previous treatment history, pre-existing ocular disease, and associated systemic and local findings were noted. All cases of ocular trauma, including mechanical, non-mechanical, thermal, chemical, electrical, radiational, explosive injuries and injuries affecting the globe as well as orbit and adnexa, were included. Patients who were not willing to participate in the study and foreign bodies on the ocular surface were excluded from the study. Ethical clearance from the institutional ethical committee was obtained.

## 3. Observations and Results

Of the 100 cases, 23% (n=23) of ocular trauma was in the age group 20-30 years, and the least number of cases, 2% (n=2), were seen over 70 years. The pediatric age group (16 years and younger) constituted 16% (n=16) of the cases. Ocular trauma was 83% (n=83) in males and 17% (n=17) in females. 83% (n=83) of cases were from a rural background, and 17% (n=17) were from an urban background. In 47% (n=47) of cases right eye was involved, whereas in 40% (n=40) of cases left eye was affected. In 13% (n=13) of cases, both eyes were involved. There were 38% (n=38) close globe injuries, 22% (n=22) open globe injuries, and 34% (n=34) were adnexal injuries. (Figure 1) Open and close globe injuries were further divided into three zones according to B.E.T.T. classification (Birmingham eye trauma terminology). (Figure 2) Among closed globe injuries, 20% (n=20) comprised zone 1 injuries, 2% (n=2) injuries to zone 2, and 16% (n=16) zone 3. The open-globe injury involved zone 1 in 7% (n=7) of patients (corneal tear with iris prolapse) and 9% (n=9) for zones 2 (corneoscleral tear), and 6% (n=6) zone 3 (scleral tear extending beyond

equator). 54% (n=54) of Cases had ocular trauma due to road traffic accidents. There were 13% (n=13) cases of injury with a block of wood (i.e., while cutting wood for fire with an axe, a big block of wood hit the eye). (Table 1)

One case of an open-globe injury at the workplace resulted from a projectile of oxygen piston, resulting in rupture. There was no I.O.F.B., in any case. One case of open globe injury by bull gore caused zone 3 rupture injury. Another case of a ten-year-old child playing on his terrace suffered zone 2 rupture as he tripped over an iron rod protruding from the beam. (Figures 3 and 4) Out of 100 cases, eyelids were involved in 85% (n=85) cases, 69% (n=69) had conjunctival involvement, 25% (n=25) had corneal involvement, 33% (n=33) of cases had iris involvement, 8% (n=8) cases of traumatic cataracts, 4% (n=4) cases of lens drop in the vitreous and 3% (n=3) cases of traumatic lens subluxation.

R.A.P.D. (relative afferent pupillary defect) was present in 27% (n=27) of cases of ocular trauma. The presence of R.A.P.D. directly correlates with the severity of trauma and final visual outcome.

A myriad of posterior segment findings was seen in the present study. 59% (n=59) of cases had posterior segment involvement, of which 22% (n=22) had berlins oedema, 1% (n=1) had a choroidal rupture, 4% (n=4) had lens drop in vitreous, 4% (n=4) had posterior vitreous detachment, 4% (n=4) had a traumatic macular hole, 2% (n=2) had traumatic optic neuropathy, and 4% (n=4) had a retinal detachment.

In this study, 43% (n=43) cases had an OTS of 1, which is related with a 90% projected outcome of NPL (no perception of light) and P.L. (perception of light) vision (i.e., 73% for no light perception plus 17% for perception of light) and just a 3% probability of vision better than 6/60. (Table 2)

Management of these diverse cases varied profoundly. Most cases 42% (n=42) were managed conservatively with medical treatment, lid tear suturing was done for 25% (n=25) cases, corneoscleral tear suturing was done for 20% (n=20) cases and 3% (n=3) underwent enucleation. Corneal tear suturing with iris abscission, vitrectomy, lens extraction, and S.F.I.O.L. (scleral fixated intraocular lens) implantation was done for 6% (n=6) of cases.

## 4. Discussion

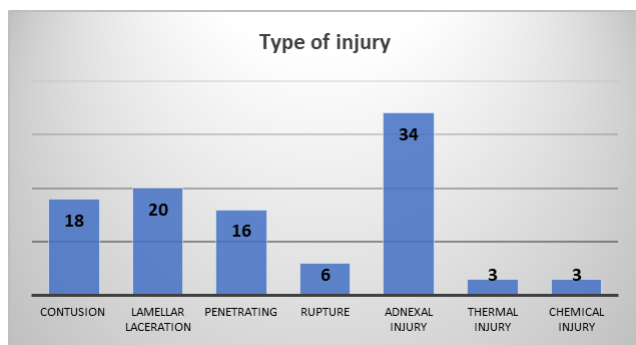
In this study, most ocular traumas occurred between 20 and 30 years because people in their second decade of life are more active and thus more vulnerable to ocular trauma. Males 83% (n=83) were more likely to sustain traumatic injuries than females due to more males involved in driving, industrial and agricultural occupations. 56% of cases presented to casualty within six hours of injury. Only 9% of cases presented after 24 hours. Patients presenting early and promptly in this region may signify better awareness of ocular trauma in the population as our hospital

**Table 1:** Objects causing trauma

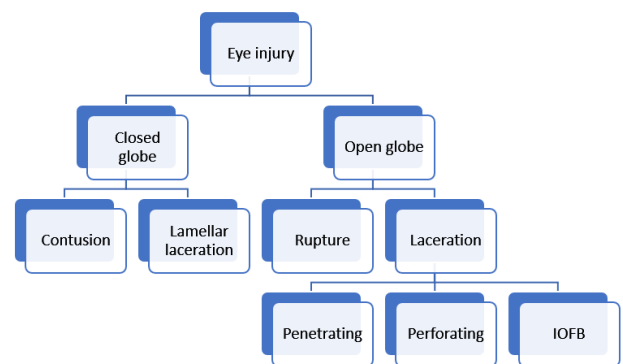
Objects	Frequency	Percent
Assault	2	2.0
Bull horn	1	1.0
Caustic lime	2	2.0
Sodium	1	1.0
Cricket ball	4	4.0
Dog bite	1	1.0
Hand	1	1.0
Hot water	2	2.0
Kerosene	1	1.0
Piston of oxygen cylinder	1	1.0
Road traffic accident	54	54.0
ROD	4	4.0
Self fall	5	5.0
Stick	6	6
Stone	1	1.0
Wood	13	13.0
Lentil stick	1	1.0
Total	100	100.0

**Table 2:** OTS score and likelihood of visual acuity at 6 months

Sum of raw points	OTS Category	No. of cases (In Present Study)	No perception of light	Light perception/hand movements+	1/200-19/200	20/200-20/50	>20/40
0–44	1	43	74%	15%	7%	3%	1%
45–65	2	20	27%	26%	18%	15%	15%
66–80	3	11	2%	11%	15%	31%	41%
81–91	4	7	1%	2%	3%	22%	73%
92–100	5	17	0%	1%	1%	5%	94%



**Fig. 1:** Type of injury



**Fig. 2:** Betts classification (Birmingham eye trauma terminology system)

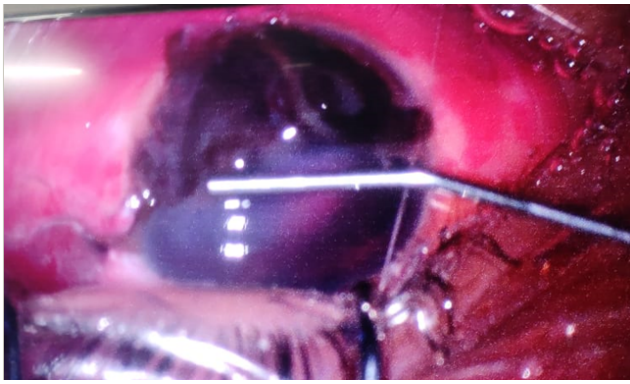
is the primary referral center.

Figure 5 shows the trend of ocular trauma throughout the study period, which is from November 2019 till April 2021. There is a decrease in the total number of cases in February 2020, corresponding with the first wave of COVID-19. A similar decrease in ocular trauma is seen in February 2021, consistent with the second wave of COVID -19.

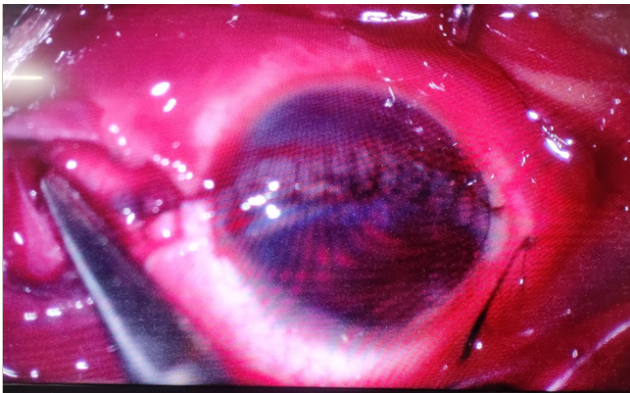
Like other studies, close globe injuries (38%) were more common than open globe (22%) injuries.<sup>8–12</sup> In our study, the cornea was affected in 25% of patients. In a study

by Alem et al., 39.33% of patients had a corneal tear. According to the JUDO study, the cornea was the most affected part of the eye (63.2%), which was also confirmed in Menelik II Hospital studies.<sup>13–16</sup>

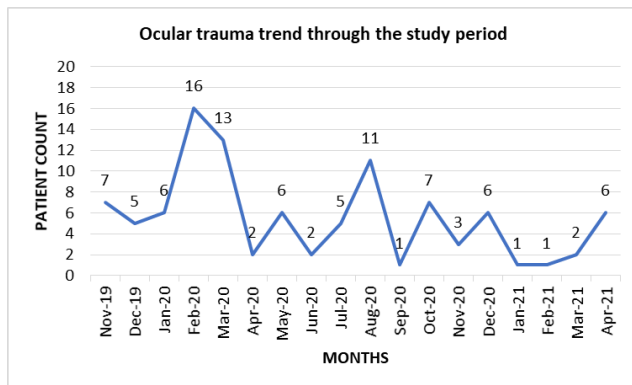
8% (n=8) of patients in our study showed early signs of traumatic cataracts. They were treated with cataract surgery and intraocular lens implantation whenever possible. Three patients underwent lens extraction with anterior vitrectomy



**Fig. 3:** Case No 98: Preoperative zone 3 rupture



**Fig. 4:** Case No 98: Postoperative: corneo-scleral suturing



**Fig. 5:** Trend of ocular trauma through the study period

for lens dislocation into the anterior chamber. Four patients with lens drop in the vitreous underwent lens extraction and scleral fixated intraocular lens implantation.

According to a blunt trauma study, hyphema is a common complication of blunt eye trauma in approximately 50% of patients.<sup>17</sup> In our study, 19% (n=19) patients had hyphema, with five patients having total hyphema. Bed rest, pressure bandage, topical steroids, cycloplegics, and antiglaucoma therapy helped the hyphema resolve.

14% (n=14) of patients had a vitreous haemorrhage in our study, which was detected on a B-scan and

treated conservatively. Nontraumatic causes account for most of the vitreous haemorrhage (diabetic retinopathy, sickle cell disease, posterior vitreous detachment, retinal vein occlusion, leukaemia). Nevertheless, trauma accounts for 12–31% and is the most common cause of vitreous haemorrhage in younger patients.<sup>14</sup>

Berlin's oedema, also known as "Commotio retina," is best described as a transient, well-defined greyish-white opacification of the retina following blunt ocular trauma. We observed twenty-two cases of commotio retinae that were treated conservatively. This injury occurs in 9% to 14% of blowout fractures, according to studies.<sup>18</sup>

## 5. Conclusion

Ocular trauma had male predilection and was common in young adults. The most common cause of eye injuries was automobile accidents. This necessitates the implementation of improved road safety measures in this region. Appropriate eye-protective devices like safety goggles, face shields, helmets, and glasses with special filters to protect from optical radiation must be worn. The need to wear protective headgear and eyewear is critical and should not be overlooked. In mechanical injury, close globe injuries included 18% (n=18) contusion and 20% (n=20) lamellar laceration. 16% (n=16) were penetrating injuries, 6% (n=6) were rupture, and 34% (n=34) were adnexal injuries in open globe injury. There were no cases of I.O.F.B. in the present study. Majority of patients presented within 6 hours of trauma to our centre. The most commonly affected structures were the eyelid and adnexa in this study. There was a significant number of Berlin's oedema in this study. B.E.T.T. classification of ocular trauma at the time of presentation helps to categorize ocular injuries. Visual prognosis can be effectively explained to the patient with regular use of ocular trauma score.

## 6. Source of Funding

None.

## 7. Conflicts of Interest

The authors declare no conflicts of interest.

## References

- Jawade S, Dagwar R, Chauhan R. Clinical Profile and Visual Outcome of Blunt Ocular Trauma in a Tertiary Care Centre of Central India: A Prospective Study. *Int J Med Sci Clin Invent*. 2020;7(11):5063–9.
- Mowatt L, McDonald A, Ferron-Boothe D. Hospitalization trends in adult ocular trauma at the University Hospital of the West Indies. *West Indian Med J*. 2012;61(6):605–9.
- Nadeem S, Ayub M, Fawad H. Visual outcome of ocular trauma. *Pak J Ophthalmol*. 2013;29(1):34–9.
- Khun F, Morris R, Witherspoon CD. Birmingham Eye Trauma Terminology (BETT): terminology and classification of mechanical eye injuries. *Ophthalmol Clin North Am*. 2002;15(2):139–43.

5. Karve S, Kolte A, Alfia A, Rathi H. Study of clinical profile of ocular trauma at a tertiary eye care centre. *Int J Contemp Med Res.* 2017;4(12):4–7.
6. Kaufman SC, Lazzaro DR. Textbook of Ocular Trauma: Evaluation and Treatment. Germany: Springer; 2017.
7. Qayum S, Anjum R, Rather S. Epidemiological profile of pediatric ocular trauma in a tertiary hospital of northern India. *Chin J Traumatol.* 2018;21(2):100–3.
8. Oner A, Kecec Z, Krakucuk S, Ikizceli I, Sözüer EM. Ocular trauma in Turkey: a 2-year prospective study. *Adv Ther.* 2006;23(2):274–83.
9. Mccarty CA, Fu CL, Taylor HR. Epidemiology of ocular trauma in Australia. *Ophthalmology.* 1999;106(9):1847–52.
10. Bhadani UP, Kumar G, Kumar R. The study of clinical profile and visual outcome of Ocular Trauma. *Eur J Mol Clin Med.* 2021;7(9):3639–46.
11. Wadwekar B, Hansdak A, Sahu P, Karnam AH, Sanjana EF. Clinical profile of ocular trauma at a tertiary care hospital in South India: A retrospective study. *Trauma.* 2021;doi:10.1177/14604086211044001.
12. D'Antone VA, Quiroz LC, Florez DC. Clinical profile of ocular injuries in a geographically isolated Colombian municipality. *Int Emerg Nurs.* 2020;52:100909. doi:10.1016/j.ienj.2020.100909.
13. Alem KD, Arega DD, Weldegiorgis ST, Agaje BG, Tigneh EG. Profile of ocular trauma in patients presenting to the department of ophthalmology at Hawassa University: Retrospective study. *PLoS ONE.* 2019;14(3):e0213893.
14. Asaminew T, Gelaw Y, Alemseged F. A 2-year review of ocular trauma in Jimma University Specialized Hospital. *Ethiop J Health Sci.* 2009;19(2):67–74.
15. Brophy M, Sinclair SA, Hostetler SG, Xiang H. Pediatric eye injury-related hospitalizations in the United States. *Pediatrics.* 2006;117(6):1263–71.
16. Altıntaş L, Altıntaş O, Yüksel N, Pirhan D, Ozkan B, Çağlar Y. Pattern of open eye injuries in northwest Turkey: a retrospective study. *Ulus Travma Acil Cerrahi Derg.* 2011;17(4):334–9.
17. Bolourian A, Moradian KH, Shandiz E. Prevalence of hyphema and its complications in patients with eye blunt trauma. *J Med Sci Islam Azad Univ Mashhad.* 2009;4(4):259–64.
18. Zigelbaum BM, Tostanoski JR, Kerner DJ, Hersh PS. Urban eye trauma. A one-year prospective study. *Ophthalmology.* 1993;100(6):851–6.

### Author biography

**Piyushi Sao**, Post Graduate Student  <https://orcid.org/0000-0001-8242-5915>

**Vallabha K**, Professor

**Cite this article:** Sao P, Vallabha K. A profile of ocular trauma in patients attending tertiary care center, North Karnataka. *Indian J Clin Exp Ophthalmol* 2022;8(3):325-329.