

Study of Electrocardiographic Changes in Acute Ischemic Stroke

Received: 21 October 2022, **Revised:** 22 November 2022, **Accepted:** 24 December 2022

Dr Mayuri M Bhujappagol

Post Graduate Department Of General Medicine Shri B M Patil Medical College, Hospital And Research Centre, Vijayapur Karnataka
Mayuribhujappagol95@Gmail.Com

Dr Vijaykumar G Warad

Professor Department Of General Medicine Shri B M Patil Medical College, Hospital And Research Centre, Vijayapur Karnataka
Vijay.Warad@Bldedu.Ac.In

***Corresponding Author: Dr Mayuri M Bhujappagol**

Keywords:

Stroke, Ischemic stroke, ECG (electrocardiography)

Abstract

Worldwide, cerebrovascular disease are a major cause of mortality and morbidity. The cerebral arteries atherosclerotic disease is the main cause. Haemorrhage, hypoperfusion, and embolism are further reasons. Common accompanying conditions include ECG abnormalities that mimic myocardial ischemia. Aim –To study the pattern of ECG changes in patients with Acute ischemic stroke Materials and methods – A descriptive cross-sectional research. There are a total of 60 patients, over 18 years satisfying the criteria for stroke, were involved in the study. Imaging CT/MRI confirmed the diagnosis of stroke. A 12-lead electrocardiogram was recorded on admission. ECG was evaluated for parameters like Rate, Rhythm, T wave abnormalities, QTc abnormalities, and ST segment abnormalities. The research was conducted from January 2021 to January 2022.. The results were pooled, and statistical analyses were performed. Results- ECG characteristics such as rate, rhythm, T wave abnormalities, QTc abnormalities, and ST segment abnormalities were all analysed. The mean age was 60 years. QTc prolongation was the most frequent ECG alteration found in 30.6% of patients. Additional ECG alterations were T wave inversion (20.4%), ST depression (17%), Bradycardia (13.6%), and Tachycardia (8.5%); 8.5% had normal ECGs. Conclusion – In the evaluation of patients of acute ischemic stroke, the study supports the use of ECG. Even in individuals with no history of coronary artery disease, electrocardiographic alterations are frequently seen in acute ischemic stroke cases, it is crucial to recognise this, since failing to do so might result in incorrectly classifying these patients as having coronary heart disease (CAD). The management of patients in terms of revascularization and surgical treatments can be helped by interpreting these ECG alterations.

1. Introduction

A stroke is a “Rapid development of clinical signs and symptoms of a focal neurological impairment lasting longer than 24 hours or leading to death with no apparent cause other than a vascular origin”⁽¹⁾⁽²⁾. Transient ischemic attack is used when the focused neurological impairments only last for a brief period often less than an hour . It is the world's second leading cause of mortality and the

fourth leading cause of disability⁽³⁾ . Arterial thrombosis, embolism, systemic hypoperfusion, and venous thrombosis are the primary causes of ischemic strokes⁽⁴⁾⁽⁵⁾⁽⁶⁾. ECG abnormalities are more common in patients with stroke. The changes in the ECG were thought to be caused by sympathetic activity. Tonic calcium channel openings, repolarization issues, and abnormal ECG patterns can all be brought on by excessive catecholamines over-activating beta-adrenergic

Journal of Coastal Life Medicine

receptors: When confronted with this electrocardiographic pattern, healthcare workers face distinct challenges. It is critical to differentiate between stroke-induced ECG abnormalities and those caused by concurrent ischemic heart disease (7).

2. Materials and Methods

A cross-sectional descriptive study, conducted over 13 months from January 2021-22 in The Department of Medicine BLDE (DU) Shri B M Patil Medical College, Hospital and Research Centre Vijayapura, Karnataka, India; written informed consent was taken from all patients included in study. Sixty patients aged more than 18 years of acute stroke admitted to medical wards with a diagnosis of acute ischemic stroke proved by CT/MRI (within 24 hours of presentation) included in study. The study excluded participants with ischemic heart disease, haemorrhagic stroke, recurrent stroke, and electrolyte disturbances. An extensive history was taken, a thorough

examination was performed, and the requisite biochemical tests were run. In 24 hours of admission, 12-lead ECG was performed. Results were compiled, and a statistical study was done.

3. Statistical Analysis

A statistical tool for the social sciences was used to do statistical analysis after entering the data into a Microsoft Excel sheet (Version 20). Findings were shown as counts, percentages, graphs, and Mean (Median) SD.

4. Results

The mean age was 60.52 years, standard deviation 13.86. 83.3% of patients were over 50 years, with 16.7% being young stroke. The highest percentage of study subjects in the age between 61–70 years. The highest percentage of study subjects were Male 61.7%.

According to analysis of ECG abnormalities, 8.5% of all acute ischemic stroke patients (n=5) had normal ECGs, whereas 91.5% of cases (n=55) showed some ECG abnormalities

TABLE 1 Ecg Changes with Percentage

ECG CHANGES	NO. OF PATIENTS	PERCENTAGE (%)
QTc PRLONGATION	18	30.6
T WAVE INVERSION	12	20.4
ST DEPRESSION	10	17
BRADYCARDIA	8	13.6
TACHYCARDIA	5	8.5
RHYTM CHANGES	2	3.4
NORMAL ECG	5	8.5

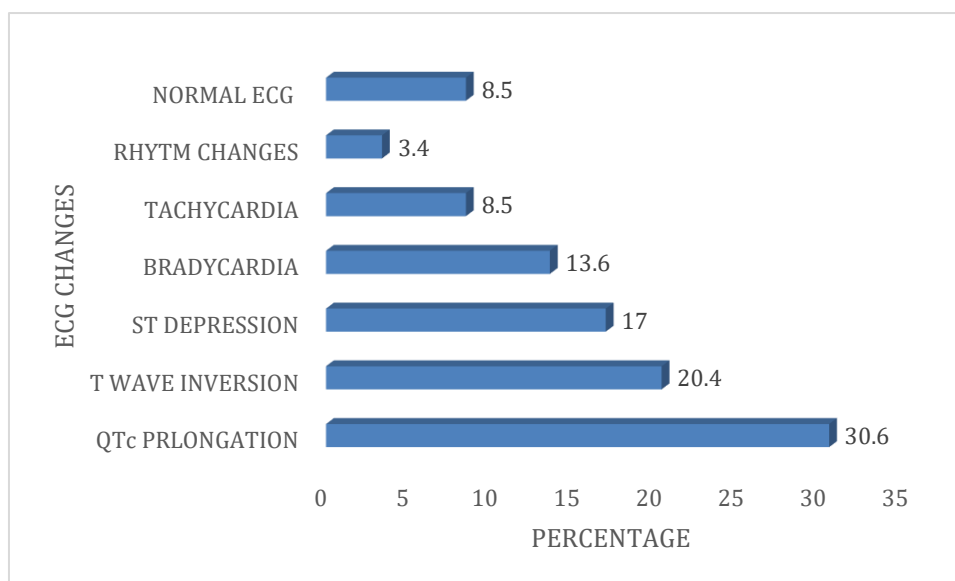


Figure 1

5. Discussion

The average age in the current research was 60.2 years. Kumar et al. study shows mean age of 62⁽⁸⁾, Saxena et al. study shows mean age of 67+/-8.90 years⁽⁹⁾, current study analysis, 16.7% of cases occurred among individuals under the age of 50.

In our study, 8.5% of the ECGs were normal, Purshothaman et al. study shows normal ECG in 23% of patients⁽¹⁰⁾ and Dimant et al. showed that 11% with no ECG alterations⁽⁵⁾.

QTc prolongation (30.6%), T wave inversions (20.4%), ST depression (17%), were among the most frequent ECG alterations in our research. Purshothaman et al. study T wave inversions 33% patients, QT prolongation 26%, ST depression in 30% of cases⁽¹⁰⁾. Togha et al. found QT prolongation in 36% of patients, T wave inversion 1%.⁽¹¹⁾

T wave inversions were seen in 31.9% of Kumar et al., Tandur, and Sundragiri cases, respectively⁽¹²⁾. Togha et al. showed T wave inversions 40%⁽¹³⁾, T wave alterations were seen in 20.4% of cases in the current study.

In our study, ST depression 17% of CVA patients. Kumar et al. showed ST alterations in 17% of patients⁽⁸⁾.

Following an ischemic stroke, there was a convincing increase in cardiac tissue

catecholamines, as demonstrated by Offerhaus and Van Gool⁽¹⁴⁾. These catecholamine-induced subendocardial lesions were also characterized by myofibrillar degeneration and dispersed foci of enlarged myocytes surrounded by invading monocytes. Myocardial necrosis usually develops as a vascular distribution in CAD patients. Within minutes of the injury's commencement, neurogenic myocardial injury can be seen, and cellular abnormalities can be seen. Mononuclear infiltration, early calcification, and hypercontracted, banded cardiac cells are the most common features of myocytolysis⁽¹⁵⁾.

6. Limitations

To demonstrate the incidence of alterations in the ECGs of individuals with acute ischemic stroke, serial ECGs were not recorded.

There was no control group analysed, therefore the occurrence of aberrant ECG patterns within the normal population may have contributed greater relevance.

References

- [1] Bybee KA, Kara T, Prasad A, et al :Systemtic review : transient left ventricular apical ballooning : a syndrome that mimics ST- segment elevation myocardial infarction. Ann Intern Med 141:858, 2004
- [2] Wittstein IS, Thiemann DR, Lima JA, et al: Neuro-humoral features of myocardial

Journal of Coastal Life Medicine

- stunning due to sudden emotional stress. *N Engl J Med* 352:539, 2005.
- [3] Ovbiagele B, Nguyen-Huynh MN. Stroke epidemiology: advancing our understanding of disease mechanism and therapy. *Neurotherapeutics*. 2011; 8(3): 319-29
- [4] Brouwers PJ, Wijdicks EF, Hasan D, Vermeulen M, Wever EF, Frericks H et al: Serial electrocardiographic recording in aneurismal subarachnoid hemorrhage. *Stroke* 1989;20(9):1162-7.
- [5] Dimant J and Grob D. Electrocardiographic changes and myocardial damage in patients with acute cerebrovascular accidents. *Stroke* 1977;8(4):448-55.
- [6] Di Pasquale G, Pinelli G, Andreoli A, Manini G, Grazi P, Tognetti F. Holter detection of cardiac arrhythmias in intracranial subarachnoid hemorrhage. *Am J Cardiol*. 1987;59(6):596-600.
- [7] Kumar S, Sharma GD, Dogra VD. A study of electrocardiogram changes in patients with acute stroke. *Int J Res Med Sci*. 2016;4(7):2930-37.
- [8] Saxena P, Kumar L, Dwivedi NC, Saxena PC. Prognostic importance of ST-T changes in ECG in acute stroke. *International Journal of Contemporary Medical Research* 2016;3(7):1999-2001.
- [9] Purushothaman S, Salmani D, Prarthana KG, Bandelkar SMG, Varghese S. Study of ECG changes and its relation to mortality in cases of cerebrovascular accidents. *Journal of Natural Science, Biology, and Medicine*. 2014;5(2):434-36.
- [10] Tandur S and Sundaragiri S. A study of electrocardiographic changes in acute cerebrovascular accidents. *Int J Med Sci Public Health*. 2016;5(12):2560-65.
- [11] Dogan A, Tunc E, Ozturk M, Kerman M, Akhan G. Electrocardiographic changes in patients with ischaemic stroke and their prognostic importance. *Int J Clin Pract* 2004;58:436-40.
- [12] Somasundaran A, Jayaraj K, George AT, George G, Antony TP. Electrocardiographic changes in acute stroke patients. *Asian Journal of Science and Technology*. 2015;6(7):1595-9.
- [13] Offerhaus L, Van Gool J: Electrocardiographic changes and tissue catecholamines in experimental subarachnoid haemorrhage. *Cardiovasc Res* 3:433, 1969.
- [14] Samuels M: Electrocardiographic manifestations of neurologic disease. *Semin Neurol* 4:453, 1984
- [15] Kothavale A, Banki NM, Kopelnik A, et al: Predictors of left ventricular regional wall motion abnormalities after subarachnoid hemorrhage. *Neurocrit Care* 4:199, 2006