

Functional Outcomes of Quadriceps Tendon versus Hamstring Tendon Autograft using Suspensory Fixation at Femoral and Tibial Sites for Primary Anterior Cruciate Ligament Reconstruction: A Randomised Controlled Study

RONAK YASHWANTBHAI KHATRI¹, VIJAYKUMAR PATIL², SHRIKANT KULKARNI³, SANDEEP NAIK⁴, SANTOSH NANDI⁵



ABSTRACT

Introduction: Arthroscopic Anterior Cruciate Ligament (ACL) reconstruction using hamstring tendon autografts is commonly used in day-to-day practice. Recently, the quadriceps tendon has been considered as a graft choice for primary ACL reconstruction due to its reliable graft size and resistance to rupture. The available literature comparing Quadriceps and Hamstring autografts in ACL reconstruction is limited. Therefore, the present study was conducted to compare the functional outcomes of these autografts using suspensory fixation at the femoral and tibial sites.

Aim: To compare the functional outcomes of quadriceps tendon versus hamstring tendon autografts for primary ACL reconstruction.

Materials and Methods: A randomised controlled study was conducted at Department of Orthopaedics, BLDE's Shri BM Patil Medical College and Research Centre, Vijayapur, Karnataka, India, from January 2021 to April 2023. Thirty-four patients were included in the study and randomised into two groups: one group was operated with a quadriceps tendon graft, and the other group used a hamstring tendon autograft. Both groups underwent surgery using suspensory fixation, and postoperative rehabilitation was similar. Functional outcomes (assessed using Lysholm and International Knee Documentation Committee (IKDC) scores), return to preinjury activity, and complications were evaluated. Statistical analysis was performed using Statistical Package for Social Sciences

(SPSS) version 20.0. The Mann-Whitney U test was applied to compare pre- and postoperative functional outcomes (Lysholm and IKDC scores) at 6, 12, and 24 months, with a significance level of $p < 0.05$.

Results: Out of 34 patients, 27 (79%) were male and 7 (21%) were female. The follow-up period ranged from a minimum of 24 months to a maximum of 26 months. The mean Lysholm score in the hamstring group increased from 47 preoperatively to 92 at six months postoperatively, while in the quadriceps group, it increased from 46 preoperatively to 90 at six months postoperatively. The reliability and validity of the IKDC score for the hamstring group also increased from 46 preoperatively to 79 at six months, and for the quadriceps group, it increased from 44 preoperatively to 78 at six months. A total 31 of the cases (91%) returned to their preinjury activity, while 3 patients (9%) (2 from the hamstring group and 1 from the quadriceps group) experienced knee stiffness, which restricted their ability to squat and sit cross-legged. There were no significant differences in Lysholm and IKDC scores between the hamstring and quadriceps tendon autografts at 6, 12, and 24 months postoperatively.

Conclusion: Patients undergoing single bundle ACL reconstruction have comparable functional outcomes with either hamstring or quadriceps grafts at the end of the 2-year follow-up period, with no specific graft site complications. The soft tissue quadriceps tendon autograft can be considered as an equally viable option for graft selection.

Keywords: Anterior cruciate ligament injuries, Autografts, Arthroscopy, Lysholm knee score

INTRODUCTION

One of the ligaments in the knee joint that frequently ruptures is the ACL. Reconstruction has long been recognised as a treatment for instability and to prevent associated complications [1]. Conservatively treated ACL tears may result in residual instability and pain due to knee instability itself or instability-related lesions such as Ramp lesion, bucket handle tears, and posterior horn longitudinal tears of the medial and lateral menisci, chondral defects, stenosis, and osteophytes at the intercondylar notch [2]. Post-traumatic osteoarthritis of the knee is a common finding in chronic ACL tears. Arthroscopic ACL reconstruction using autografts is the standard

practice [3]. Allografts carry a risk of slower graft incorporation, higher rupture rates in some highly active young groups, non availability, and increased cost [4].

Bone-patellar tendon-bone graft has been considered the gold standard for ACL reconstruction due to its high strength, stiffness, ease of harvest, consistent graft size, and bone integration potential [5]. However, complications such as patellar ligament rupture, patella fracture, or tibial tuberosity may occur intraoperatively [6]. Postoperatively, common complaints of quadriceps weakness can lead to extension lag [7], problems with kneeling, and anterior knee pain, which have drawn attention to other graft options [8].

Hamstring tendon autograft is a common choice amongst surgeons due to its larger cross-sectional area and the maintenance of the extensor mechanism's integrity [5]. Moreover, the Hamstring tendon autograft has an elastic modulus similar to that of the native ACL, resulting in postoperative outcomes similar to the native ACL, with less anterior knee pain and stiffness [9]. However, it may have a longer healing time and graft integration time within the bone tunnel, as well as hamstring weakness with compromised flexion and internal rotation [9].

In recent years, the soft tissue quadriceps tendon has been increasingly used as a graft choice for ACL reconstruction due to its reliable graft size. The Quadriceps tendon has the same width as the patellar tendon but a larger cross-sectional area, resistance to rupture, and can be harvested with a minimally invasive technique. It also has the ability to adjust in width as per the intraoperative requirement [10]. Compared to the hamstring graft, it exhibits less laxity on pivot shift, and therefore lower failure rates compared to the hamstring graft have been claimed [11]. However, some reported disadvantages include the need for an extra incision for graft harvest, which can lead to Quadriceps atrophy and weakness postoperatively, and in rare cases (<1%), donor site quadriceps tendon rupture [12].

Studies claim that the Quadriceps tendon as a graft tends to perform better or equally to the hamstring tendon in terms of functional outcomes and has fewer complications [11,13,14]. The available literature comparing quadriceps and hamstring grafts in ACL reconstruction is limited. Hence, the present study aimed to compare the functional outcomes of these autografts using suspensory fixation at the femoral and tibial sites.

MATERIALS AND METHODS

A randomised controlled study was conducted at Department of Orthopaedics, BLDE's Shri BM Patil Medical College and Research Centre, Vijayapur, Karnataka, India from January 2021 to April 2023.

Sample size calculation: The sample size was calculated to detect a true difference in means between two groups with a power of 50% and a significance level of 5% (two-sided) [7]. The estimated sample size was 34.

Ethical clearance was obtained from the Institutional Ethical Committee, BLDE (DU) Shri BM Patil Medical College, Vijayapur, Karnataka, India with approval number IEC/NO-11/21 (dated 22/01/2021). Informed and written consent was obtained from all participating patients.

Inclusion criteria: The study included patients aged 18 to 45 years with clinically and Magnetic Resonance Imaging (MRI)-confirmed ACL ruptures.

Exclusion criteria: Patients with ACL ruptures associated with meniscal injury requiring meniscectomy, multiligament knee injuries, open knee injuries, associated fractures around the knee joint, associated neurovascular injury, polytrauma, and patients medically unfit for surgery were excluded.

Procedure

A total of 42 patients were initially recruited, but eight patients did not meet the inclusion criteria, resulting in a final sample size of 34 patients. The subjects were randomised into two groups using the lottery method. Group A (17 patients) underwent ACL reconstruction using the quadriceps tendon, while Group B (17 patients) underwent ACL reconstruction using the Hamstrings tendon autograft. Both groups underwent ACL reconstruction with suspensory fixation on both the femoral and tibial sides. The postoperative rehabilitation protocol was the same for both groups.

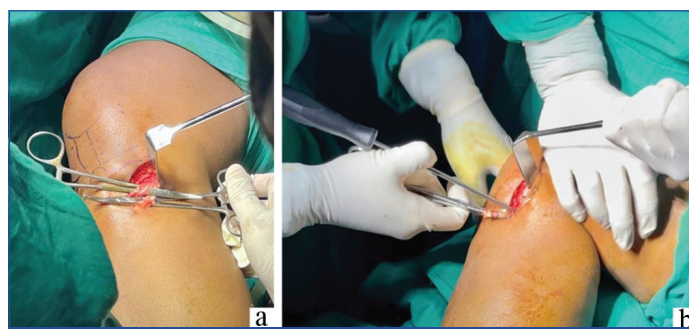
Patient demographics, side of the injury, functional outcomes (measured by Lysholm [15] and IKDC [16] scores), return to preinjury activity, and complications were assessed. Follow-up evaluations

were conducted for a minimum of 24 months and a maximum of 26 months. The Lysholm and IKDC scores were assessed preoperatively and postoperatively at 6, 12, and 24 months. The Lysholm scoring system evaluated patients' perceptions of their own function and indications of instability, with scores ranging from excellent (91-100) to unsatisfactory (<65) [15]. The IKDC scoring system assessed subjective assessment, symptoms, range of motion, and ligament inspection, with scores ranging from 0 (lowest level of function or highest level of symptoms) to 100 (highest level of function and lowest level of symptoms) [16].

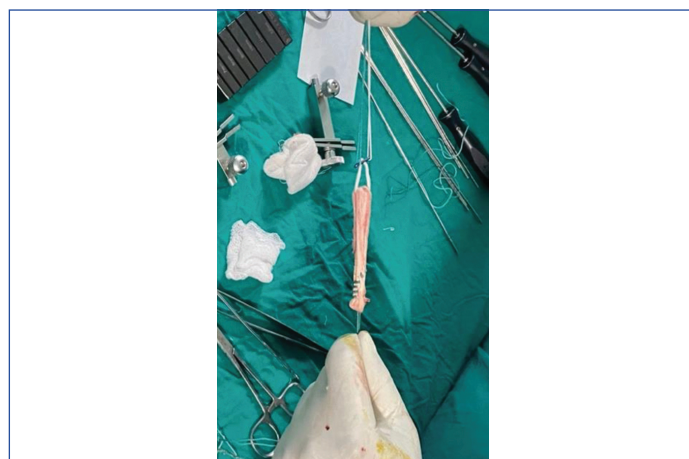
Surgical technique:

(a) Graft harvest:

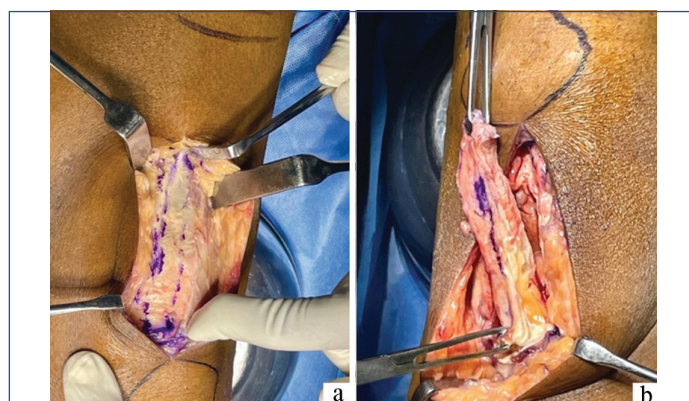
- For the hamstring tendon autograft [Table/Fig-1 a,b,2] [17], an oblique incision was made one finger breadth medial to the tibial tuberosity. The Sartorius fascia was incised, and the insertions of the gracilis and semitendinosus tendons were identified. Bands connecting the tendons were severed, and both tendons were stripped using a tendon stripper.
- For the soft tissue quadriceps tendon autograft [Table/Fig-3a,b] [9], a mid-line incision ending at the superior



[Table/Fig-1]: Hamstrings graft harvest incision, Tendon Exposure (a); and Tendon stripping (b).



[Table/Fig-2]: Hamstrings graft preparation.



[Table/Fig-3]: Soft tissue quadriceps tendon autograft incision (a); and harvesting (b).

pole of the patella was made. The anterior surface of the central portion of the quadriceps tendon was incised using a knife. The distal graft diameter would increase by 0.5 to 1 mm to prepare the graft for suture. A number 15-blade was used to extend the longitudinal incision distally to the superior pole of the patella. Deep dissection was avoided since only a partial thickness graft was to be harvested. After elevating 3 cm of the tendon, it was whipstitched using a looped suture. For most patients undergoing anatomic ACL restoration, a graft length of 7 cm was sufficient [18].

- (b) **ACL Reconstruction [19,20]:** A five-strand hamstrings graft and quadriceps graft were harvested with a diameter of 9 mm in all cases. Anatomical ACL reconstruction was performed by fixing the endobutton on the femoral side and the base plate on the tibial side.

The postoperative protocol and rehabilitation [19] were similar in both groups, including quadriceps strengthening, active Range Of Motion (ROM) of 0-90 degrees, weight bearing as tolerated with crutches in the first two weeks, patella mobilisation, and ankle pumps. At four weeks, ROM of 0-120 degrees with full weight bearing using a stick was achieved. Full ROM (>130 degrees) and weight bearing without support were advised at six weeks. Further hamstrings strengthening, agility training, and sports-specific exercises were performed.

STATISTICAL ANALYSIS

The statistical analysis was conducted using the Statistical Package for Social Sciences (SPSS version 20.0). The Mann-Whitney U test was applied to compare functional outcomes (Lysholm and IKDC scores) preoperatively and postoperatively at 6, 12, and 24 months. A p-value <0.05 was considered statistically significant.

RESULTS

Out of 34 patients, 17 (50%) underwent surgery with Hamstrings tendon autografts, while the remaining 17 had quadriceps tendon autografts. Among them, 27 (79%) were male and 7 (21%) were female. A total of 16 patients (47%) sustained a left-sided injury, while 18 (53%) sustained a right-sided knee injury. The mean value of the Lysholm score in the Hamstrings group preoperatively was 47.06, which increased to 91.9 at six months postoperatively and 98.8 at 24 months. The IKDC score of the Hamstrings group also increased from 45.5 preoperatively to 79.2 at six months and 96.06 at 24 months. In the quadriceps group, the mean value of the Lysholm score preoperatively was 45.8, which increased to 90.2 at six months postoperatively and 99.1 at 24 months. The IKDC score of the Quadriceps group also increased from 43.8 preoperatively to 78 at six months and 96.2 at 24 months.

The Lysholm and IKDC scores for the Hamstrings and Quadriceps tendon autografts showed no significant difference ($p>0.05$) at 6, 12, and 24 months postoperatively [Table/Fig-4,5]. All patients in the study had unsatisfactory outcomes preoperatively with a

Comparison of Lysholm	Hamstrings		Quadriceps		Mann-Whitney U	p-value
	Mean	Std. Deviation	Mean	Std. Deviation		
Preop	47.06	6.057	45.82	6.840	127.500	0.563
Postop 6 months	91.94	3.716	90.29	4.370	108.000	0.218
Postop 12 months	97.35	2.805	95.82	3.414	122.500	0.454
Postop 24 months	98.82	0.635	99.18	0.636	104.000	0.114

[Table/Fig-4]: Comparison of mean Lysholm scores between Hamstrings and Quadriceps tendon autograft groups preoperatively and postoperatively at 6, 12 and 24 months.

Mann-Whitney U score, *p-value <0.05

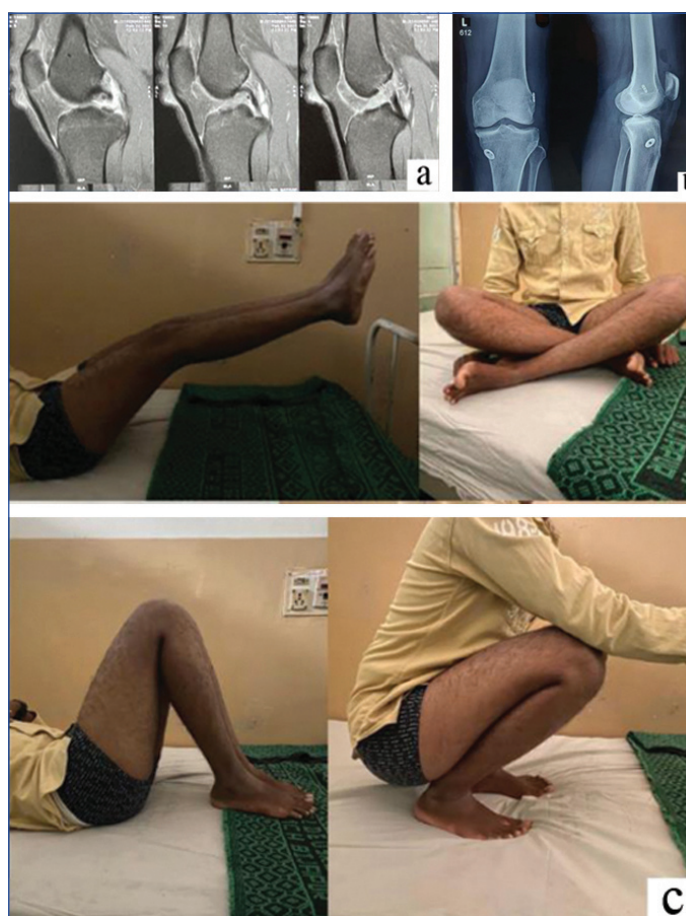Comparison of IKDC Scores	Hamstrings		Quadriceps		Mann-Whitney U	p-value
	Mean	Std. Deviation	Mean	Std. Deviation		
Preop	45.53	6.345	43.82	7.117	107	0.205
Postop 6 months	79.24	7.742	78.06	7.284	121	0.433
Postop 12 months	91.88	7.279	89.41	7.027	102	0.150
Postop 24 months	96.06	0.899	96.23	0.831	129	0.567

[Table/Fig-5]: Comparison of mean IKDC scores between Hamstrings and Quadriceps tendon autograft groups preoperatively and postoperatively at 6, 12 and 24 months.

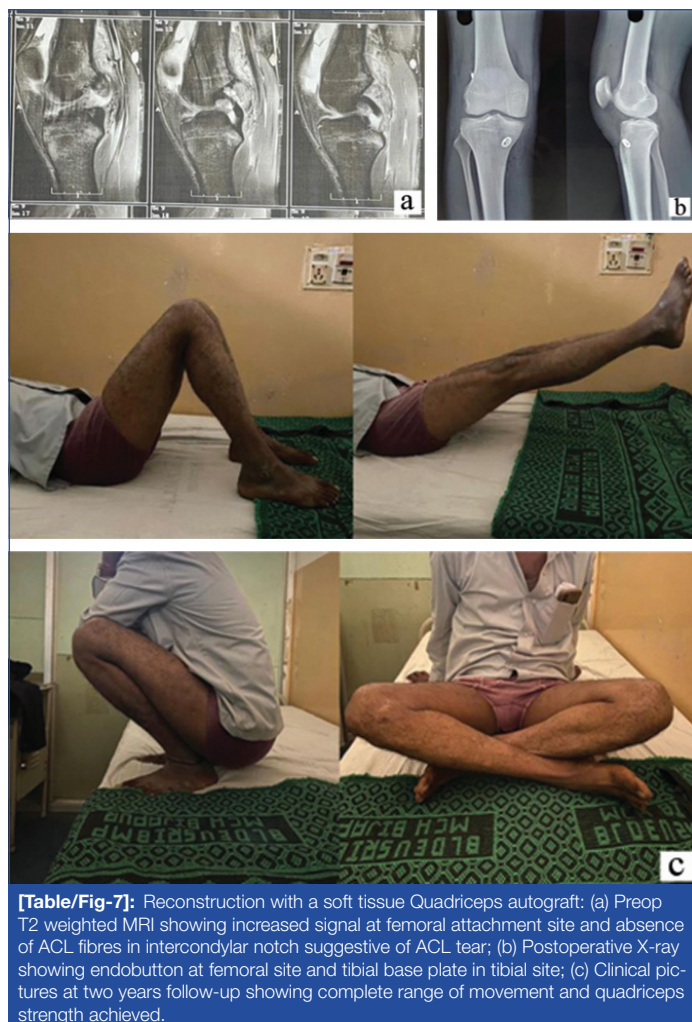
Mann-Whitney U score, *p-value <0.05

mean Lysholm score of 46.44. At six months postoperatively, 19 (56%) patients achieved excellent outcomes, 14 (41%) had good outcomes, and one (3%) patient had fair functional outcomes. At the one-year follow-up, all patients achieved excellent outcomes except for one with good functional outcomes. At the two-year follow-up, all patients scored excellent. A total of 31 (91%) cases returned to their preinjury activity. Three patients (two from the Hamstrings group and 1 from the Quadriceps group) still experienced knee stiffness, which restricted them from squatting and sitting cross-legged. Sixteen patients (47%) out of 34 returned to sports activity [Table/Fig-6,7], while the remaining 18 (53%) experienced mild pain and difficulty in cutting, accelerating, and sudden stops while running.

Complications: One patient from each group (Hamstrings and Quadriceps) had a superficial infection at the donor site, which was treated with intravenous antibiotics. Two patients from the Hamstrings group and one from the Quadriceps group complained of knee stiffness due to poor compliance with postoperative



[Table/Fig-6]: Reconstruction with four-tailed Hamstrings graft: (a) Preop T2-weighted MRI showing increased signal at femoral attachment site and disruption in continuity of ACL fibres in intercondylar notch suggestive of ACL tear; (b) Postoperative X-ray showing Endobutton at femoral site and tibial base plate in tibial site; (c) Clinical pictures at two years follow-up showing complete range of movement and quadriceps strength achieved.



[Table/Fig-7]: Reconstruction with a soft tissue Quadriceps autograft: (a) Preop T2 weighted MRI showing increased signal at femoral attachment site and absence of ACL fibres in intercondylar notch suggestive of ACL tear; (b) Postoperative X-ray showing endobutton at femoral site and tibial base plate in tibial site; (c) Clinical pictures at two years follow-up showing complete range of movement and quadriceps strength achieved.

rehabilitation. Aggressive physiotherapy helped increase the range of movement from 10 to 80 degrees. Two patients, both from the Hamstrings group, reported numbness over the anteromedial aspect of the leg. None of the patients experienced severe early postoperative pain, unsatisfactory cosmetic appearance of the postoperative scar, implant or fixation failure requiring removal, or infection debridement.

DISCUSSION

A randomised controlled study was conducted to compare the functional outcomes of Quadriceps and Hamstrings tendon autografts in ACL reconstructions. No significant difference was observed between the two groups at a two-year follow-up. Out of 34 patients, 17 (50%) were operated on with the Hamstrings tendon, and the remaining 17 with Quadriceps tendon autograft. All patients in the study had unsatisfactory outcomes preoperatively (according to Lysholm scores). At six months postoperatively, 19 patients achieved excellent, 14 good, and one patient fair functional outcomes. At the one-year follow-up, all patients achieved excellent outcomes except for one with good functional outcomes. At the two-year follow-up, all patients scored excellent.

A similar study by Todor A et al., retrospectively followed up with 72 patients (39 Quadriceps and 33 Hamstrings) for two years [21]. Pomenta Bastidas MV et al., conducted a non-randomised comparative study including 52 patients (25 Quadriceps and 27 Hamstrings) with a minimum two-year follow-up [22]. All patients who sustained sports-related injuries decided not to return to sports at the final follow-up. There was no significant difference in functional outcomes between Quadriceps and Hamstrings tendon autograft at the two-year follow-up based on Lysholm ($p=0.563$) or IKDC ($p=0.567$) scores in the present study. These

findings were similar to the study by Todor A et al., which also concluded no significant difference in functional outcomes based on Lysholm scores ($p=0.299$) [21]. Pomenta Bastidas MV et al., found no significant difference in IKDC scores ($p=0.38$) between both groups [22].

In the present study, two patients from each group were noted to have a superficial infection at the donor site. Three patients (two Hamstrings and one Quadriceps group) complained of restricted range of movement due to poor compliance with postoperative rehabilitation. Two patients from the Hamstrings group reported numbness over the anteromedial aspect of the leg. None of the patients reported unsatisfactory cosmetic appearance of the postoperative scar. There were no cases of fixation failure at the tibial or femoral site at the end of two years, and no deep infections requiring debridement. Additionally, there were no implant or graft-related long-term complications requiring revision.

Todor A et al., reported five patients in the Quadriceps group with unsatisfactory results, while eight patients in the Hamstrings group reported mild numbness on the anteromedial aspect of the leg. None of their patients required revisions or reoperations [21]. Pomenta Bastidas MV et al., found three patients requiring revision surgery, one from the Quadriceps group due to donor site infection, and the other two (one from each group) due to sports injury [22].

Hence, the findings of the present study were similar to other studies, which concluded that the soft tissue Quadriceps tendon provides comparable outcomes to Hamstrings tendon autograft in ACL reconstruction [21,22].

Limitation(s)

The short duration of follow-up and reliance on subjective scores for assessment were potential limitations of the present study.

CONCLUSION(S)

Patients undergoing single-bundle ACL reconstruction have comparable functional outcomes with either hamstrings or quadriceps grafts at the end of a 2-year follow-up, with no specific graft site complications. Hence, the soft tissue quadriceps autograft can be considered a reliable graft option for primary ACL reconstruction, similar to Hamstrings, in the future.

REFERENCES

- [1] Thompson L. Quadriceps tendon graft for ACL reconstruction-how does it compare?-a literature review with a case example. 2018.
- [2] Krause M, Frosch KH, Freudenthaler F, Achtnich A, Petersen W, Akoto R. Operative Versus Conservative Treatment of Anterior Cruciate Ligament Rupture. *Dtsch Arztebl Int.* 2018;115(51-52):855-62. <https://doi.org/10.3238/arztebl.2018.0855>.
- [3] Krupa S, Reichert P. Factors influencing the choice of graft type in ACL reconstruction: Allograft vs autograft. *Adv Clin Exp Med.* 2020;29(10):1145-51. <https://doi.org/10.17219/acem/124884>.
- [4] Mistry H, Metcalfe A, Colquitt J, Loveman E, Smith NA, Royle P, et al. Autograft or allograft for reconstruction of anterior cruciate ligament: A health economics perspective. *Knee Surg Sports Traumatol Arthrosc.* 2019;27(6):1782-90. <https://doi.org/10.1007/s00167-019-05436-z>.
- [5] Butt UM, Khan ZA, Amin A, Shah IA, Iqbal J, Khan Z. Peroneus longus tendon harvesting for anterior cruciate ligament reconstruction. *JBJS Essent Surg Tech.* 2022;12(2):e20.00053. <https://doi.org/10.2106/JBJS.ST.20.00053>.
- [6] Perez JR, Emerson CP, Barrera CM, Greif DN, Cade WH, Kaplan LD, et al. Patient-reported knee outcome scores with soft tissue quadriceps tendon autograft are similar to bone-patellar tendon-bone autograft at minimum 2-year follow-up: a retrospective single-center cohort study in primary anterior cruciate ligament reconstruction surgery. *Orthop J Sports Med.* 2019;7(12):2325967119890063. <https://doi.org/10.1177/2325967119890063>.
- [7] Ito N, Capin JJ, Khandha A, Buchanan TS, Silbernagel KG, Snyder-Mackler L. Bone-patellar tendon-bone autograft harvest prolongs extensor latency during gait 2 yr after ACLR. *Med Sci Sports Exerc.* 2022;54(12):2109-17. <https://doi.org/10.1249/MSS.0000000000003009>.
- [8] Wilding CSR, Cruz CCA, Mannino LBJ, Deal CJB, Wake CJ, Bottoni CR. Bone-Tendon-Autograft Anterior Cruciate Ligament Reconstruction: A New Anterior Cruciate Ligament Graft Option. *Arthrosc Tech.* 2020;9(10):e1525-30. <https://doi.org/10.1016/j.eats.2020.06.021>.

- [9] Matzkin E. Editorial commentary: Large-diameter quadrupled hamstring autografts are an acceptable option for national collegiate athletic association division I college football players: we must challenge our comfort zone to be successful in the end zone. *Arthroscopy*. 2022;38(1):107-08. <https://doi.org/10.1016/j.arthro.2021.06.014>.
- [10] Xerogeaneas JW. Quadriceps tendon graft for anterior cruciate ligament reconstruction: The graft of the future! *Arthroscopy*. 2019;35(3):696-97. <https://doi.org/10.1016/j.arthro.2019.01.011>.
- [11] Nyland J, Collis P, Huffstutler A, Sachdeva S, Spears JR, Greene J, et al. Quadriceps tendon autograft ACL reconstruction has less pivot shift laxity and lower failure rates than hamstring tendon autografts. *Knee Surg Sports Traumatol Arthrosc*. 2020;28(2):509-18. <https://doi.org/10.1007/s00167-019-05720-y>.
- [12] Singh H, Glassman I, Sheean A, Hoshino Y, Nagai K, de Sa D. Less than 1% risk of donor-site quadriceps tendon rupture post-ACL reconstruction with quadriceps tendon autograft: a systematic review. *Knee Surg Sports Traumatol Arthrosc*. 2023;31(2):572-85. <https://doi.org/10.1007/s00167-022-07175-0>.
- [13] Akoto R, Albers M, Balke M, Bouillon B, Höher J. ACL reconstruction with quadriceps tendon graft and press-fit fixation versus quadruple hamstring graft and interference screw fixation-A matched pair analysis after one year follow-up. *BMC Musculoskelet Disord*. 2019;20(1):109. <https://doi.org/10.1186/s12891-019-2499-y>.
- [14] Runer A, Wierer G, Herbst E, Hepperger C, Herbort M, Gföller P, et al. There is no difference between quadriceps- and hamstring tendon autografts in primary anterior cruciate ligament reconstruction: a 2-year patient-reported outcome study. *Knee Surgery, Sports Traumatology, Arthroscopy*. 2018;26(2):605-14. <https://doi.org/10.1007/s00167-017-4554-2>.
- [15] Lysholm J, Gillquist J. Evaluation of knee ligament surgery results with special emphasis on use of a scoring scale. *Am J Sports Med*. 1982;10(3):150-54. <https://doi.org/10.1177/036354658201000306>.
- [16] Hefti F, Müller W, Jakob RP, Stäubli HU. Evaluation of knee ligament injuries with the IKDC form. *Knee Surg Sports Traumatol Arthrosc*. 1993;1(3-4):226-34. <https://doi.org/10.1007/BF01560215>.
- [17] Gilmer BB. Editorial Commentary: Goldilocks and the three grafts: managing tendon harvest and graft length problems in autograft anterior cruciate ligament reconstruction. *Arthroscopy*. 2018;34(8):2463-65. <https://doi.org/10.1016/j.arthro.2018.05.025>.
- [18] Clinger B, Xerogeaneas J, Feller J, Fink C, Runer A, Richter D, et al. Quadriceps tendon autograft for anterior cruciate ligament reconstruction: state of the art. *J ISAKOS*. 2022;7(6):162-72. <https://doi.org/10.1016/j.jisako.2022.08.010>.
- [19] Musahl V, Engler ID, Nazzari EM, Dalton JF, Lucidi GA, Hughes JD, et al. Current trends in the anterior cruciate ligament part II: Evaluation, surgical technique, prevention, and rehabilitation. *Knee Surg Sports Traumatol Arthrosc*. 2022;30(1):34-51. <https://doi.org/10.1007/s00167-021-06825-z>.
- [20] Kohn L, Rembeck E, Rauch A. Anterior cruciate ligament injury in adults: Diagnostics and treatment. *Orthopade*. 2020 49(11):1013-28. <https://doi.org/10.1007/s00132-020-03997-3>.
- [21] Todor A, Nistor DV, Catelev S. Clinical outcomes after ACL reconstruction with free quadriceps tendon autograft versus hamstring tendons autograft. A retrospective study with a minimal follow-up two years. *Acta Orthop Traumatol Turc*. 2019;53(3):180-83. <https://doi.org/10.1016/j.aott.2019.03.004>.
- [22] Pomenta Bastidas MV, Sastre S, Segur Vilalta JM, Rios J, Sabater M, Popescu D. Quadriceps tendon vs hamstring autograft in primary ACL reconstruction-a comparative study with minimum two-year follow-up. *Acta Orthop Belg*. 2022;88(2):347-54. <https://doi.org/10.52628/88.2.7306>.

PARTICULARS OF CONTRIBUTORS:

1. Postgraduate Student, Department of Orthopaedics, BLDE's Shri BM Patil Medical College and Research Centre, Vijayapur, Karnataka, India.
2. Assistant Professor, Department of Orthopaedics, BLDE's Shri BM Patil Medical College and Research Centre, Vijayapur, Karnataka, India.
3. Assistant Professor, Department of Orthopaedics, BLDE's Shri BM Patil Medical College and Research Centre, Vijayapur, Karnataka, India.
4. Associate Professor, Department of Orthopaedics, BLDE's Shri BM Patil Medical College and Research Centre, Vijayapur, Karnataka, India.
5. Professor, Department of Orthopaedics, BLDE's Shri BM Patil Medical College and Research Centre, Vijayapur, Karnataka, India.

NAME, ADDRESS, E-MAIL ID OF THE CORRESPONDING AUTHOR:

Dr. Sandeep Naik,
Associate Professor, Department of Orthopaedics, 2nd Floor, BLDE's Shri BM Patil Medical College and Research Centre, Vijayapur, Karnataka-586103, India.
E-mail: sandippkmc@gmail.com

PLAGIARISM CHECKING METHODS: [Jain H et al.]

- Plagiarism X-checker: Apr 10, 2023
- Manual Googling: Jul 01, 2023
- iThenticate Software: Jul 03, 2023 (8%)

ETYMOLOGY: Author Origin**EMENDATIONS:** 7**AUTHOR DECLARATION:**

- Financial or Other Competing Interests: None
- Was Ethics Committee Approval obtained for this study? Yes
- Was informed consent obtained from the subjects involved in the study? Yes
- For any images presented appropriate consent has been obtained from the subjects. Yes

Date of Submission: **Apr 04, 2023**
Date of Peer Review: **May 24, 2023**
Date of Acceptance: **Jul 05, 2023**
Date of Publishing: **Aug 01, 2023**