

## HEMORRHOIDS AND FISSURE IN PREGNANCY – SINGLE CENTERED CASE SERIES

Received : 25/03/2023  
 Received in revised form : 29/04/2023  
 Accepted : 25/05/2023

**Keywords:**

*Hemorrhoids, Anal fissure, Anal ulcer, pregnancy, gestational period, case series.*

Corresponding Author:

**Dr. Shreedevi Kori,**

Email: shree\_kori@yahoo.com

DOI: 10.47009/jamp.2023.5.3.200

Source of Support: Nil,

Conflict of Interest: None declared

*Int J Acad Med Pharm*  
 2023; 5(3); 972-976



Dayanand Biradar<sup>1</sup>, Shreedevi Kori<sup>2</sup>, Shivanand L. Karigar<sup>3</sup>, Mallikarjun B. Patil<sup>4</sup>, Rajasri Yaliwal<sup>5</sup>, Subhash Mudanur<sup>5</sup>, Vikram U. Sindagikar<sup>1</sup>, Sowmya Madderla<sup>6</sup>

<sup>1</sup>Associate professor, Department of General Surgery, BLDE (Deemed to be University) Shri B.M. Patil Medical College, Vijayapura, Karnataka, India

<sup>2</sup>Associate Professor, Department of Obstetrics and Gynaecology, BLDE (Deemed to be University) Shri B.M. Patil Medical College, Vijayapura, Karnataka, India

<sup>3</sup>Associate professor, Department of Anaesthesiology, BLDE (Deemed to be University) Shri B.M. Patil Medical College, Vijayapura, Karnataka, India

<sup>4</sup>HOD and Professor, Department of General Surgery, BLDE (Deemed to be University) Shri B.M. Patil Medical College, Vijayapura, Karnataka, India

<sup>5</sup>Professor, Department of Obstetrics and Gynaecology, BLDE (Deemed to be University) Shri B.M. Patil Medical College, Vijayapura, Karnataka, India

<sup>8</sup>Junior Resident, Department of Obstetrics and Gynaecology, BLDE (Deemed to be University) Shri B.M. Patil Medical College, Vijayapura, Karnataka, India

### Abstract

**Background:** Hemorrhoids and anal fissures are the most commonly observed complications during pregnancy or even after the birth of child. Hemorrhoids refers to the swelling in the veins whereas anal fissures occur as a result of tears in the region of anus. It has been estimated that approximately 30 – 40 % of females suffer from hemorrhoids during their delivery and 37 % suffer after their delivery. **Materials and Methods:** It is a single centered case series that has included the cases of patients having anal fissures and hemorrhoids during their pregnancy. Total of 6 cases are presented in this study and all of them have taken the conservative treatment approach. Some patients had previously presented to have normal delivery while others had C-section. Some patients demonstrated to have the symptoms of hemorrhoids like painful defecation, bleeding and itching while some patients presented to have no signs of hemorrhoids. Samples were taken as patients who came to Department of Obstetrics and Gynecology OPD and with history of Hemorrhoids and on Examination Hemorrhoids present. All Grades of Hemorrhoids are included in the study. **Result:** Clinical implications- This study will play an essential role in determining the association between the development of hemorrhoids and anal fissures in pregnant females which will help the clinicians and general population to take precautionary measures to prevent them from developing complications in future cases. **Conclusion:** Hemorrhoids and anal fissures are common and harmless during pregnancy but they can somehow affect the quality of life by interfering with the normal intestinal activity and may cause gastric issues.

## INTRODUCTION

Pregnant females usually suffer from several colorectal complications including the formation of anal fissures, bleeding stools, hemorrhoids, and carcinomas.<sup>[1]</sup> Hemorrhoids are usually harmless but they may be painful in most situations along with the bleeding in the stools.<sup>[2]</sup> Literature suggests that approximately 30 – 40 % of females suffer from hemorrhoids.<sup>[1]</sup> During pregnancy, a female may feel extra pressure on the lower digestive tract or lower part of the pelvis as a result of increased volume of blood, fetus and constipation leading to

be the main reason for swollen veins causing hemorrhoids.<sup>[3]</sup> Anal fissures occur acutely with painful lacerations as a result of hardening of stools in the anal region.<sup>[4]</sup> In severe and chronic cases, spasm usually occurs in the internal sphincter area thereby causing reduction in the flow of blood and delayed process of healing. According to statistics, approximately 10 – 15 % of the cases suffer from anal fissures during the course of their pregnancy or even after birth.<sup>[2]</sup>

A study has been carried out by Poskus et al (2022) which state that the most commonly associated symptoms of hemorrhoids and anal fissures include; painful defecation, itching, intense pain in the

surrounding and internal region, formation of palpable lumps in the anal region and discharge of blood during passing of stool.<sup>[5]</sup> Ganz et al (2013) highlighted that proper rectal exams should be conducted in order to properly diagnose the condition and to differentiate between the hemorrhoids and anal fissures. He also stated that close observation of anus is essential to rule out the cases of external hemorrhoids. In addition, sigmoidoscopy (observed the internal environment of the rectum) and digital rectal exam (for assessing the internal hemorrhoids) are also essential to rule out the cases.<sup>[6]</sup>

Moore et al (2013) suggests that sometimes hemorrhoids that occur during pregnancy relieves on their own after the birth of baby but its management during gestational period may include the change in sedentary life style, relieving of constipation by intake of fiber (20 – 30 grams / day) in diet, consumption of good water content (8 – 12 glasses / day), taking laxatives (advised by physician). In addition, constipation can also be avoided by relieving the excess pressure from the area by avoiding prolong sitting or standing, and by the use of donut cushion while sitting. This study is conducted to highlight the cases of female patients suffering from hemorrhoids and anal fissures during their gestational period.<sup>[7]</sup>

#### **CASE 1**

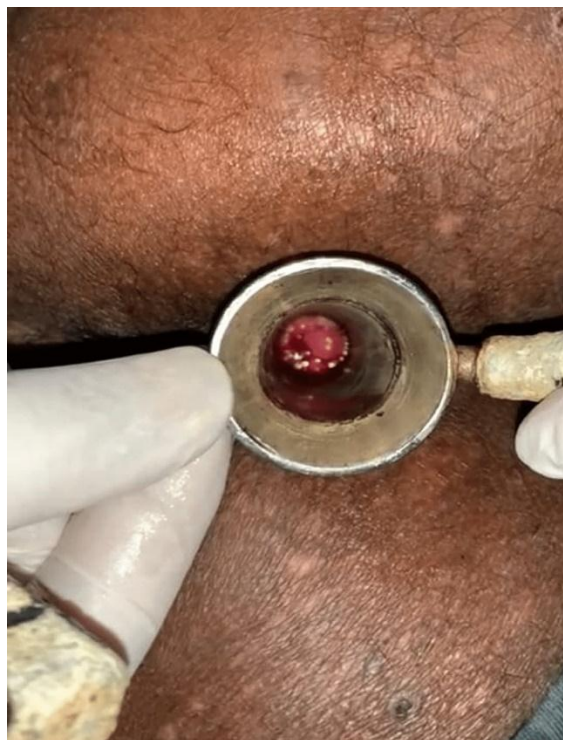A 34 - years old gravida 2 (15th week) para 1 living 1 having a Body mass index (BMI) of 21.5 kg/m<sup>2</sup> presented to the gynecological department with the complaints of bleeding during defecation, pain and itching surrounding the anal region and discharge of blood along with stool. Previously she has presented no such complaint before the conception or during the last pregnancy. Digital rectal exam (DRE) revealed that she was having grade I internal hemorrhoid which are causing pain and itching in the anal region. [Figure 1] Upon history taking and physical examination, it has been revealed that she is a house wife who stands for prolong period and excessive pressure has been born by her in the lower tract throughout her day. Her previous baby has been born healthy and was a normal delivery conducted in our hospital. She has been advised to modify her life style and follow slight exercise in order to relieve the excessive pressure. In addition, she has been prescribed with ointment and laxatives for 2 weeks in order to relieve the pain, swollen area and to reduce the constipation. In her follow up session after 2 weeks, she described that her constipation has been settled within this time period. She continued her follow ups till her delivery and delivered a normal baby.

A 34year Gravida 2 Para 1 Living 1 Female with 15weeks Period of Gestation with BMI 21.5kg/m<sup>2</sup> with Grade 1 Hemorrhoids on Digital Rectal Examination

#### **CASE 2**

A 25 - years old 10 weeks pregnant female presented to the hospital with complaint of severe

constipation from the last week. She has been visiting the hospital for her regular check-ups as this is her first pregnancy. Although, she stated that she has a family history of diabetes and constipation. She also reported that she often suffers from constipation despite taking routinely laxatives due to her sedentary life style and decrease consumption of water. Sometimes she also complains of bloody stools and pinching pain after passing stools. Upon history taking and physical examination, it has been revealed that she is obese with a BMI of 30 kg / m<sup>2</sup>. DRE showed that she has been suffering from grade I internal hemorrhoids and anal fissures with a swollen area surrounding all over the anus [Figure2]. Although no severe ulcerations and edema has been observed in the anal region. She has been prescribed to apply Anal pram and Tucks hydrocortisone ointment twice daily for disinfecting the overall area, decreasing the itching, swelling, inflammation and to promote the healing of the damaged tissue [4]. Her symptoms have been recovered after a continuous application for 2 weeks. She delivered her baby through C-section in this hospital.



**Figure 1: A 25 yr old 10 week Pregnant Female with BMI 30kg/m<sup>2</sup> with Grade 1 hemorrhoids**

#### **CASE 3**

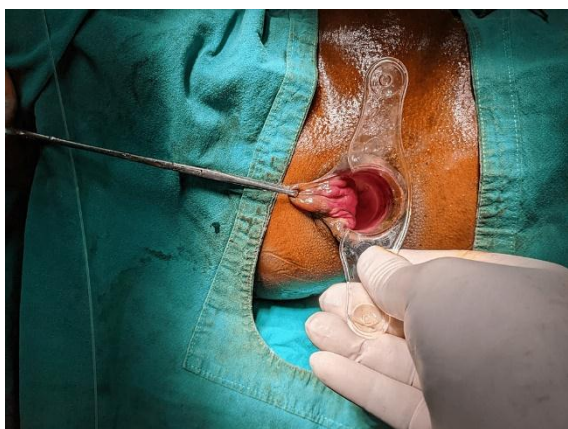
A 35 - years old gravida 3 para 2 living 2 having a BMI of 21.2 kg / m<sup>2</sup> presented to the hospital in 2nd trimester of pregnancy with presenting complaints of gastrointestinal issues. She reports that she suffers from pain while passing the stool and has gaps of about 3-4 days in between defecation. She suffered the same symptoms during the last 2 pregnancies as well and reported that she sometimes got loose stools while get constipation

sometimes. Her previous 2 deliveries were normal without any other presenting complications. Physical examination revealed that no redness and swelling has been observed on the exterior surface however, grade 1 internal hemorrhoids were observed along with anal fissures [Figure 3]. She has been receiving continuous treatment with prescribed laxatives and hemorrhoids ointment along with modification in her diet and life style.<sup>[2]</sup> Upon 1 week follow up treatment, she reported improvement in her symptoms of pain, irritation, swelling and constipation.

A 35year old Gravida 3 Para 2 Living 2 Female having a BMI of 21.2 kg / m<sup>2</sup> in 2nd Trimester of Pregnancy with Grade 1 Hemorrhoids

#### CASE 4

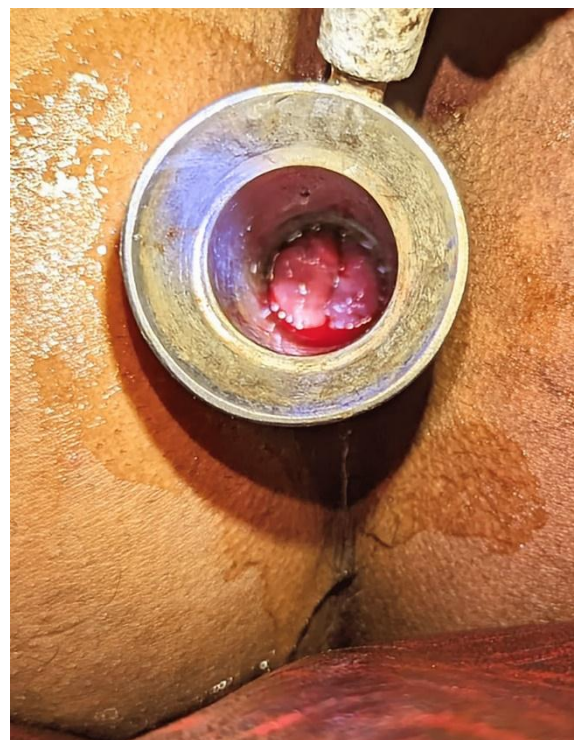A 32 - years old pregnant female presented to the hospital with sensations of pricking, bursting and burning pain along with constipation and bleeding from the rectum. She has been diagnosed with hemorrhoids from the last 4 weeks. She is gravida 2 para 1 living 1 and had presented with the same symptoms of constipation in her last pregnancy but at that time her symptoms of hemorrhoids appeared after delivery. Her previous delivery was normal without any complications and her baby had a normal weight. History taking and physical examination revealed that she is 15th week pregnant with a BMI of 32.1 kg / m<sup>2</sup>. She has no family history of diabetes or hypertension neither she has any GIT dysfunction. Upon digital rectal examination, it has been revealed that she is suffering from grade II internal hemorrhoids without any associated complications in gastrointestinal tract [Figure 4]. Along with several irritating symptoms, she also suffers from bleeding along with defecation. She has been prescribed with the conservative treatment approach such as rubber band ligation along with continuous use of laxatives (prescribed by physician).<sup>[3]</sup> In her follow up treatment after 2 weeks, she reported that her symptoms have subsided and her constipation has been relieved.



**Figure 2: A 32 - year old Gravida 2 Para 1 Living 1 Pregnant Female with 15weeks Period of Gestation with BMI 32.1 kg/m<sup>2</sup> with Grade 2 Hemorrhoids**

#### CASE 5

A 28 - years old gravida 2 para 1 living 1 presented to the hospital with diagnosed case of hemorrhoids. She has a BMI of 28.5 and no previous history of any surgery or complications. She has many associated symptoms of hemorrhoids and anal fissures which disturbs her during routine activities. She suffers from pain, irritation and itching after every defecation. Sometimes she also feels difficulty while defecating and sometimes unable to defecate for 3-4 days. Upon digital rectal examination, it has been observed that she has been suffering from grade II internal hemorrhoids [Figure 5]. She was receiving treatment through conservative management by using laxatives and other sclerotherapy injections but due to pregnancy it was being processed with care. She was advised to hydrate herself and keep a good electrolyte balance along with physical activity. After 2 weeks of taking proper medications, she reported that she was feeling better and her constipation has been subsided to some extent. Throughout her gestational period, she was receiving continuous follow ups with 2 weeks gap in between after few months she had recovered a lot and delivered a normal baby.

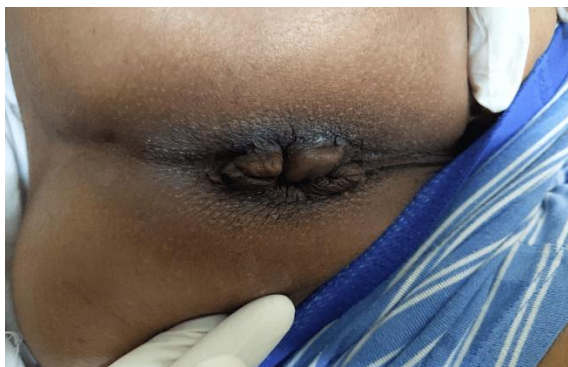

**Figure 3: A 28-year-old gravida 2 para 1 living 1 Pregnant Female with BMI 28.5kg/m<sup>2</sup> with Grade 2 Hemorrhoids and Anal Fissures**

#### CASE 6

A 34 years old gravida 4 para 3 living 2 dead 1 presented to the hospital setting with 10th week of pregnancy. She has a BMI of 25 and has a frail and weak body structure with poor diet intake. Her history revealed that she had belonged to a rural area that was not much developed. She had a complicated pregnancy before this one and her baby

died soon after birth due to environmental hazards. Upon physical examination, no other complication was observed in any of her systematic regions neither she has any traumatic history. DRE revealed that she had chronic hemorrhoids that has continuously been a trouble for her during pregnancy or even in the normal circumstances [Figure 6]. She has been taking the laxatives throughout the period but didn't get enough progress through it. She has been advised to apply the hemorrhoids ointment twice daily in order to reduce the inflammation and pain. Further, she was also advised to sit in a warm water bath tub to reduce the soreness. Sclerotherapy has been considered as an effective procedure in her case but with precautionary measures.<sup>[6]</sup> In her follow up sessions, she reported that she has recovered mildly from her hemorrhoids but still she feels pinching pain during defecation due to its chronicity. She delivered a healthy baby through C-section.



**Figure 4: A 34year old gravida 4 para 3 living 2 dead 1 Female with 10weeks of pregnancy with BMI of 25 kg/m<sup>2</sup> with Chronic Hemorrhoids**

## DISCUSSION

Anal fissure occurs as a result of breakthrough in the anal canal which can be recognized easily through anal bleeding often during the day time and sometimes after defecation.<sup>[8]</sup> The cases can be acute or chronic with bleeding and pain immediately after defecation in acute cases whereas reduction in pain and increased bleeding and swelling in chronic cases.<sup>[9]</sup> There are some certain locations that are prone in its development with major influence on the posterior mid portion of the anus. Its depth may also vary; it can be superficial or can be deep within the sphincter muscles.<sup>[10]</sup> In case of deep fissures, the muscles of internal sphincter become spasmatic thereby causes decrease in the blood flow and delayed in the healing process of cracked tissues.<sup>[9]</sup> Hemorrhoids may occur independently or either secondary to anal fissures especially during the gestational period. The prevalence of hemorrhoids has been observed among both males and females both pregnant females demonstrate to have higher prevalence as compared to other population.<sup>[11]</sup>

The exact etiology of the condition is unknown but literature suggests that it occurs as a result of sedentary lifestyle, unbalanced diet, and poor consumption of water. Pregnancy sometimes also leads to hemorrhoids due to excessive pressure on the lower part of the digestive tract as a result of fetus weight, constipation, and excessive flow of blood.<sup>[12]</sup> In some situations, the anal canal also become infectious due to several reasons, some females suffer from fissures after dew months of delivery due to heavy weight of the babies, post - partum incontinence, and long labor pain.<sup>[10]</sup>

The cases included in the study were reported to be between the time period of 2017-2022. All the included cases have the active symptoms of hemorrhoids with pain, bleeding after stools, irritability and itching in the surrounding area. Some the females were multiparous while some were uniparous which predisposes some females to be at higher risk of developing hemorrhoids or fissures. None of the patients however demonstrates any serious complications that could interfere with the delivery of the babies but they had demonstrated swollen vessels that has complicated their normal digestive tract. Therefore, the six female cases were treated conservatively owing to the symptoms of the patients who reported to show decrease in the symptoms of pain and severe constipation after few weeks of the conservative management. It is a recurring condition that can overwent again even after the proper treatment for few days and weeks, therefore, it is essential to follow the accurate guidelines associated with the modification of diet and lifestyle change. They are also required to take laxatives prescribed by physicians and high fiber contents in their diet throughout the period in order to avoid any complexities and complications during the gestational period and after delivery.

Limitations in this study include small sample size and Many articles are published in this area of study and is studied again as it is most encountered in pregnant females.

## CONCLUSION

Hemorrhoids and anal fissures are the most commonly observed complications in pregnant females that can occur either during pregnancy or after birth. It is not a harmful condition but it directly interferes normal gastric motility although it don't interfere with the process of delivery but it may complicate the condition due to associated inflammatory conditions. Therefore, it is essential to follow the conservative procedures for managing the condition. After managing the hemorrhoids, it become easier for the females to lead a normal life without any pain and irritation.

## REFERENCES

1. Altomare DF, Giannini I. Pharmacological treatment of hemorrhoids: a narrative review. *Expert opinion on pharmacotherapy*. 2013 Dec 1;14(17):2343-9.
2. Lohsiriwat V. Treatment of hemorrhoids: A coloproctologist's view. *World Journal of Gastroenterology: WJG*. 2015 Aug 8;21(31):9245.
3. Rao SS, Qureshi WA, Yan Y, Johnson DA. Constipation, Hemorrhoids, and Anorectal Disorders in Pregnancy. *Official journal of the American College of Gastroenterology| ACG*. 2022 Oct 1;117(10S):16-25.
4. Gaj F, Bianchi FP, Passannanti D, Telesco D. Relief of hemorrhoid symptoms: pilot study of a new topical ally. *Il Giornale di Chirurgia-Journal of the Italian Surgical Association*. 2020 Jan 1;41(1):118-25.
5. Poskus T, Sabonyte-Balsaitiene Z, Jakubauskiene L, Jakubauskas M, Stundiene I, Barkauskaite G, Smigelskaite M, Jasiunas E, Ramasauskaite D, Strupas K, Drasutiene G. Preventing hemorrhoids during pregnancy: a multicenter, randomized clinical trial. *BMC pregnancy and childbirth*. 2022 Dec;22(1):1-7.
6. Ganz RA. The evaluation and treatment of hemorrhoids: a guide for the gastroenterologist. *Clinical Gastroenterology and Hepatology*. 2013 Jun 1;11(6):593-603.
7. Moore JS, Seah AS, Hyman N. Management of hemorrhoids in unusual circumstances. In *Seminars in Colon and Rectal Surgery* 2013 Jun 1 (Vol. 24, No. 2, pp. 108-111). WB Saunders.
8. Davids JS, Ridolfi TJ. Hemorrhoids. *The ASCRS Textbook of Colon and Rectal Surgery*. 2022:209-29.
9. Hall G, Kann BR. Anal Fissure. In *Anorectal Disease* 2016 (pp. 95-126). Springer, Cham.
10. Davids JS, Ridolfi TJ. Hemorrhoids 11. *The ASCRS Textbook of Colon and Rectal Surgery*. 2021 Nov 20:209.
11. Yu S. Anal fissure. In *Practices of Anorectal Surgery* 2019 (pp. 45-53). Springer, Singapore.
12. Obcowska A, Kołodziejczak M. Haemorrhoids—current view on aetiology, pathogenesis and methods of treatment. A review of literature. *NowaMedycyna*. 2016 Jun 15.