

**"UTILITY OF FINE NEEDLE ASPIRATION CYTOLOGY  
IN DIAGNOSIS OF CLINICALLY SUSPECTED CASES  
OF METASTATIC LYMPH NODES"**

By

**DR. SHIKHA SHARMA**

Dissertation submitted to

**BLDE (Deemed to be University), Vijayapur, Karnataka**



In partial fulfillment of the requirements for the award of the degree of

**DOCTOR OF MEDICINE**

IN

**PATHOLOGY**

Under the Guidance of

**DR. SUREKHA U. ARAKERI** M.D.

Professor, Department of Pathology.

**B.L.D.E. (DEEMED TO BE UNIVERSITY)  
SHRI B.M. PATIL MEDICAL COLLEGE,  
HOSPITAL & RESEARCH CENTRE, VIJAYAPUR,  
KARNATAKA.**

**2019**

**B.L.D.E. ( DEEMED TO BE UNIVERSITY)**  
**SHRI B. M. PATIL MEDICAL COLLEGE, HOSPITAL**  
**& RESEARCH CENTRE, VIJAYAPUR**

**DECLARATION BY THE CANDIDATE**

I hereby declare that this dissertation entitled “**UTILITY OF FINE NEEDLE ASPIRATION CYTOLOGY IN DIAGNOSIS OF CLINICALLY SUSPECTED CASES OF METASTATIC LYMPH NODES**” is a bonafide and genuine research work carried out by me under the guidance of **Dr. SUREKHA U. ARAKERI**, Professor, Department of Pathology, B.L.D.E. (Deemed to be university) Shri B. M. Patil Medical College, Hospital & Research Centre, Vijayapur, Karnataka.

Date:

**Dr. SHIKHA SHARMA**

Place: Vijayapur

Post graduate student  
Department of Pathology,  
B.L.D.E (Deemed to be  
University) Shri B. M. Patil  
Medical College, Hospital &  
Research Centre, Vijayapur,  
Karnataka.

**B.L.D.E. (DEEMED TO BE UNIVERSITY)**  
**SHRI B. M. PATIL MEDICAL COLLEGE, HOSPITAL**  
**& RESEARCH CENTRE, VIJAYAPUR**

**CERTIFICATE BY THE GUIDE**

This is to certify that the dissertation “**UTILITY OF FINE NEEDLE ASPIRATION CYTOLOGY IN DIAGNOSIS OF CLINICALLY SUSPECTED CASES OF METASTATIC LYMPH NODES**” is a bonafide research work done by **Dr. SHIKHA SHARMA** in partial fulfillment of the requirements for the degree of **Doctor of Medicine (Pathology)**.

Date:

**Dr. SUREKHA U. ARAKERI** M.D.

Place: Vijayapur.

Professor,  
Department of Pathology,  
B.L.D.E. (Deemed to be  
University) Shri B. M. Patil  
Medical College, Hospital &  
Research Centre, Vijayapur,  
Karnataka.

**B.L.D.E. (DEEMED TO BE UNIVERSITY)**  
**SHRI B. M. PATIL MEDICAL COLLEGE, HOSPITAL**  
**& RESEARCH CENTRE, VIJAYAPUR**

**ENDORSEMENT BY HEAD OF DEPARTMENT**

This is to certify that the dissertation entitled “**UTILITY OF FINE NEEDLE ASPIRATION CYTOLOGY IN DIAGNOSIS OF CLINICALLY SUSPECTED CASES OF METASTATIC LYMPH NODES**” is a bonafide research work done by **Dr. SHIKHA SHARMA** in partial fulfillment of the requirements for the degree of **Doctor of Medicine (Pathology)**.

Date:

**Dr. B. R. YELIKAR** M.D.

Place: Vijayapur

Professor and H.O.D,  
Department of Pathology,  
B.L.D.E. (Deemed to be  
University) Shri B. M. Patil  
Medical College, Hospital &  
Research Centre, Vijayapur,  
Karnataka.

**B.L.D.E. ( DEEMED TO BE UNIVERSITY)**  
**SHRI B. M. PATIL MEDICAL COLLEGE, HOSPITAL**  
**& RESEARCH CENTRE, VIJAYAPUR**

**ENDORSEMENT BY PRINCIPAL /**  
**HEAD OF THE INSTITUTION**

This is to certify that the dissertation entitled “**UTILITY OF FINE NEEDLE ASPIRATION CYTOLOGY IN DIAGNOSIS OF CLINICALLY SUSPECTED CASES OF METASTATIC LYMPH NODES**” is a bonafide research work done by **Dr. SHIKHA SHARMA** in partial fulfillment of the requirements for the degree of **Doctor of Medicine (Pathology)**.

Date:

**Dr. S. P. GUGGARIGOUDAR**

Place: Vijayapur

Principal,  
B.L.D.E. (Deemed to be  
University) Shri B. M. Patil  
Medical College, Hospital &  
Research Centre, Vijayapur,  
Karnataka.

**B.L.D.E. (DEEMED TO BE UNIVERSITY)**  
**SHRI B. M. PATIL MEDICAL COLLEGE, HOSPITAL**  
**& RESEARCH CENTRE, VIJAYAPUR**

**COPYRIGHT**

**DECLARATION BY THE CANDIDATE**

I hereby declare that the B.L.D.E. (Deemed to be University), Karnataka shall have the rights to preserve, use and disseminate this dissertation / thesis in print or electronic format for academic / research purpose.

Date:

**Dr. SHIKHA SHARMA**

Place: Vijayapur

Post graduate student  
Department of Pathology,  
B.L.D.E. (Deemed to be  
University) Shri B. M. Patil  
Medical College, Hospital &  
Research Centre, Vijayapur,  
Karnataka.

**© B.L.D.E. (DEEMED TO BE UNIVERSITY) VIJAYAPUR**

## ACKNOWLEDGEMENT

I owe my deepest gratitude to my guide Dr. **SUREKHA U. ARAKERI MD**, Professor, Department of Pathology. Without her in depth knowledge, encouragement, unfettering support and continuous optimism this thesis would hardly have been completed. I express my warmest gratitude to her. Each meeting with her added invaluable aspects to the research and broadened my perspective. She has guided me with her invaluable suggestions, lightened up the way in my darkest times and encouraged me a lot in all aspects of my life. It was a great pleasure for me to have a chance of working with her.

I am indebted to the **Professor and H.O.D** of Department of Pathology **Dr. B. R. YELIKAR** for encouraging and boosting my potential. He has had a profound influence on both my personal growth and professional pursuits.

I am grateful to **Dr. R. M. POTEKAR Prof., Dr. S. B. HIPPARGI Prof.** and **Dr. M. H. KARIGOUDAR Prof.** for their guidance and support. I would like to attempt to thank them for making my time during my tenure in the Department a period that I will treasure.

I am forever thankful to all my colleagues specially **Dr. Moksha and Dr. Poojitha Ram V.** for their friendship and support. I thankfully acknowledge their contributions.

I would also like to thank my supportive seniors like **Dr. Y. Divya Prafulla, Dr. Varsha Deshpandey, Dr. Sachin S Kapse**, my beloved roommate **Dr. Shilpa Gupta** and all my dear juniors for their love and respect.

I am very grateful to all the technical staff of cytology and histopathology section who have helped me during this work.

Finally, my deep and sincere gratitude towards my parents. Whatever I perceive, deliver and accomplish belongs to them, today and forever. I am very grateful to my sister in law **Ishanee Sharma** and my brother **Sachin Sharma** for their continuous and unparalleled love, help and support. They have supported me in each and every way, believed in me permanently and inspired me in all dimensions of life. Last but not least my heartfelt thanks to all the patients who participated in this study and co-operated whole heartedly.

Date:

**Dr. SHIKHA SHARMA**

Place: Vijayapur

Post graduate student  
Department of Pathology.

## **LIST OF ABBREVIATIONS USED**

FNAC	Fine needle aspiration cytology
NHL	Non Hodgkins Lymphoma
H&E	Hematoxylin and eosin
IHC	Immunohistochemistry
Fig.	Figure
TIL	Tumour infiltrating lymphocytes
METS	Metastatic
Ca	Carcinoma
SCC	Squamous cell carcinoma
IDC	Infiltrating ductal carcinoma
LN	Lymph node
CK	Cytokeratin
PAP	Papanicolaou
AFB	Acid fast bacilli
POORLY DIFF CA	Poorly differentiated carcinoma
IHC	Immunohistochemistry

## **ABSTRACT**

### **BACKGROUND:**

Fine needle aspiration cytology (FNAC) is considered as a valuable diagnostic aid in the diagnosis of metastatic malignancies in the lymph nodes and is one of the most common indications for lymph node aspiration. It is safe, minimally invasive, reliable, and is convenient alternative to open biopsy.

### **OBJECTIVE:**

To evaluate utility of fine needle aspiration cytology in diagnosis of clinically suspected cases of metastatic lymph nodes with special reference to primary site.

### **MATERIALS AND METHODS:**

Eighty one clinically suspected cases of metastatic lymph nodes referred to cytology section for FNAC were included in study. Thorough clinical examination was done for all patients and standard FNAC procedure was done. Histopathology correlation and special stains were done wherever possible.

### **RESULT:**

Out of 81 clinically suspected cases of metastatic lymph nodes 72 cases were diagnosed as metastatic lymphadenopathy, 07 cases were negative for malignancy and two cases were reported as NHL on cytology. Histopathology correlation was done in 45.6% of cases. Maximum number of cases were in the range of 46-65 years of age group. Commonest group of metastatic lymph node in the present study was cervical group of lymph nodes amounting to 40.4% of cases. Metastatic squamous cell carcinoma was the commonest cytological diagnosis & commonest primary site was oral cavity. Out of 7 cases diagnosed as negative for malignancy on cytology 6 cases

were of reactive lymphadenitis and 1 case was diagnosed as granulomatous lymphadenitis.

**CONCLUSION:**

The overall diagnostic sensitivity, specificity, positive predictive value, negative predictive value and accuracy were 100%, 50%, 97.22%, 100% and 97.30% respectively. Based on these findings it was concluded that FNAC is a valuable diagnostic tool in detecting secondary as well as help in detecting primary site of malignancy.

**KEY WORDS:** FNAC, Metastatic lymph node, Squamous cell carcinoma, Primary site

## TABLE OF CONTENTS

<b>Sr. No.</b>	<b>Contents</b>	<b>Page No</b>
<b>1.</b>	<b>INTRODUCTION</b>	<b>1</b>
<b>2.</b>	<b>OBJECTIVES</b>	<b>3</b>
<b>3.</b>	<b>REVIEW OF LITERATURE</b>	<b>4</b>
<b>4.</b>	<b>MATERIALS AND METHODS</b>	<b>17</b>
<b>5.</b>	<b>RESULTS</b>	<b>20</b>
<b>6.</b>	<b>DISCUSSION</b>	<b>48</b>
<b>7.</b>	<b>CONCLUSION</b>	<b>55</b>
<b>8.</b>	<b>SUMMARY</b>	<b>56</b>
<b>9.</b>	<b>BIBLIOGRAPHY</b>	<b>58</b>
<b>10.</b>	<b>ANNEXURES</b>  <b>ETHICAL CLEARANCE LETTER</b>  <b>CONSENT FORM</b>  <b>PROFORMA</b>  <b>KEY TO MASTER CHART</b>  <b>MASTER CHART</b>	<b>68</b>

## LIST OF TABLES

Table no.	Table	Page No.
Table 1	Age and sex distribution	20
Table 2	Distribution of anatomical sites of lymph nodes	21
Table 3	Pie diagram showing distribution of anatomical sites of lymphnodes	22
Table 4	Cytological diagnosis in clinically suspected cases of metastatic lymph nodes	23
Table 5	Distribution of cases according to primary site	24
Table 6	Distribution according to primary site with cytological diagnosis	25
Table 7	Distribution of primary site in cervical lymph nodes	26
Table 8	Distribution of primary site in submandibular lymph nodes	27
Table 9	Distribution of primary site in inguinal lymph nodes	28
Table 10	Distribution of primary site in supraclavicular lymph nodes	29
Table 11	Categorization of cytological diagnosis in clinically suspected cases of metastatic lymph node	30
Table 12	Correlation between clinical and cytological diagnosis	30
Table 13	Details of discordant cases on cytology and histopathology	31
Table 14	Cytological and histopathological correlation	32
Table 15	Statistical analysis of clinical, cytological and histopathological diagnosis	33
Table 16	Distribution of anatomical sites of lymph nodes	50
Table 17	Cytological diagnosis in various studies	51

## LIST OF FIGURES

Figure No.	Figure	Page No.
Figure 1	Cytology of mets SCC in cervical LN	35
Figure 2	Cytology of mets SCC in cervical LN	35
Figure 3	Cytology of mets SCC in cervical LN	35
Figure 4	Histopathology (cell block ) of mets SCC in cervical LN	35
Figure 5	Histopathology (cell block ) of mets SCC in cervical LN	36
Figure 6	IHC showing SCC positive for CK	36
Figure 7	IHC showing SCC negative for CD45	36
Figure 8	Histopathology of primary site : oral cavity SCC	36
Figure 9	Cytology of mets poorly diff Ca	37
Figure 10	Cytology of mets poorly diff Ca	37
Figure 11	Histopathology (cell block) of mets poorly diff Ca	37
Figure 12	IHC of mets poorly diff Ca negative for CD45	37
Figure 13	Cytology of NHL in cervical LN	38
Figure 14	Cytology of NHL in cervical LN	38
Figure 15	Cytology of NHL in cervical LN	38
Figure 16	Cytology of NHL in cervical LN	38
Figure 17	Histopathology of NHL in cervical lymph node	39
Figure 18	Histopathology of NHL in cervical lymph node	39
Figure 19	IHC showing diffuse CD45 positivity in NHL of cervical LN	39
Figure 20	Histopathology of NHL tonsil	39
Figure 21	Cytology of mets malignant melanoma in inguinal LN	40
Figure 22	Cytology of mets malignant melanoma in inguinal LN	40

Figure 23	Histopathology of mets malignant melanoma in inguinal LN	40
Figure 24	Histopathology of mets malignant melanoma in inguinal LN	40
Figure 25	IHC showing diffuse HMB 45 positivity in mets malignant melanoma in inguinal LN	41
Figure 26	Histopathology of primary site : malignant melanoma of sole	41
Figure 27	Cytology of mets follicular carcinoma in submental LN	41
Figure 28	Cytology of primary site: follicular carcinoma of thyroid gland	41
Figure 29	Cytology of mets IDC in axillary LN	42
Figure 30	Cytology of mets IDC in axillary LN	42
Figure 31	Histopathology of primary site: IDC Breast	42
Figure 32	Histopathology of primary site: IDC Breast	42
Figure 33	Cytology of mets lobular carcinoma in axillary LN	43
Figure 34	Cytology of mets lobular carcinoma in axillary LN	43
Figure 35	Cytology of adenosquamous carcinoma	43
Figure 36	Cytology of adenosquamous carcinoma	43
Figure 37	Cytology of mets nasopharyngeal carcinoma in cervical LN	44
Figure 38	Cytology of mets nasopharyngeal carcinoma in cervical LN	44
Figure 39	Cytology of mets nasopharyngeal carcinoma in cervical LN	44
Figure 40	Cytology of mets nasopharyngeal carcinoma in cervical LN	44
Figure 41	Cytology of mets adeno Ca in inguinal LN	45
Figure 42	Histopathology showing features of sarcoma of inguinal region in clinically suspected mets Ca	45
Figure 43	IHC showing Pan CK negativity on histopathology section	45
Figure 44	IHC showing Pan CK negativity on histopathology section	45

Figure 45	Cytology of reactive inguinal LN	46
Figure 46	Cytology of reactive inguinal LN	46
Figure 47	Histopathology of necrotizing granulomatous lymphadenitis suggestive of tuberculosis in inguinal LN	46
Figure 48	Histopathology of necrotizing granulomatous lymphadenitis suggestive of tuberculosis in inguinal LN	46
Figure 49	Photomicrograph showing AFB in inguinal LN	47
Figure 50	Photomicrograph showing AFB in inguinal LN under fluorescence microscope	47
Figure 51	Cytology of mets SCC in cervical LN	47
Figure 52	Histopathology of acute suppurative lesion	47

## INTRODUCTION

Fine needle aspiration cytology (FNAC) for the diagnosis of clinically suspected cases of metastatic malignancies in the lymph nodes is one of the most common indication for lymph node aspiration.<sup>1-4</sup> FNAC is safe, cost effective, simple technique, well tolerated by the patients, repeatable and is done on outpatient basis.<sup>5-10</sup> It has significantly low risk of subsequent complication such as tumor recurrence as compared to excision biopsy and patient is also free from scar.<sup>11-14</sup>

FNAC is very useful in preoperative assessment of patients; however its interpretation requires sound understanding of cytomorphology and knowledge of different limitations due to variations in cellular patterns. Even though histological study of lymph node by open biopsy followed by FNAC still remains the standard practice for diagnosing lymph node malignancies, FNAC is still considered one of the most common indications for metastatic lymphadenopathy.<sup>15-18</sup> FNAC findings are analogous with those of tissue biopsies and in some situations the aspirate has equal characteristics of a micro-biopsy.<sup>19-22</sup>

Diagnosis of primary site in patients presenting with metastatic tumor is a challenging task for the clinician and cytopathologist when the site of primary is not known.<sup>23</sup> However thorough evaluation of clinical features and cytomorphological details give clue regarding nature and origin of primary tumor and thus helps in more specific and effective treatment to the patients. In patients with enlarged lymph nodes and previously documented malignancy, FNAC can prevent further surgery just by confirming the presence of metastasis and thus is of considerable value in documentation of recurrence and also helps in staging of tumor.<sup>24-26</sup>

Hence the present study was done to assess the usefulness of FNAC in diagnosing clinically suspected cases of metastatic lymph nodes with special reference to primary site which will bear impact on patient management and prognosis.

## **AIMS AND OBJECTIVES**

1. To evaluate utility of FNAC for cytological diagnosis of metastatic lesions in clinically suspected cases of metastatic lymph nodes
2. To evaluate utility of FNAC in diagnosis of clinically suspected cases of metastatic lymph nodes with special reference to primary site.

## REVIEW OF LITERATURE

### Historical Overview

It is not all astonishing that the first elucidation of what is referred to as Fine needle aspiration (FNA) biopsy was made long back in the year 1904 by E.D.W. Greig and A.C.H Gray in Uganda. They utilised hypodermic needle for aspirating lymph node juice and reported their findings on presence of motile trypanosomes in the lymph nodes of sleeping sickness patients.<sup>27-29</sup>

Gordon R. Ward in the year 1914 utilised FNA for the identification of lymph node tumours.<sup>27</sup>

In 1921, Dr. C.G. Guthrie, clinical pathologist successfully performed gland puncture and appropriately detected Hodgkins lymphoma which completely influenced the patient treatment and prognosis.<sup>27,30</sup>

In the year 1926, Dr. Hayes E. Martin from New York along with Fred W Stewart, surgical pathologist and Edward B. Ellis, chief histotechnologist proposed that needle aspiration of cervical lymph node is a better option than excision biopsies which turned out to be the most influential and valid diagnostic measure.<sup>27</sup>

Forkner in the year 1927 published detailed study on lymph node aspiration cytology. In between 1930 and 1940 the efforts of Martim and Willis, Pavlovski, Stahel, Rohr and Weil came into sight. They aspirated 2,500 tumours in 1933 and swiftly accumulated their experience, which permitted Dr. Fred Stewart to frame various principles of FNA cytology, by accentuating sample preparation, its limitations, variation in pattern on smear and morphology of individual cell, clinical and histological correlation which are still valid today.<sup>27,31</sup>

Dr. Fred Stewart utilised Romanovsky stains instead of H & E stains which resulted in re-emergence and improvisation of the technique in various European countries in the year 1950s. They also made effective use of needles that were smaller in size because these needles were less likely to cause any sort of complications or tumour seeding.<sup>27</sup>

In 1967 Zajicek along with Franzen at Karolinska hospital, Sweden gave various diagnostic criterias to diagnose precisely broad spectrum of lymph node pathologies.<sup>32</sup> Zajicek<sup>32</sup> reported 1,200 aspiration biopsies of lymphnode out of which 38% were found to be metastatic and 52% were falling in the category of various benign conditions of lymph node. Out of total 1200 cases, only 305 cases were subsequently operated and he concluded that aspiration biopsy might eliminate the need for surgery in many cases.

### **Indications for Lymph Node FNAC**

Technique of fine needle aspiration cytology of metastatic lymph nodes gained popularity and acceptance very rapidly in the whole world.<sup>33, 34</sup>

Lymph nodes that are superficial are easily accessible for FNAC by palpation wherein cases of deep seated lymphadenopathy require utilization of image guided techniques like ultrasound and computed tomography.<sup>35, 36</sup>

Indications for FNAC are:

1. To establish etiology of lymphadenopathy
2. For diagnosis of metastasis in draining lymph nodes and to determine the primary site in unknown primary.
3. Stage a known primary lymphoid malignancy
4. Look for any risk for advancement or evolution of lymphoid malignancies.<sup>37,38,39</sup>

Most of the patients that present with the complaints of lymph node enlargement are found maximally to fall in the category of non neoplastic lesions such as reactive, inflammatory, infectious and granulomatous disorders.<sup>40-43</sup> Approximately 30% of the cases show metastasis in lymph node whereas primary malignancies are noted in less than 10% of all cases of lymph node enlargement.<sup>27</sup>

In some studies, very high specificity is noted in cytological diagnosis of lymph node aspirates amounting to 98 -100%.<sup>44</sup> On the contrary, some studies mentioned that population and variety of lesions studied decides the sensitivity of cytological diagnosis made in cases of lymph node enlargement. In these studies, sensitivity for diagnosis of metastasis in enlarged lymph nodes by FNAC is more than 95%.<sup>27</sup> Multiple ancillary techniques such as culture, flow cytometry (FC), immunohistochemistry (IHC), Electron microscopy (EM), cytogenetics and various other molecular diagnostic studies can be carried out on FNA samples.<sup>45-46</sup>

It was speculated that excision biopsy of lymph node can be easily avoided in approximately 86% of the cases that present with lymph node enlargement with the advent of this highly useful technique of FNAC. Further change in the intervention to utilise excision biopsy of lymph node can be done to avoid any chance of missing suspicious lesion in cases where FNA does not prove any definitive diagnosis or in cases where there is persistent enlargement of lymph node for a period of one to three months even after the lesion was reported as non neoplastic on FNAC.<sup>27</sup>

Clinical history and physical examination of the patient which presents with enlarged lymph node should include site, size, shape, number, duration, consistency, overlying skin appearance, tenderness, surrounding area and fixity to the adjacent structures. It should also include history of respiratory and gastrointestinal symptoms, prior

medical history, family history, travel to endemic areas, medication intake and other relevant factors. All of the above information collectively helps in contributing to an accurate diagnosis on cytology.<sup>27,45</sup>

## **NORMAL HISTOLOGY AND CYTOLOGY OF LYMPH NODE**

Sound knowledge of the structural, cytological and histological features of normal lymph node is important to assess whether the pathology in FNAC from enlarged lymph node is reactive, infective or is due to lympho-proliferative disorder or metastasis.<sup>47-50</sup>

### **Normal Lymph node histology**

Parenchyma of a normal lymph node is surrounded by fibrous capsule. It is divided into outer cortex, inner medulla and an intervening paracortex and sinus system.<sup>51</sup>

The cortex is composed of primary and secondary follicles. Primary follicles are comprised of collection of small resting B cells that are found in non stimulated nodal state. Secondary follicles develop after stimulation by antigen and are comprised of narrow mantle zone of small B lymphocytes surrounding a germinal centre. Various types of cells are seen in germinal centre, majority of them are B cells in the form of centroblast and centrocytes along with macrophages containing phagocytosed debris.<sup>51</sup>

Mature immunoglobulins secreting B cells, known as plasma cells, is the primary cell type found in the medulla. The paracortex is comprised of numerous small lymphoid cells which are of T-phenotype along with activated T-cells and Immunoblasts.<sup>51</sup>

## **Normal Cytology of Lymph node**

Aspirate from a normal lymph node is comprised of 87-99% lymphocytes, 0-5% plasma cells and 1-3% of remainder cells.<sup>52</sup>

1. **Mature lymphocytes**:- These are small, round lymphocytes measures 7-10  $\mu$ , with dense nuclear chromatin having thin rim of pale cytoplasm.<sup>52</sup>

### **2. Follicular center cells**:-

A) Small cleaved lymphocytes- These cells are 10-12  $\mu$  in diameter. Nuclei of these cells have deep indentation of nuclear membrane, and hence the term cleaved. They have moderate amount of cytoplasm.<sup>52</sup>

B) Large cleaved lymphocytes - These cells are round measuring 20-40 $\mu$  in diameter. Their nuclei shows deep indentation therefore appears cleaved and nucleoli is not prominent. These cells have abundant basophilic cytoplasm.<sup>52</sup>

C) Small non-cleaved lymphocytes - These cells are round and larger measuring 12-20 $\mu$  in diameter. They have scant amount of cytoplasm and contain prominent nucleoli.<sup>52</sup>

D) Large non-cleaved lymphocytes -These cells are 20-40 $\mu$  in diameter having large round vesicular nucleus with two or three prominent nucleoli and moderate amount of cytoplasm.<sup>52</sup>

### **3. Immunoblast**

These cells are large cells measuring 20-40 $\mu$  in diameter having a size that is three times larger than small lymphocytes. Their nuclei is round, irregular with fine granular chromatin and prominent nucleoli and is centrally/ eccentrically placed with abundant amount of cytoplasm.<sup>52</sup>

#### **4. Plasma cells**

These cells have eccentrically placed nucleus having dense coarse chromatin that is often arranged in characteristic cart-wheel like pattern with deeply basophilic cytoplasm along with para-nuclear clear zone.<sup>52</sup>

#### **5. Macrophages**

These cells show broad variation in size. In the resting stage, they measure 14 to 34 $\mu$  in diameter. Cytoplasm of these cells contains many phagocytosed fragments of degenerated cells (tingible bodies). Their nuclei is round to oval having evenly distributed reticulated chromatin.<sup>52</sup>

#### **5. Lymphoid globules (Lymphoglandular bodies):**

They are characteristic finding in smears of lymphoid tissue. They are round cytoplasmic fragments seen in the background and have a diameter of 8 $\mu$ . They stain uniform pale blue similar to the cytoplasm of intact cells when visualized after staining with Giemsa stain. Various other cells like endothelial cells, interdigitating reticulum cells etc can also be seen in lymph node aspirate. Eosinophils, neutrophils and plasma cells may also be seen depending on pathological process.<sup>52</sup>

### **Challenges and various limitations of FNAC**

One of the most challenging area of cytopathology is reporting of broad array of lymph node pathologies on fine needle aspiration cytology. Lymph nodes can harbour a spectrum of various neoplastic and non neoplastic conditions.<sup>52, 53</sup> For all practical purposes, any primary site in the body can lead to lymph node metastasis. Therefore, evaluation of lymph node on FNAC should be supplemented with detailed clinical history of the patient along with proper physical examination and various laboratory test results for rendering diagnosis confidently and accurately.<sup>54, 55</sup>

Sometimes it becomes very challenging to report low-grade lymphomas on cytology due to the minimal degree of cytological atypia in the low grade lymphomas. In high grade lymphomas cytomorphologic features are difficult to differentiate from poorly differentiated metastatic SCC.<sup>27</sup>

Hence, it becomes mandatory to utilise wide range of ancillary techniques such as IHC, FC, molecular techniques and fluorescence in situ hybridization (FISH) in such situation to render precise diagnosis to the patient so that further management can be planned accordingly.<sup>56</sup>

### **Lymphadenopathy**

Lymphadenopathy is of two types: Generalised and localised.

Localised lymphadenopathy is also called as regional lymphadenopathy. Lymphnode enlargement within contiguous anatomic regions is noted in case of localised lymphadenopathy whereas non-contiguous enlargement of more than two groups of lymph nodes with or without hepatosplenomegaly is seen in generalized lymphadenopathy.<sup>55, 57</sup>

FNAC should be undertaken urgently in patients whose lymph nodes are enlarged for more than eight weeks and show evidence of fixity to the overlying skin or adjacent structures irrespective of the fact whether other parameters like age of the patient, site or symptoms are correlating with likelihood of malignancy or not.<sup>27</sup>

Lymph nodes are usually found to be firm to hard, confluent and shows fixity to adjacent structures or skin in cases of various malignant conditions.<sup>45</sup>

Various lymphomas and leukaemias account for maximum number of cases falling into the category of malignant lymphadenopathy in children, followed by metastasis

from primary malignancy such as neuroblastoma, rhabdomyosarcoma, Wilms tumour, nasopharyngeal carcinoma, and osteosarcoma.<sup>27</sup>

Incidence of metastatic carcinoma in cervical lymph node rises in direct proportionality to the age of the patient. In elderly patient cervical lymphadenopathy due to metastasis from various primary sites is seen more commonly than due to primary neoplasms.<sup>58, 59</sup>

Metastasis from head and neck region is most commonly seen in patients more than 60 years of age and is associated strongly with history of tobacco and betel nut chewing, smoking and alcohol consumption.<sup>60-63</sup>

Metastasis to axillary group of lymph nodes is seen most frequently from breast carcinoma, melanoma, and squamous cell carcinoma in decreasing order.<sup>27, 64, 65</sup>

Primary malignancies of pelvic and abdominal organs commonly metastasise to left supraclavicular lymph node that is Virchow's node. Ipsilateral lymph node metastasis is seen usually in cases where primary site is mammary gland, lung or head and neck region.<sup>27, 66</sup>

Most of the patients that present with enlarged lymphnode give a clear cut hint towards the location of primary site.

Metastasis to mediastinal lymph node is seen most commonly to arise from lung amounting to more than 80% of malignant mediastinal lymphadenopathy cases. Extra thoracic malignancy can also metastasise to mediastinal lymph nodes. Although, mediastinal lymphadenopathy has equal chances of being benign or malignant.<sup>27</sup>

In decreasing order of frequency, metastatic inguinal lymphadenopathy is seen to arise from skin of the lower extremities, cervix, vulva, skin of the trunk, anus/rectum, ovary, and penis. Various sarcomas, melanomas and metastasis from different

primary sites such as testis, prostate, kidney, bladder, lung and breast are also seen metastasising to inguinal lymph nodes.<sup>27</sup>

Pelvic and genital malignant tumour, malignancy from lower extremities, and various lymphomas metastasize to retroperitoneal and intra-abdominal lymph nodes specifically to lower Para-aortic lymph nodes.<sup>27</sup>

Sometimes lymphadenopathy is found to be the first clinical evidence of malignancy where the primary site is not known.<sup>27</sup>

Patients of Non Hodgkins lymphoma usually present with generalized lymphadenopathy, however sarcoidosis, infectious mononucleosis, autoimmune disorders along with other viral processes may also give rise to a similar clinical picture. This picture can also be seen in AIDS patients with coexisting reactive nonspecific lymphoid hyperplasia, which may be clinically misdiagnosed as NHL.<sup>27,67</sup>

Clinical history and findings on various imaging techniques such as ultrasound and computed tomography CT is very helpful in understanding the malignant involvement of nonpalpable lymph nodes. Use of high-frequency real-time transcutaneous, endoscopic and endobronchial ultrasound is also utilised in assessing the involvement of non palpable lymph nodes in mediastinal, abdominal, and pelvic region.<sup>25, 35, 36</sup>

Size of the lymph nodes greater than 1 cm, having round shape, hypoechogenicity, well defined and sharp margins should be considered as abnormal on ultrasound.

Accuracy of predicting malignancy turns out to be 80% in conditions where all of the above features are observed in lymph node. However, all of these features are seen only in 25% of malignant lymph nodes.<sup>27</sup>

Establishing the presence of metastatic tumour in lymph nodes is essential for the management and prognosis of cancer. Lymph node status is the most crucial indicator of clinical outcome. Anatomic location and number of lymph nodes involved are also important indicators of the process. New methods, such as sentinel lymph node biopsies, have been devised to answer questions of staging. Not infrequently, a lymph node metastasis is discovered before an occult primary tumour is detected. In such cases, to identify the unknown primary tumour, extensive studies of the lymph node metastases, including immunohistochemistry and electron microscopy in addition to detailed cytology and histopathology are often necessary.<sup>68-70</sup>

### **PATHOBIOLOGY OF TUMOR METASTASIS**

Involvement of lymph nodes by metastatic tumour signifies the beginning of a new phase in the progress of a cancer. It indicates that through a succession of molecular changes, cancer cells have acquired phenotypes that enable them to invade, colonize and disseminate.

Metastasis plays a major role in morbidity and mortality associated with tumours. Still the process of dissemination remains unknown to a great extent. To prevent metastasis and provide cure to the cancer patients, it is essential to get more clarification about mechanism of metastasis.<sup>57</sup>

Metastasis of the tumour is a complicated phenomenon which is based on a series of interdependent events. These events begin from detachment of cells from the primary tumour, progression through the matrix of the tumour, penetration through the basement membranes of vessels, dissemination through the vascular flow and finally arrival in remote organs along with formation of independent deposits having their own vascular supply and growth factors for survival. Some believe that primary

tumours are heterogeneous in nature and have the ability for growing autonomously and metastasising to distant organs. Others think that the potential for metastasis arises through mutations generating new variants that are selected during tumour development. The fact that not all malignant tumours are metastatic suggests that the metastatic phenotype is different from and independent of the tumorigenic phenotype.<sup>71</sup>

Process of metastasis is complex and involves multiple steps at the level of genetics. As counterparts of the genes promoting the formation of metastatic phenotypes, metastatic suppressor genes degrade the gene products that favour tumour cell dissemination. Because malignant cells are inherently unstable, their genomes are subject to constant variation, resulting in what is termed phenotypic drift. During cancer development accumulation of genetic changes modulates the sensitivity of neoplastic cells to invasion stimulators and invasion inhibitors to a newly acquired invasive phenotype. Various genes undergo irreversible structural changes (mutations), such as deletions, amplifications, and translocations, which yield altered gene products.<sup>71</sup>

Downregulation of E-cadherins decreases tumour cell cohesiveness; integrins which are helpful in affinity of tumour cells for basement membranes and certain proteolytic enzymes like type IV collagenase, which are required for tumour cell invasiveness. A particular adhesion molecule, CD44, and its variants, which are normally expressed on T lymphocytes, have also been detected on some tumour cells, which suggest a possible role of T lymphocytes in tumour implantation in lymph nodes..<sup>71</sup>

Tumor cells and tumour infiltrating lymphocytes (TIL) are the main cells involved in reciprocal death-inducing activities of primary neoplasm and their metastasis. Tumour

cells and TIL interaction, may result in the apoptosis of either cell. Mechanism of apoptosis is conducted mainly by FAS and its ligand FAS-L. Up regulated expression of FAS-L in the metastatic tumour cells is related to their capacity to fight against anti-tumour immune attack by lymph node TIL. Thus, FAS/FAS-L system is mandatory for the process of apoptosis to take place but it contributes very little in the tumour invasion and anti-tumour defense mechanism. Tumour cells progressively acquire the characteristics necessary for invasion and metastasis, which characterize the metastatic phenotype. Consequently, the success or failure of a tumour to invade and metastasize depends on the interaction of gene products released by stimulatory and inhibitory metastasis genes.<sup>71</sup>

## **TUMOR METASTASIS IN LYMPH NODES**

Antigenicity of tumour cells may initiate and develop complex immune reactions in regional lymph nodes or may entrap circulating tumour cells that have originated in their tributary territories. Lymph nodes act as efficient barriers and help in to destroying invading tumour cells or at least cease their dissemination temporarily.<sup>71</sup>

Appearance of metastatic tumour cells begins in the marginal sinus from where they penetrate the medullary sinuses, medulla, cortex and finally replace complete parenchyma. Even before metastatic tumour cells are present in the lymph node, reactive changes take place which reorganize the microenvironment. Newly discovered vascular endothelial factors such as (VEGF-C and VEGF-D promote tumour-associated lymphangiogenesis which increase the proliferation of endothelial cells in high endothelial venules resulting in blood- and lymph-enriched lymph nodes. Within the lymph nodes, the tumour cells may induce various tissue reactions, such as angiogenesis, reactive follicular hyperplasia, sinus histiocytosis and foreign-body

granuloma formation. Some metastatic tumours elicit intense desmoplastic reactions, which contribute to the partial or total replacement of lymphoid tissue. Finally, radiotherapy or chemotherapy may wipe out lymphoid tissue with the tumour and create an unusual histologic appearance of the affected lymph nodes.<sup>57, 71</sup>

Lymph node metastasis, in contrast to the vascular spread of tumours, presents an opportunity, even if temporary, for surgical intervention. In addition, because of their accessibility, lymph nodes with metastatic tumour present the best opportunity for primary tumour diagnosis through aspiration, biopsy and histopathologic evaluation.<sup>71</sup>

This rapid, simple, inexpensive, relatively painless technique remains a convenient and proficient method of following up patients with known malignancies and also play major role in diagnosing primary site of tumour which further helps in guiding accurate therapy.<sup>72-75</sup>

## **MATERIALS AND METHODS**

### **Materials and methods**

#### **Source of data:**

The study was done on clinically suspected cases of metastatic lymph nodes that were referred for FNAC of lymph nodes to the Cytology section in The Department of Pathology, B.L.D.E. (Deemed to be University) Shri B. M. Patil Medical College, Hospital and Research Centre, Vijayapur.

Study Period : 1<sup>st</sup> September 2016 –31<sup>st</sup> July 2018

#### **Methods of collection of data**

Thorough examination of the patients who were referred to the Cytology Section of Department of pathology for cytological evaluation of clinically suspected cases of metastatic lymph nodes was done and detailed clinical history and consent was taken. Standard FNAC procedure was performed by using Cameco syringe pistol with 10 ml disposable syringe and 23-22G needle and multiple smears were prepared. Smears fixed in alcohol were stained with Haematoxylin and Eosin (H&E) and Papanicolaou stains while air dried smears were stained with May – Grunwald Giemsa (MGG) stain. Special stains like Periodic Acid Schiff (PAS), Mucicarmine and immunohistochemistry (IHC) were done wherever required. Histopathological correlation was done to confirm the diagnosis wherever possible.

#### **Inclusion criteria:**

All clinically suspected cases of metastatic lymph node referred to the cytology section for cytological evaluation during the study period were included.

#### **Exclusion criteria:**

FNAC smears with inadequate material and only haemorrhagic material were excluded.

## STATISTICAL METHODS

### Study design:

A prospective cross-sectional study.

### Sample size:

By using the formula:

$$n = \frac{z^2 p(1-p)}{d^2}$$

where,

Z= z statistic at 5% level of significance

d is margin of error

p is anticipated incidence rate among suspected cases (5 – 25%)<sup>5</sup>

A sample size of 45 subjects was calculated to assess the incidence of metastatic lymph node cases among clinically suspected cases with 95% confidence level and margin of error of ±13% with finite population correction.

81 cases were evaluated in the present study.

### Statistical analysis:

All characteristics were summarized descriptively. For continuous variables, the summary statistics of mean, standard deviation (SD) were used. For categorical data, the number, percentage and McNemar's test were used in the data analyses. Diagrammatic presentation was done wherever needed.

Sensitivity- specificity was done to check relative efficiency by the formulae:

**Sensitivity or True Positivity (TPR)**

eqv. with hit rate, recall

$$\text{TPR} = \text{TP}/\text{P} = \text{TP}/(\text{TP}+\text{FN})$$

**Specificity (SPC) or True negative rate**

$$\text{SPC} = \text{TN}/\text{N} = \text{TN}/(\text{FP}+\text{TN})$$

**Precision or Positive predictive value (PPV)**

$$\text{PPV} = \text{TP}/(\text{TP}+\text{FP})$$

**Negative predictive value (NPV)**

$$\text{NPV} = \text{TN}/(\text{TN}+\text{FN})$$

If the p-value was < 0.05, then the results were considered statistically significant.

Data were analyzed using SPSS software v.23.0. and Microsoft office.

## RESULTS

The study was conducted on 81 clinically suspected cases of metastatic lymph nodes from 1<sup>st</sup> September 2016 to 31<sup>st</sup> July 2018. Fine needle aspiration was done in all cases. Observations of cytological study were described and wherever possible correlated with histopathology findings.

**TABLE 1: AGE AND SEX DISTRIBUTION (n=81)**

Sr. No.	Age Group (Years)	Total Number		No. of Males		No. of Females	
		No.	Percentage	No.	Percentage	No.	Percentage
1	25-45	17	21%	9	11.1%	8	9.9%
2	46-65	46	56.8%	35	43.2%	11	13.6%
3	66-85	18	22.2%	12	14.8%	6	7.4%
		81	100	56	69.1%	25	30.9%

- The age group of the patients ranged from 25 years to 85 years with maximum number of cases in the range of 46-65 years amounting to 56.8%
- The gender preponderance was found to be skewed towards male having M: F ratio of 2.2: 1. Median age was 60 yrs.

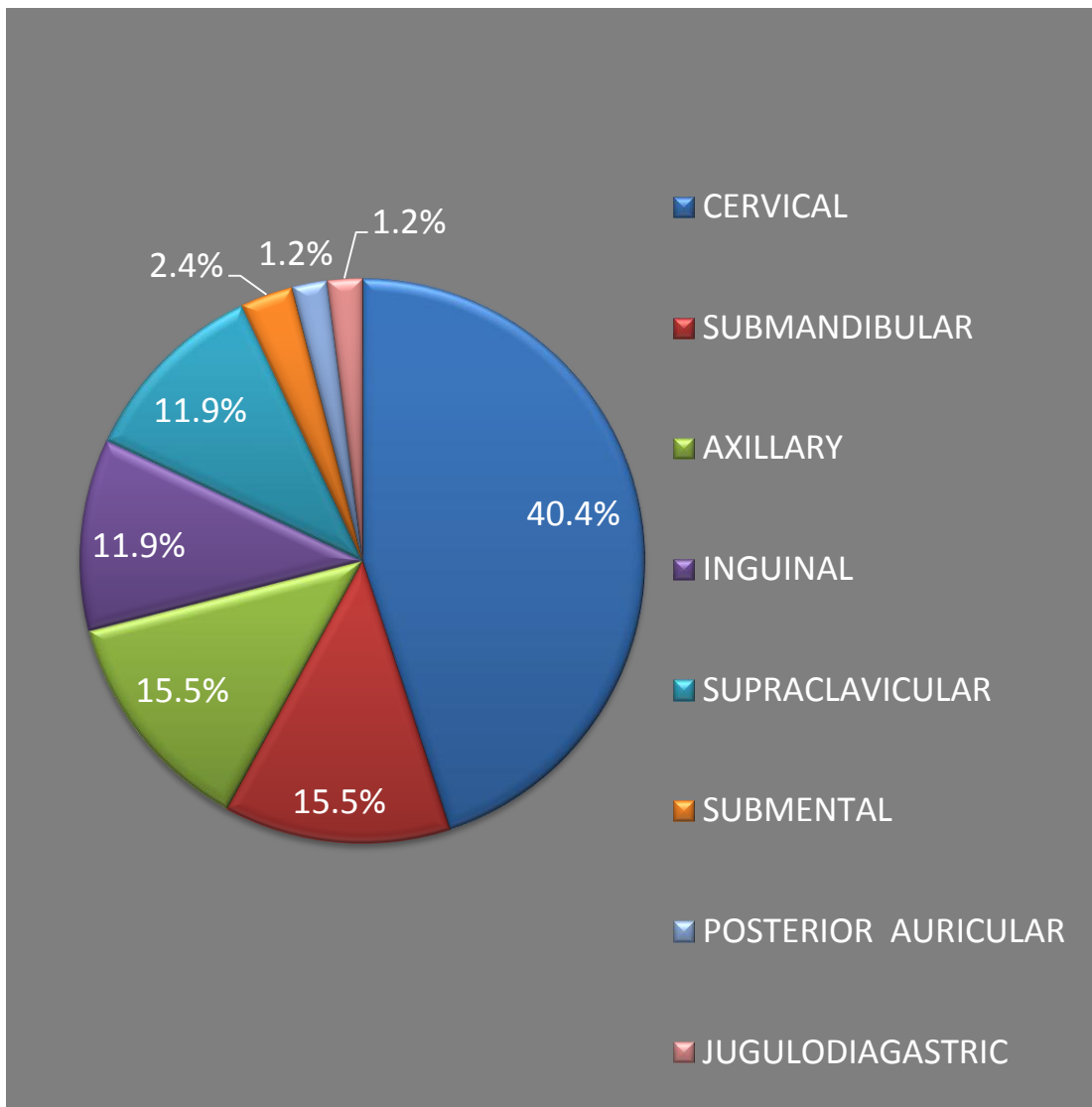
**TABLE 2: DISTRIBUTION OF ANATOMICAL SITES OF LYMPH NODES (n=84)**

<b>S.No.</b>	<b>Anatomical sites of lymph node</b>	<b>Number of cases</b>	<b>Percentage</b>
1	Cervical lymph node	34	40.4%
2	Submandibular lymph node	13	15.5%
3	Axillary lymph node	13	15.5%
4	Inguinal lymph node	10	11.9%
5	Supraclavicular lymph node	10	11.9%
6	Submental lymph node	2	2.4%
7	Posterior auricular lymph node	1	1.2%
8	Jugulodiagastric lymph node	1	1.2%

In the present study most common lymph node metastasis was observed in cervical lymph node followed by submandibular and axillary lymph nodes. In one case each of jugulodiagastric and posterior auricular lymph node metastasis was suspected clinically.

In 3 cases two anatomical site of lymph nodes were involved.

**TABLE 3: PIE DIAGRAM SHOWING DISTRIBUTION OF ANATOMICAL SITES OF LYMPHNODES**



Commonest group of metastatic lymph node in the present study was cervical group of lymph node amounting to 40.4%.

**TABLE 4: CYTOLOGICAL DIAGNOSIS IN CLINICALLY SUSPECTED CASES OF METASTATIC LYMPH NODES (n=81)**

S.No	Cytological diagnosis	Total	Percentage
1	Metastatic squamous cell carcinoma (Mets SCC)	43	53.1%
2	Metastatic infiltrating ductal carcinoma /Invasive lobular carcinoma (Mets IDC/Invasive lobular Ca)	12	14.8%
3	Metastatic poorly differentiated carcinoma (Mets poorly diff Ca)	8	9.8%
4	Metastatic adenocarcinoma (Mets Adeno Ca)	3	3.8%
5	Metastatic adenosquamous carcinoma (Mets Adenosquamous Ca)	3	3.8%
6	Reactive lymphadenitis	6	7.4%
	Granulomatous lymphadenitis	1	1.2%
7	Non Hodgkins lymphoma (NHL)	2	2.5%
8	Metastatic nasopharyngeal carcinoma	1	1.2%
9	Metastatic follicular carcinoma	1	1.2%
10	Metastatic malignant melanoma	1	1.2%

Out of 81 clinically suspected cases of metastatic lymphadenopathy in 72 cases diagnosis of metastatic lymphadenopathy was given on cytology.

In remaining 09 cases diagnosis of reactive lymphadenitis was given in 6 cases, granulomatous lymphadenitis in 1 case and diagnosis of NHL was given in 2 cases.

Metastatic squamous cell carcinoma was the commonest cytological diagnosis followed by metastatic infiltrating ductal carcinoma.

**TABLE 5: DISTRIBUTION OF CASES ACCORDING TO PRIMARY SITE (n= 42)**

<b>S.No.</b>	<b>Primary site</b>	<b>Number of cases</b>	<b>Percentage</b>
1	Oral cavity	14	33.3%
2	Breast	12	28.6%
3	Pharynx	4	9.5%
4	Larynx	3	7.1%
5	Penis	3	7.1%
6	Thyroid	2	4.8%
7	Growth over mandible	1	2.4%
8	Sole	1	2.4%
9	Lung	1	2.4%
10	Anus	1	2.4%

Out of 72 cases of metastatic lymphadenopathy diagnosed on cytology, primary site was suggested in 42 (amounting to 58%) cases by correlating with clinical features. In remaining 30 cases that is 42% primary site was not known.

Commonest primary site of malignancy was oral cavity followed by breast. Metastasis from pharynx was noted in 4 cases and larynx in 3 cases.

**TABLE 6: DISTRIBUTION ACCORDING TO PRIMARY SITE WITH CYTOLOGICAL DIAGNOSIS (n=42)**

S.No.	Primary site	Number of cases	Cytological Diagnosis
1	Oral cavity	14	<ul style="list-style-type: none"> <li>• SCC -13</li> <li>• Poorly diff Ca – 01</li> </ul>
2	Breast	12	<ul style="list-style-type: none"> <li>• IDC -11</li> <li>• Invasive Lobular Ca -01</li> </ul>
3	Pharynx	4	<ul style="list-style-type: none"> <li>• SCC- 03</li> <li>• Nasopharyngeal Ca - 01</li> </ul>
4	Larynx	3	<ul style="list-style-type: none"> <li>• SCC</li> </ul>
5	Penis	3	<ul style="list-style-type: none"> <li>• SCC</li> </ul>
6	Thyroid	2	<ul style="list-style-type: none"> <li>• Follicular Ca</li> <li>• Poorly diff Ca</li> </ul>
7	Growth over mandible	1	<ul style="list-style-type: none"> <li>• SCC</li> </ul>
8	Sole	1	<ul style="list-style-type: none"> <li>• Malignant melanoma</li> </ul>
9	Lung	1	<ul style="list-style-type: none"> <li>• Adenosquamous Ca</li> </ul>
10	Anal canal	1	<ul style="list-style-type: none"> <li>• SCC</li> </ul>

In cervical and submandibular lymph nodes squamous cell carcinoma of oral cavity, pharynx and larynx was the commonest primary malignancy.

**TABLE 7: DISTRIBUTION OF PRIMARY SITE IN CERVICAL LYMPH NODES (n=32)**

<b>Primary site</b>	<b>Cytological diagnosis</b>	<b>No. of cases</b>	<b>Percentage</b>
Oral cavity	SCC Tongue -04, SCC oral cavity – 01, SCC Cheek – 01	6	18%
Pharynx	Nasopharyngeal Ca -01 SCC Hypopharynx,01, SCC Pyriform fossa 01, SCC Posterior pharyngeal wall 01.	4	12%
Breast	IDC	2	6%
Tonsil	SCC	1	3%
Thyroid	Poorly diff Ca	1	3%
Unknown	1.SCC – 12 2. Poorly diff Ca - 05 3. Adenosquamous Ca – 01	18	58%

In cervical lymph node, out of 32 cases primary site of metastasis was known in 14 cases. Most common primary was squamous cell carcinoma of oral cavity followed by squamous cell carcinoma of pharynx. In remaining 18 cases primary was not known.

**TABLE 8: DISTRIBUTION OF PRIMARY SITE IN SUBMANDIBULAR LYMPH NODES (n=13)**

<b>Primary site</b>	<b>Cytological diagnosis</b>	<b>No. Of cases</b>	<b>Percentage</b>
Oral Cavity	SCC	5 (Tongue -02, Cheek - 02, Buccal mucosa -01)	38%
Larynx	SCC	2 (Epiglottis -01, Hypoglottis -01)	16%
Growth over mandible	SCC	1	8%
Unknown	SCC	5	38%

Most common primary was from (oral cavity) tongue and cheek squamous cell carcinoma. Primary was unknown in 38% of the cases.

**TABLE 9: DISTRIBUTION OF PRIMARY SITE IN INGUINAL LYMPH  
NODES (n= 6)**

<b>Primary site</b>	<b>Cytological diagnosis</b>	<b>No. of cases</b>	<b>Percentage</b>
Penis	SCC	3	52%
Anal Canal	SCC	1	16%
Sole	Malignant Melanoma	1	16%
Unknown	Adenocarcinoma	1	16%

Most common primary site was penis in metastatic inguinal lymph node. One case of malignant melanoma of sole metastatised to inguinal lymph node. Also one metastasis was noted from SCC of anal canal.

**TABLE 10: DISTRIBUTION OF PRIMARY SITE IN SUPRACLAVICULAR LYMPH NODES (n= 9)**

<b>Primary site</b>	<b>Cytological diagnosis</b>	<b>No. Of cases</b>	<b>Percentage</b>
Larynx	SCC	1	11%
Lung	Adenosquamous Ca	1	11%
Unknown	SCC	2	78%
	Adenocarcinoma	2	
	Adenosquamous Ca	1	
	Poorly diff Ca	1	
	NHL	1	

One case each of lung and laryngeal malignancy were found to metastasise to supraclavicular lymph node. In 78% of cases, primary site was not known.

All cases of metastasis to axillary lymph node were from breast as infiltrating ductal carcinoma except one case of invasive lobular carcinoma. One clinically suspected metastatic axillary lymph node was found to be reactive lymphadenitis.

Out of two case of submental lymph node metastasis, one case was of follicular carcinoma of thyroid and other one was squamous cell carcinoma of buccal mucosa.

One case each of posterior auricular lymph node and jugulodiagastric lymph node metastasis were noted from poorly diff Ca of oral cavity and SCC of tongue respectively.

**TABLE 11: CATEGORIZATION OF CYTOLOGICAL DIAGNOSIS IN CLINICALLY SUSPECTED CASES OF METASTATIC LYMPH NODE (n=81)**

<b>Features</b>	<b>Clinical Diagnosis</b>	<b>Cytological Diagnosis</b>	<b>Percentage</b>
<b>Metastatic</b>	81	72	88.9%
<b>Primary</b>	00	02	2.5%
<b>Reactive</b>	00	06	7.4%
<b>Granulomatous</b>	00	01	1.2%

**TABLE 12: CORRELATION BETWEEN CLINICAL AND CYTOLOGICAL DIAGNOSIS**

	<b>Concordance</b>	<b>Discordance</b>
<b>Number of cases</b>	72	09
<b>Percentage</b>	88.9%	11.1%

Out of 81 clinically suspected cases of metastatic lymphadenopathy, 72 cases were showing concordance on cytology. In 9 cases discordance was observed. One case was of granulomatous lymphadenitis, 2 cases of Non Hodgkins Lymphoma and 6 cases were of reactive lymphadenitis.

Four clinically suspected cases of penile carcinoma metastasising to inguinal lymph node were found to be reactive.

One case of suspected metastatic oral carcinoma to supraclavicular lymph node was found to be reactive.

One case suspicious of metastatic breast carcinoma turned out to be reactive.

One case of suspected metastatic cervical lymphadenopathy was reported as granulomatous inflammation on cytology.

Two cases suspicious of metastasis turned out to be Non Hodgkins Lymphoma.

**TABLE13: DETAILS OF DISCORDANT CASES ON CYTOLOGY AND HISTOPATHOLOGY (n=7)**

<b>Cytology</b>	<b>Histopathology</b>	<b>Number of cases</b>
Mets adenocarcinoma	Sarcoma	01
Met SCC	Suppurative lesion	01
Met adenocarcinoma	Met SCC	01
Reactive lymphadenitis	Necrotizing granulomatous lymphadenitis	01
Poorly diff ca	SCC	02
Poorly diff ca	Adenocarcinoma	01

**TABLE 14: CYTOLOGICAL AND HISTOPATHOLOGICAL CORRELATION (n = 37)**

	<b>Concordance</b>	<b>Discordance</b>
Number of cases	30	07
Percentage	81%	19%

Out of 81 cases, histopathology correlation was available in 37 cases. Cytological diagnosis was correlating in 81% of the cases and was discordant in 19% of cases.

One case of clinically suspected metastatic inguinal lymphadenopathy on cytology was reported as metastatic adenocarcinoma which turned out to be sarcoma of inguinal region on histopathology.

One case of suspected SCC of hypopharynx metastatising to cervical lymph node on cytology was reported as metastatic SCC but on histopathology turned out to be acute suppurative lesion.

One case of Mets adenocarcinoma of left supraclavicular lymph node on cytology was reported as Mets SCC on histopathology.

One case suspected as metastasis to left inguinal lymph node was reported as reactive lymphadenitis on cytology and necrotising granulomatous lymphadenitis suggestive of tuberculosis on histopathology.

Three cases reported as poorly diff Ca on cytology were diagnosed as SCC in 2 cases and adenocarcinoma in one case on histopathology.

Considering histopathological diagnosis as gold standard comparison was done between clinically suspected cases of metastatic lymph node and cytological diagnosis in clinically suspected cases of metastatic lymph node.

**TABLE 15: STATISTICAL ANALYSIS OF CLINICAL, CYTOLOGICAL AND HISTOPATHOLOGICAL DIAGNOSIS (n =37)**

	<b>Clinical diagnosis</b>	<b>Cytological diagnosis</b>	<b>Histopathological diagnosis</b>
<b>Positive</b>	37	36	35
<b>Negative</b>	00	01	02

<b>TP (true positive)</b>	35
<b>FN (false negative)</b>	0
<b>FP (false positive)</b>	1
<b>TN (true negative)</b>	1

<b>Sensitivity</b>	100.00%
<b>Specificity</b>	50.00%
<b>PPV</b>	97.22%
<b>NPV</b>	100.00%
<b>Accuracy</b>	97.30%

Sensitivity is calculated as:

$$= TP/(TP+FN)*100$$

$$= 35/(35+0)*100$$

$$= 100\%$$

Specificity is calculated as:

$$= TN/(FP+TN)*100$$

$$= 1/(1+1)*100$$

$$= 50\%$$

Positive predictive value is calculated as:

$$= TP/(TP+FP)*100$$

$$= 35/(35+1)*100$$

$$= 97.22\%$$

Negative predictive value is calculated as:

$$= TN/(TN+FN)*100$$

$$= 1/(1+0)*100$$

$$= 100\%$$

Accuracy is calculated as:

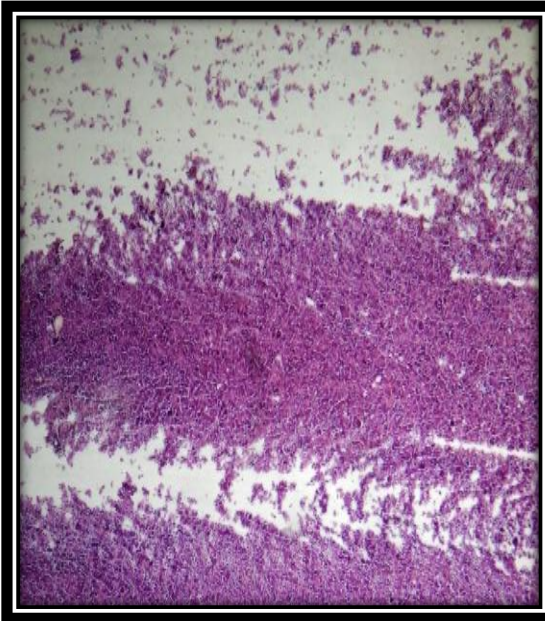
$$= (TP+ TN)/(TP+TN+FN+FP)*100$$

$$= (TP+ TN)/(TP+TN+FN+FP)*100$$

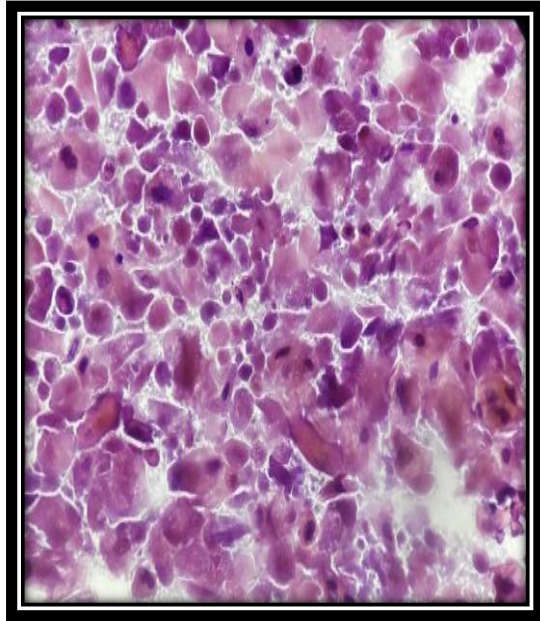
$$= (35+ 1)/(35+1+0+1)*100$$

$$= 97.30\%$$

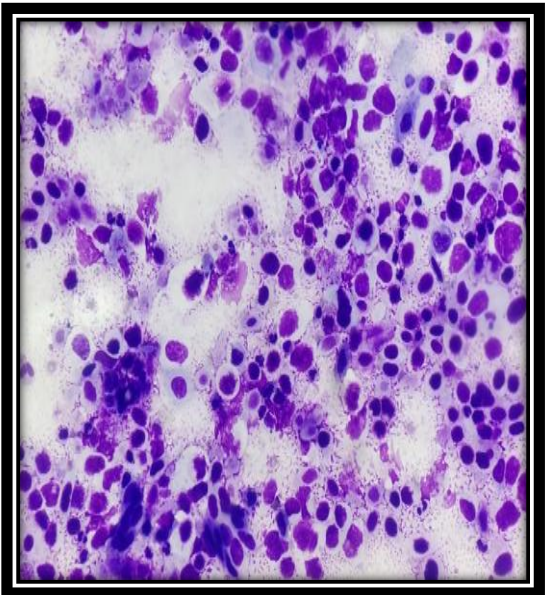
## PHOTOMICROGRAPHS



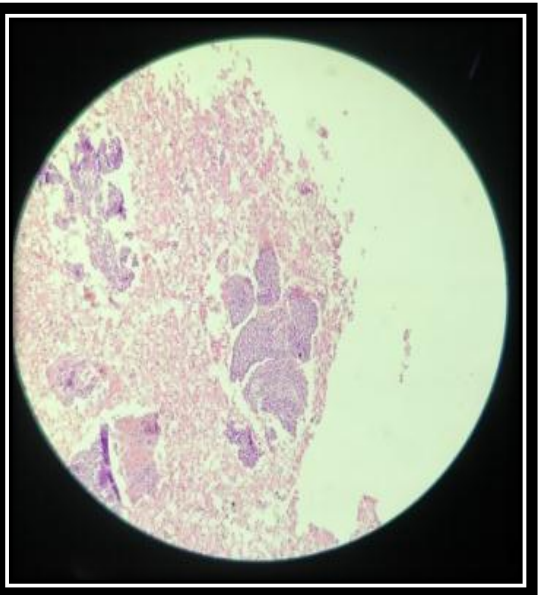
**Fig. 1** – Cytology of mets SCC in cervical LN (PAP Stain, 100x)



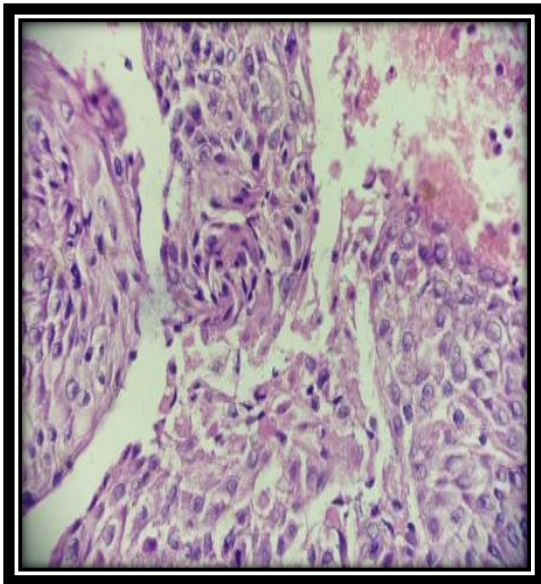
**Fig. 2** – Cytology of mets SCC in cervical LN (PAP Stain, 400x)



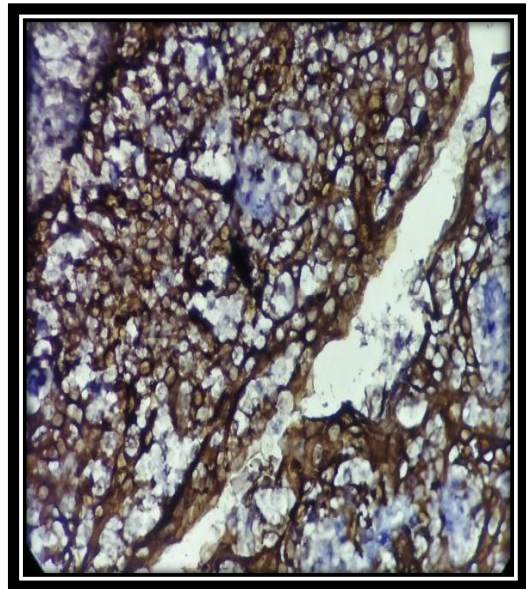
**Fig. 3** – Cytology of mets SCC in cervical LN (Geimsa Stain, 400x)



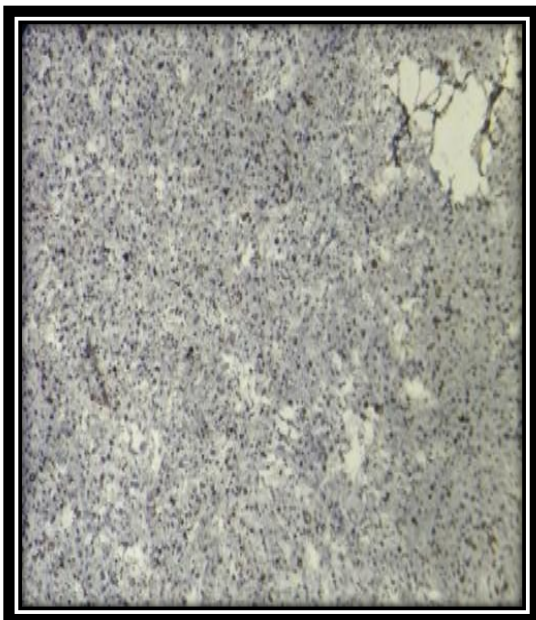
**Fig. 4** –Histopathology (cell block ) of mets SCC in cervical LN. (H&E stain, 100x)



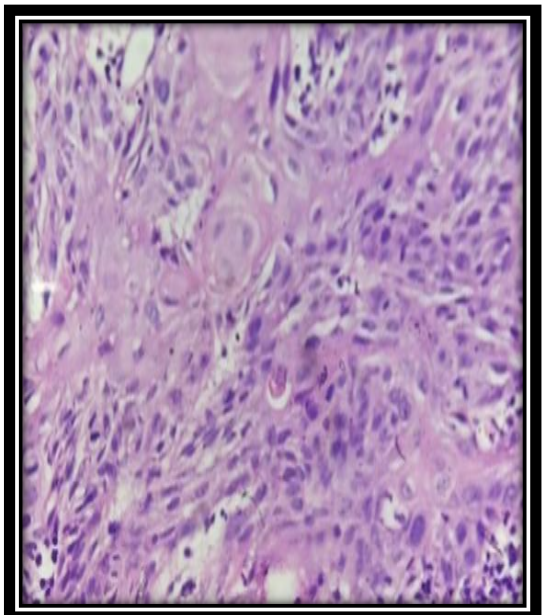
**Fig. 5** – Histopathology (cell block) of mets SCC in cervical LN. (H&E stain, 400x)



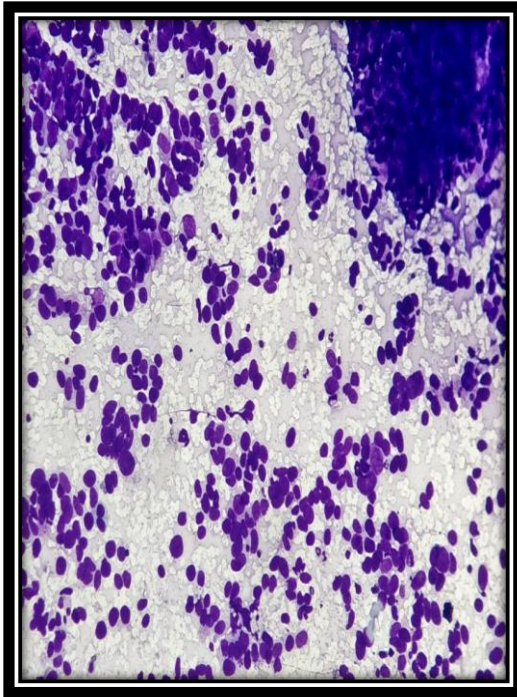
**Fig.6** - IHC showing SCC positive for CK (400x)



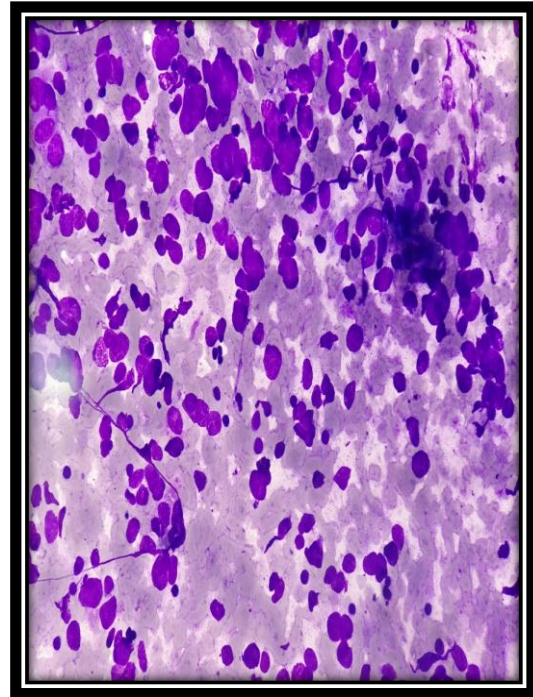
**Fig. 7** – IHC showing SCC negative for CD45 (100x)



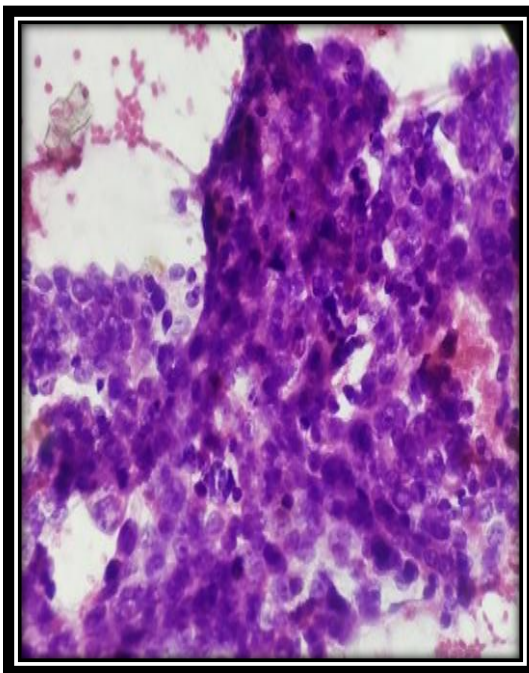
**Fig. 8** – Histopathology of primary site : oral cavity SCC. (H&E stain, 400x)



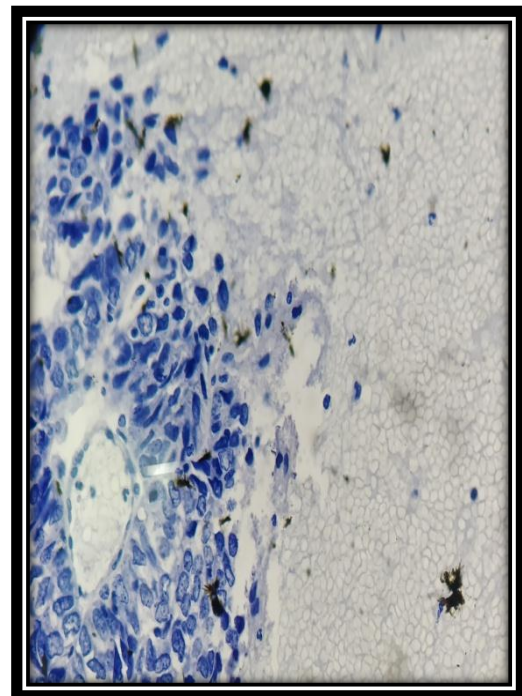
**Fig.9** – Cytology of mets poorly diff Ca (Geimsa stain, 100x)



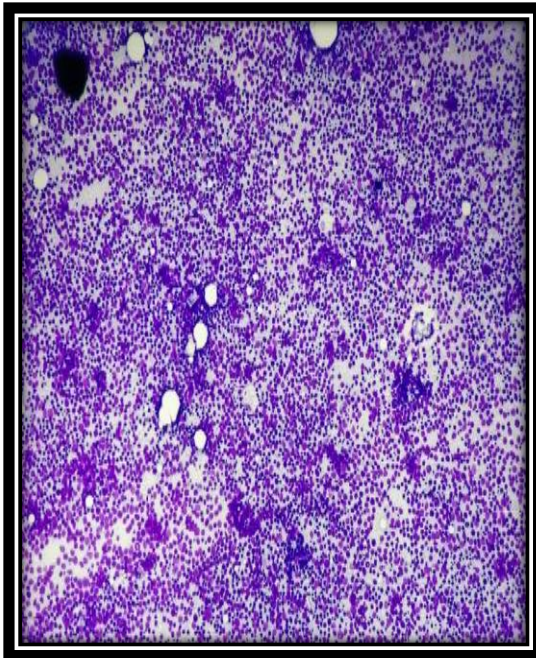
**Fig.10** - Cytology of mets poorly diff Ca (Geimsa stain, 400x)



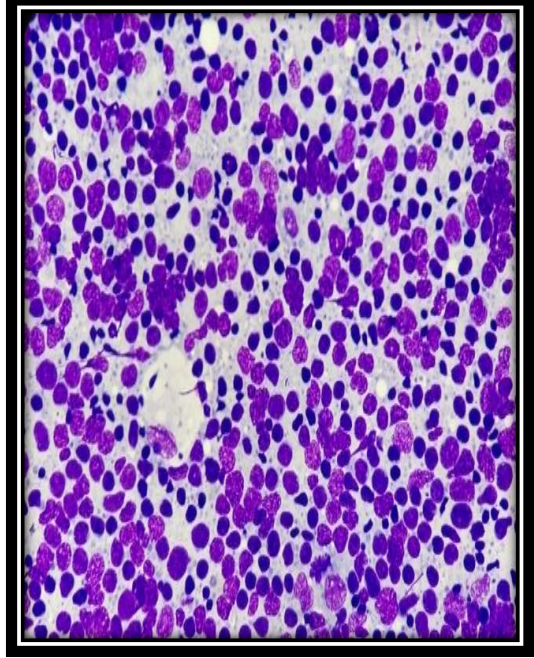
**Fig. 11** – Histopathology (cell block) of mets poorly diff Ca (Pap stain, 400x)



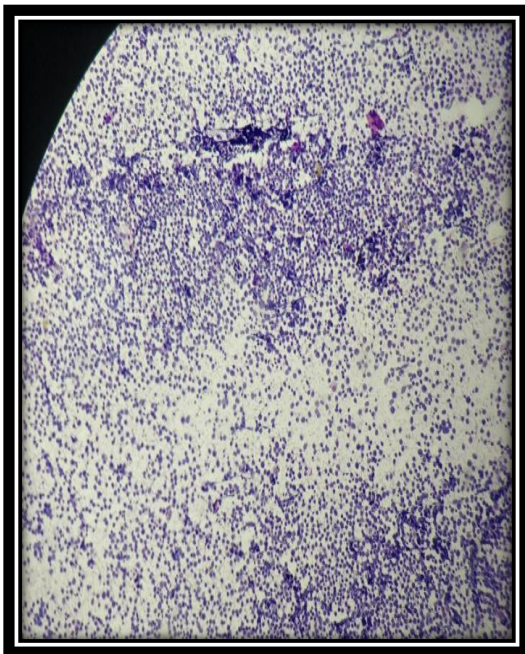
**Fig. 12** – IHC of mets poorly diff Ca negative for CD45 (400x)



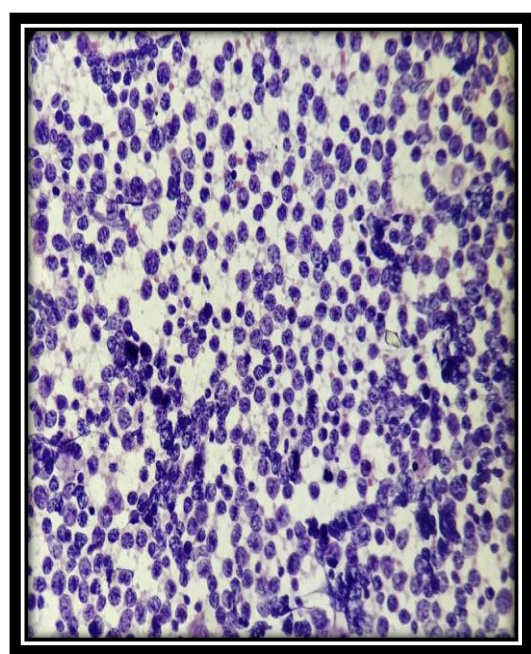
**Fig. 13** – Cytology of NHL in cervical LN (Geimsa stain, 100x)



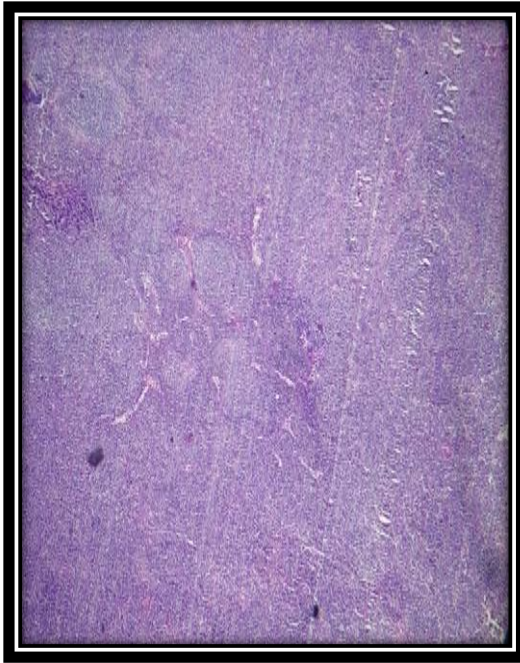
**Fig. 14** – Cytology of NHL in cervical LN (Geimsa stain, 400x)



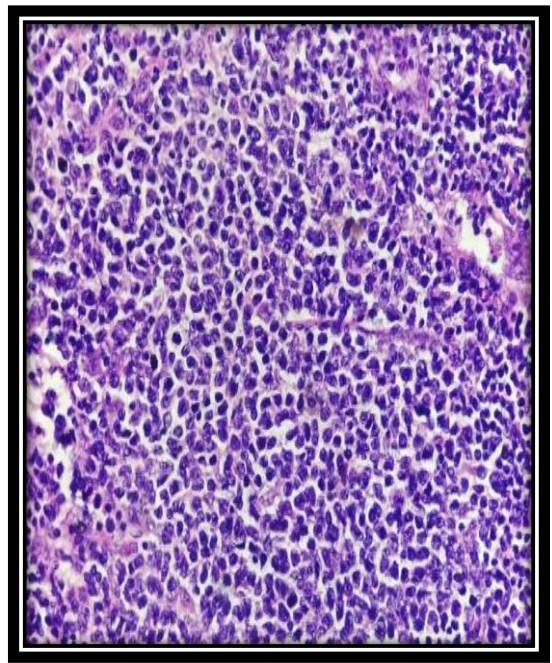
**Fig. 15** - Cytology of NHL in cervical LN (Pap stain, 100x)



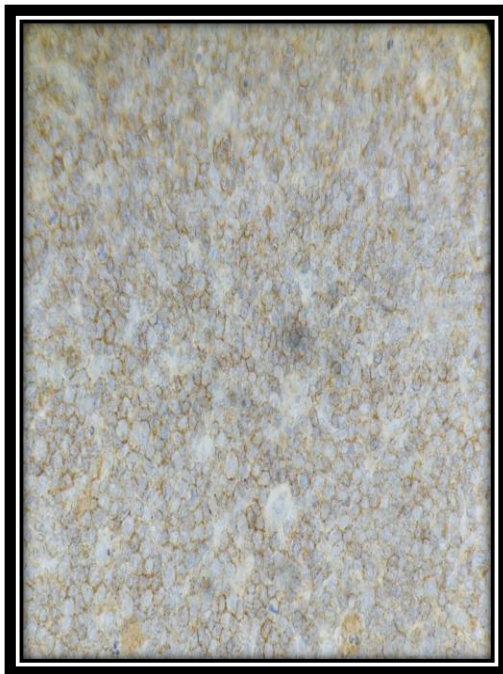
**Fig. 16** - Cytology of NHL in cervical LN (Pap stain, 400x)



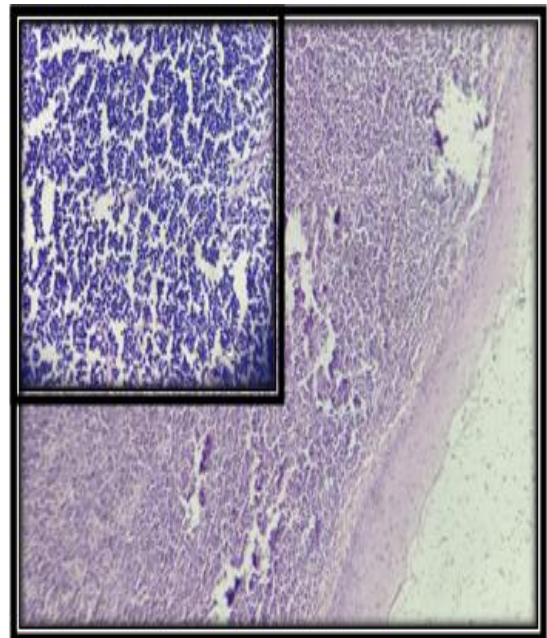
**Fig. 17** - Histopathology of NHL in cervical lymph node (H&E stain, 100x)



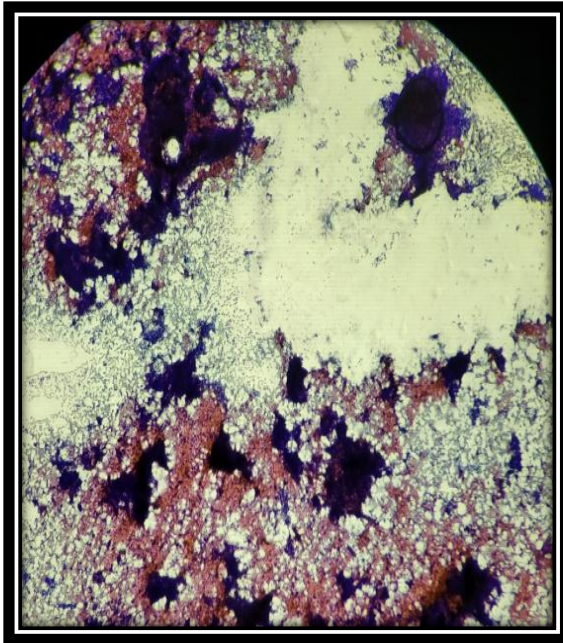
**Fig. 18** - Histopathology of NHL in cervical lymph node (H&E stain, 400x)



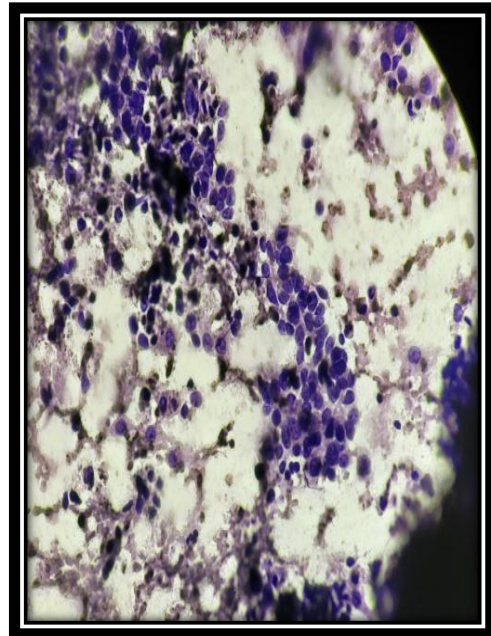
**Fig. 19** -IHC showing diffuse CD45 positivity in NHL of Cervical LN (100x)



**Fig. 20** - Histopathology of NHL tonsil (H&E stain, 100x & Inset: 400x)



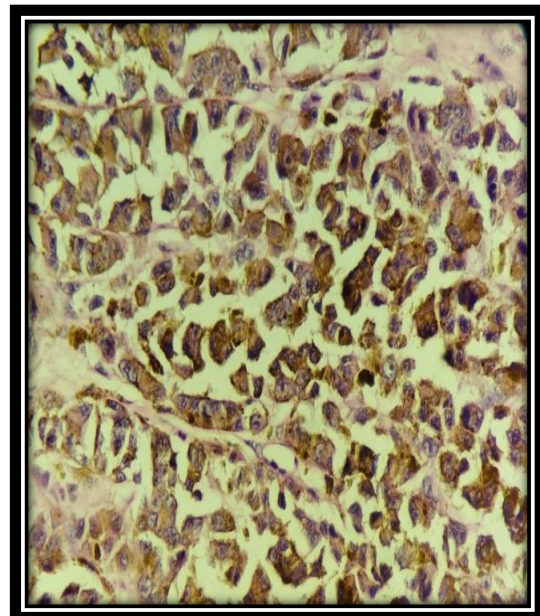
**Fig. 21** - Cytology of mets malignant melanoma in inguinal LN (Geimsa stain, 100x)



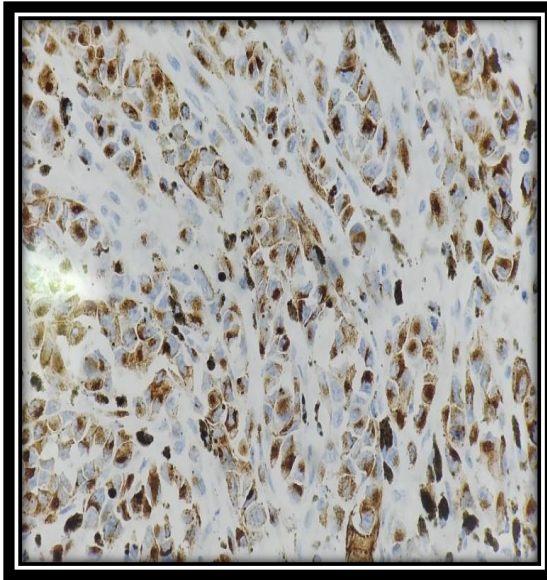
**Fig. 22** - Cytology of mets malignant melanoma in inguinal LN (Geimsa stain, 400x)



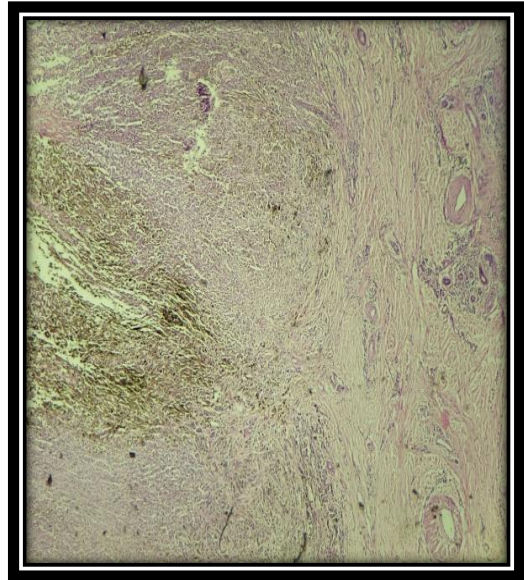
**Fig. 23** Histopathology of mets malignant melanoma in inguinal LN (H&E stain, 100x)



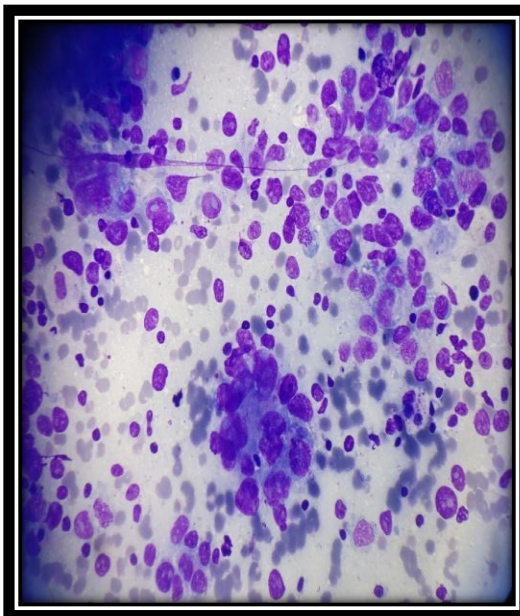
**Fig. 24** Histopathology of mets malignant melanoma in inguinal LN (H&E stain, 400x)



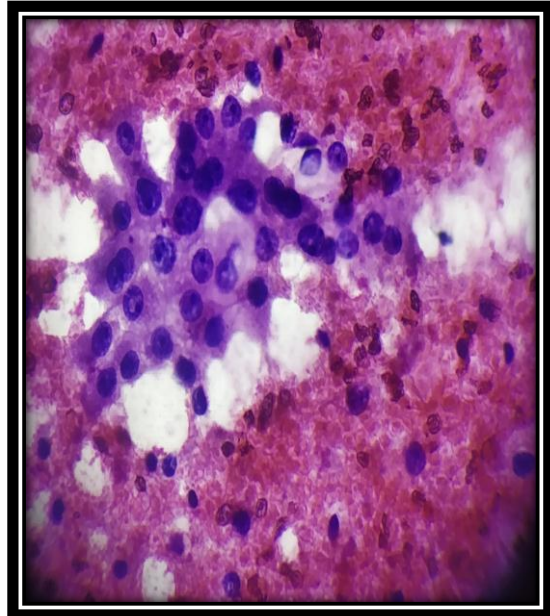
**Fig. 25** –IHC showing diffuse HMB 45 positivity in mets malignant melanoma in inguinal LN (400x)



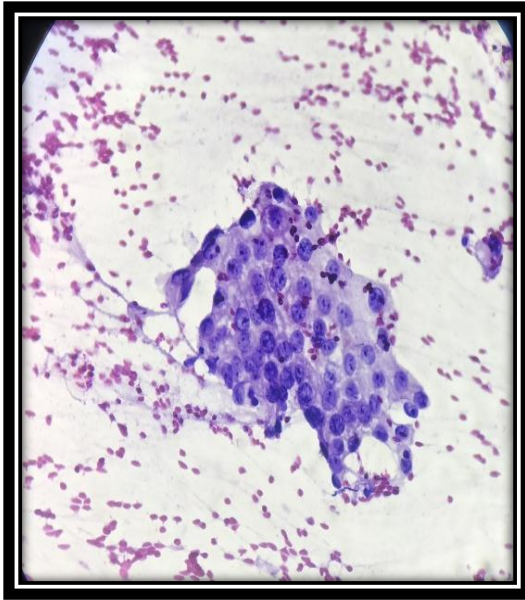
**Fig. 26** - Histopathology of primary site : malignant melanoma of sole. (H&E stain, 100x)



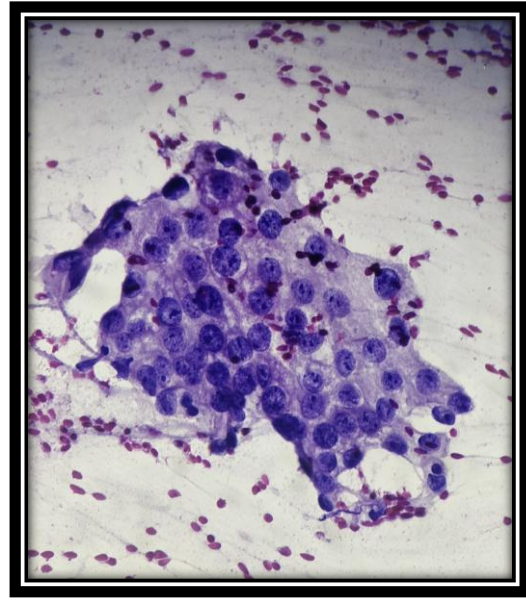
**Fig. 27** – Cytology of mets follicular carcinoma in submental LN (Geimsa stain, 100x)



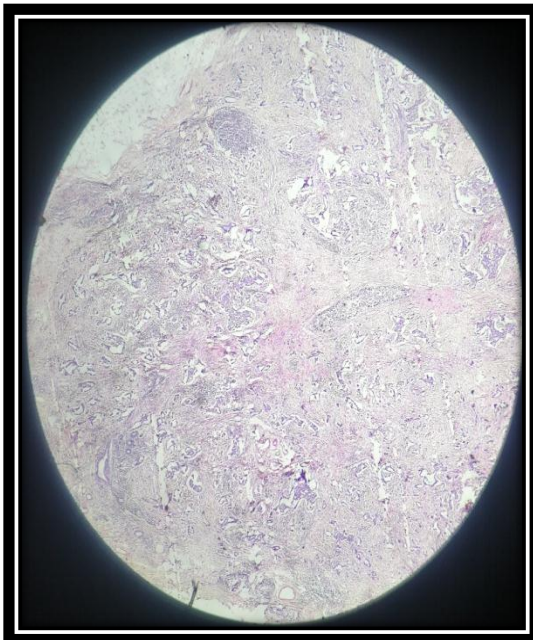
**Fig. 28** - Cytology of primary site: follicular carcinoma of thyroid gland (Pap stain, 400x)



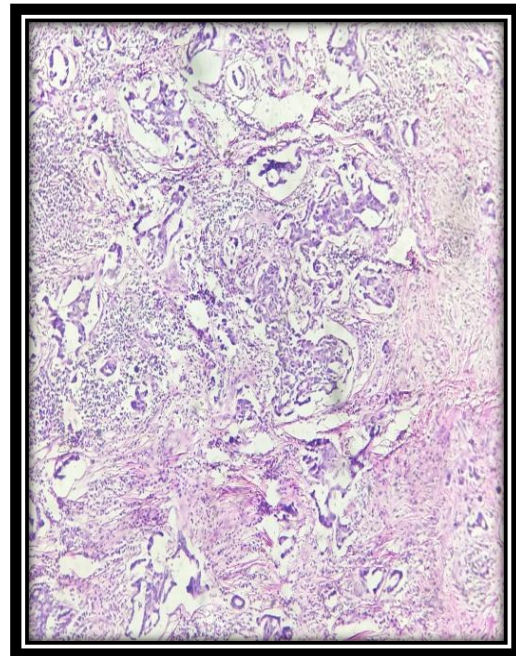
**Fig. 29** - Cytology of mets IDC in axillary LN (Pap stain, 100x)



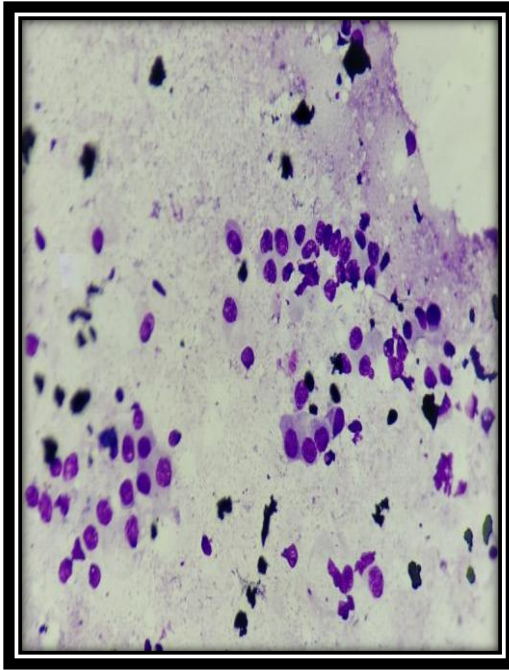
**Fig. 30** - Cytology of mets IDC in axillary LN (Pap stain, 400x)



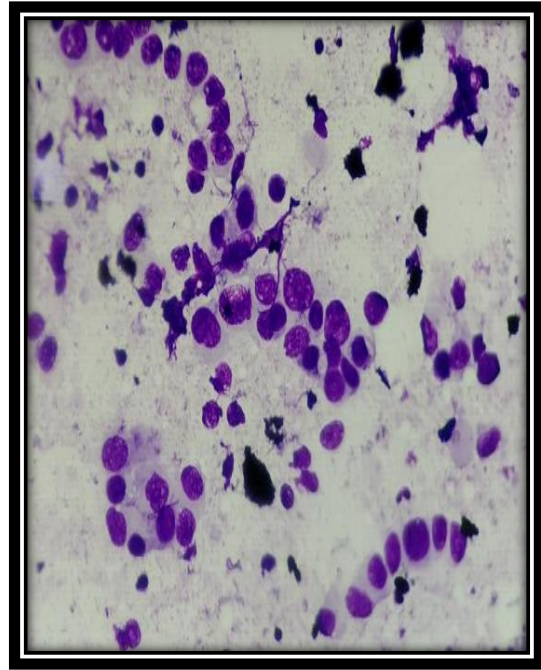
**Fig. 31** – Histopathology of primary site: IDC Breast. (H&E stain, 100x)



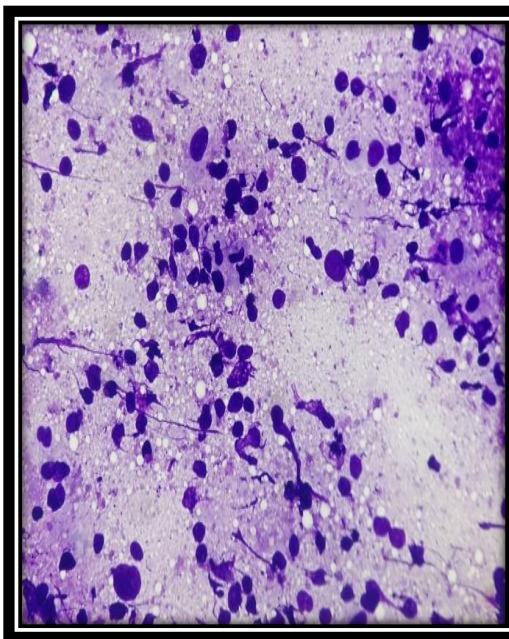
**Fig. 32** – Histopathology of primary site: IDC Breast. (H&E stain, 400x)



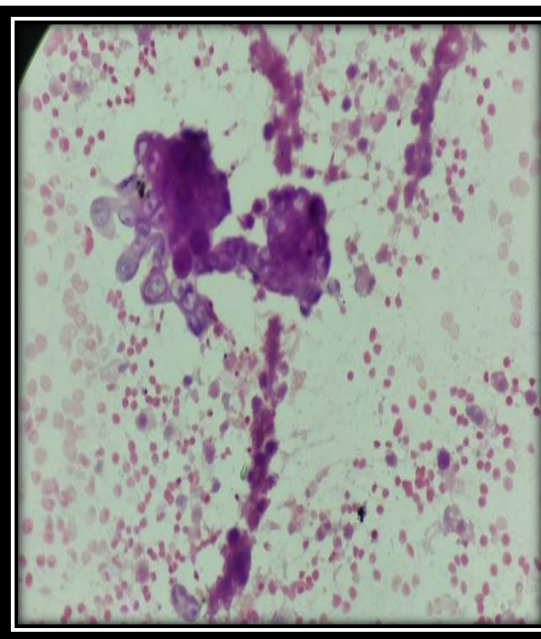
**Fig. 33** - Cytology of mets lobular carcinoma in axillary LN (Geimsa stain, 100x)



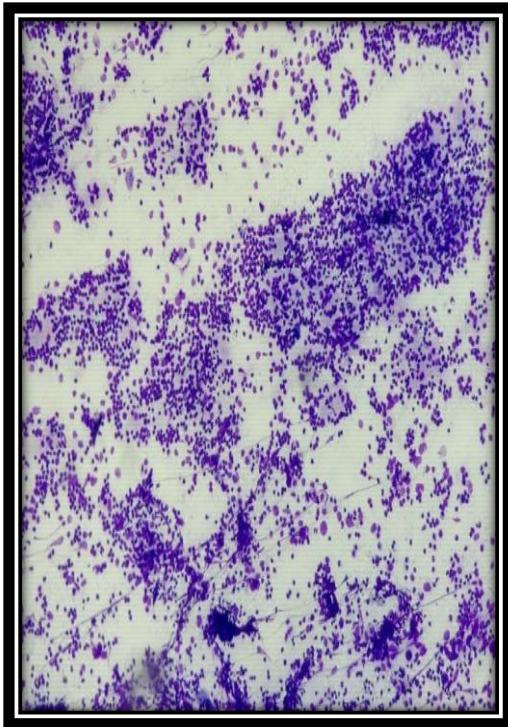
**Fig. 34** - Cytology of mets lobular carcinoma in axillary LN (Geimsa stain, 400x)



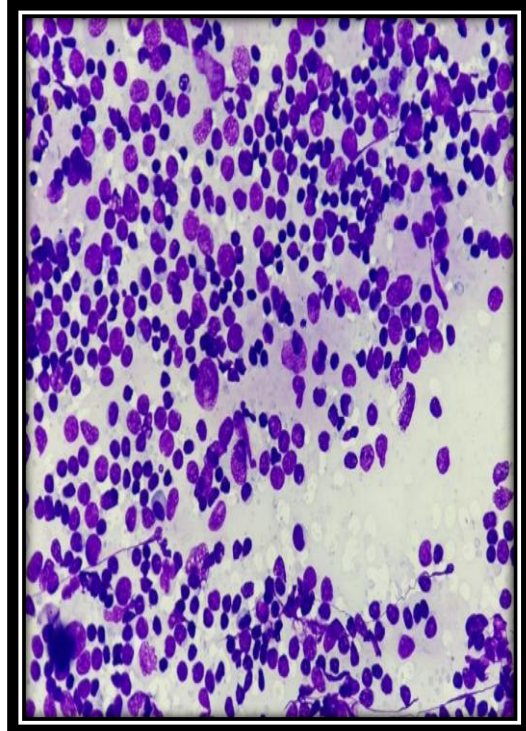
**Fig. 35** - Cytology of adenosquamous carcinoma (Geimsa stain, 400x)



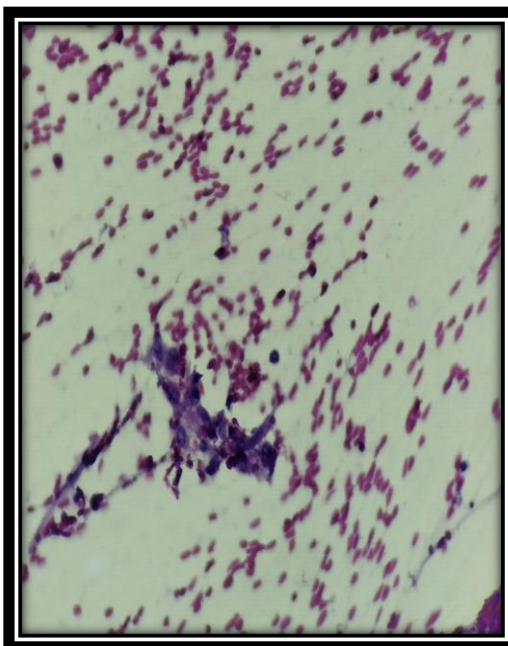
**Fig. 36** - Cytology of adenosquamous carcinoma (Pap stain, 400x)



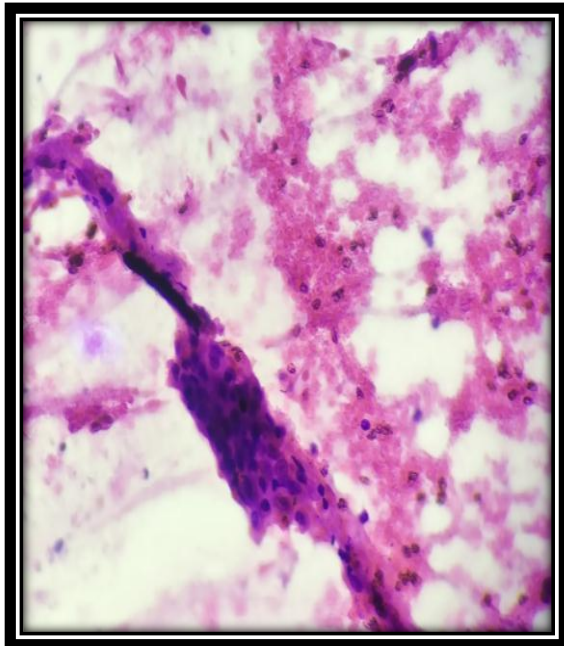
**Fig. 37** - Cytology of mets nasopharyngeal carcinoma in cervical LN (Geimsa stain, 100x)



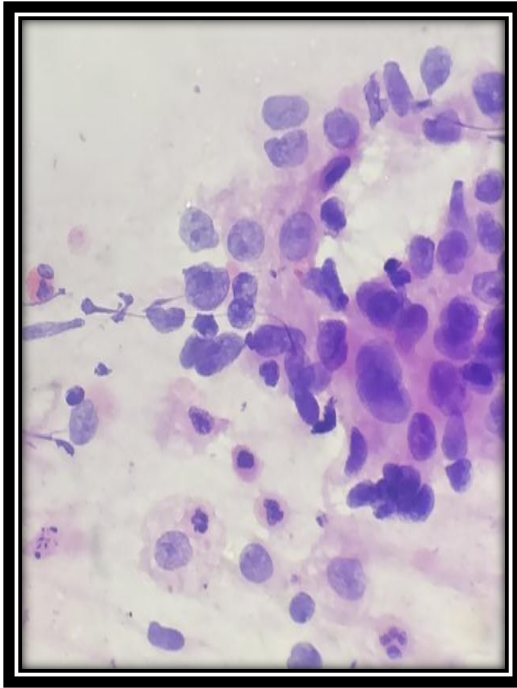
**Fig. 38** - Cytology of mets nasopharyngeal carcinoma in cervical LN (Geimsa stain, 400x)



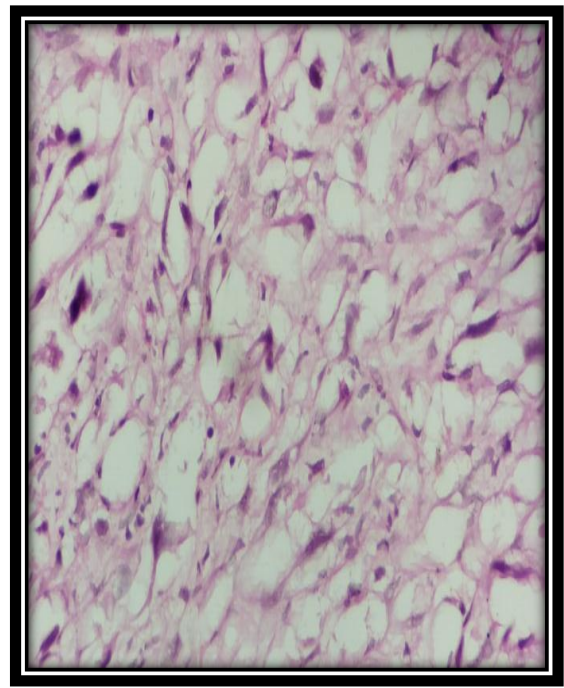
**Fig. 39** - Cytology of mets nasopharyngeal carcinoma in cervical LN (Pap stain, 100x)




**Fig. 40** - Cytology of mets nasopharyngeal carcinoma in cervical LN (Pap stain, 100x)



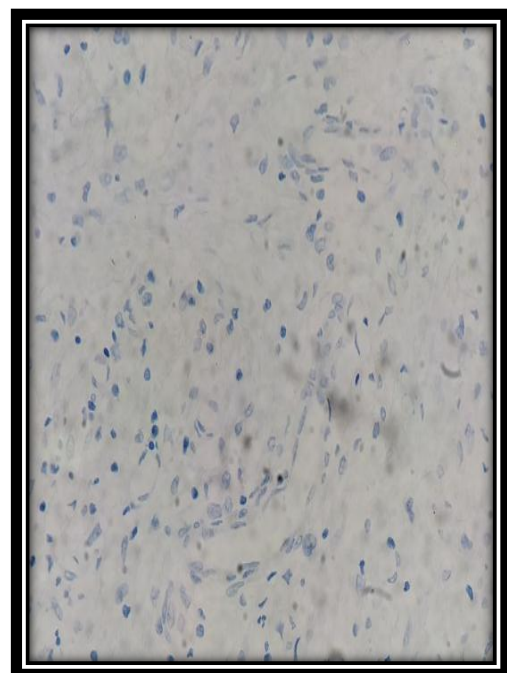
**Fig 41-** Cytology of mets adeno Ca in inguinal LN (Pap stain,) 400x



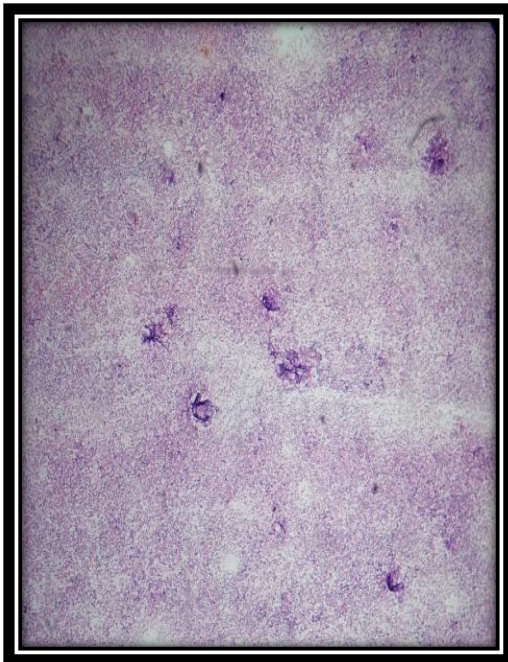
**Fig. 42** – Histopathology showing features of sarcoma of inguinal region in clinically suspected mets Ca (H&E stain, 400x).



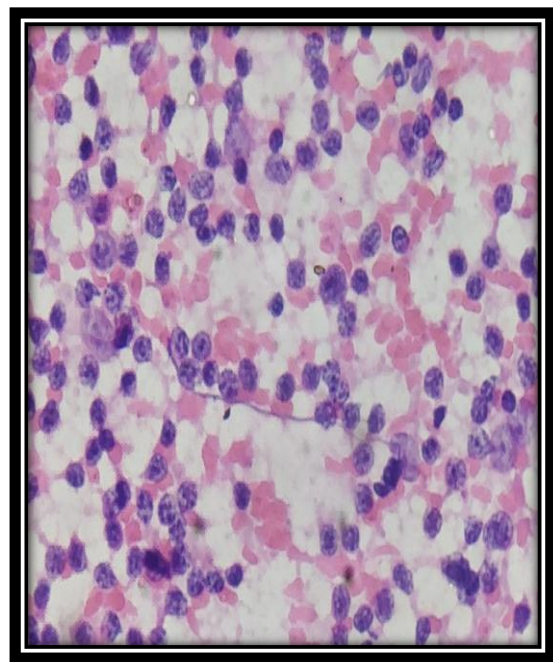
**Fig. 43** – IHC showing Pan CK negativity on histopathology section (100x).



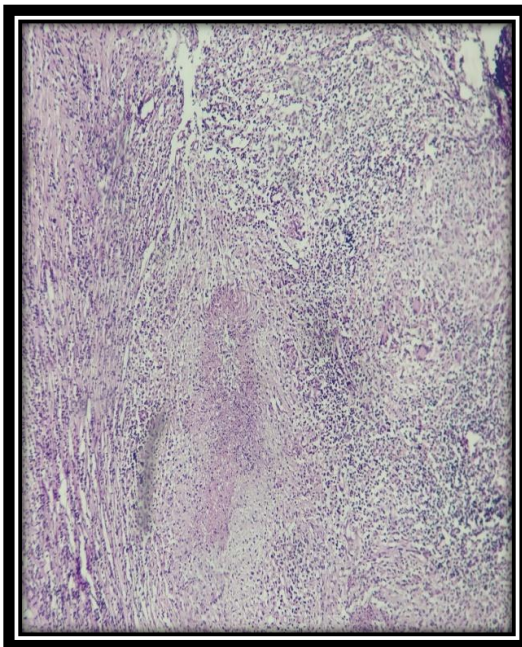
**Fig. 44** – IHC showing Pan CK negativity on histopathology section (400x).



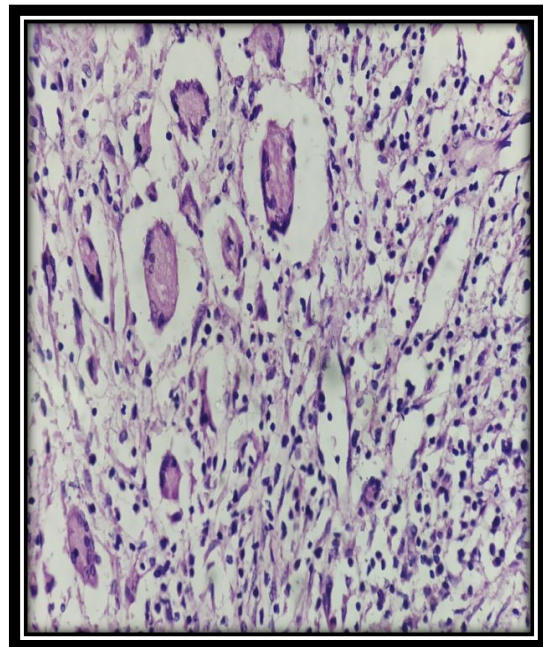
**Fig. 45** - Cytology of reactive inguinal LN (H&E stain, 100x)



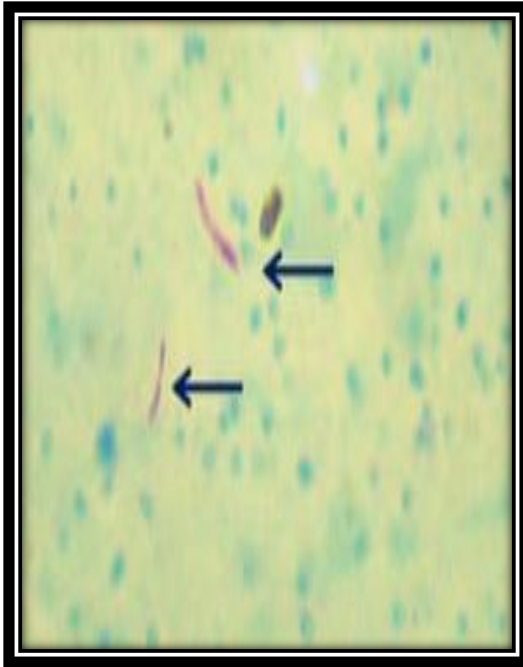
**Fig. 46** - Cytology of reactive inguinal LN (H&E stain, 400x)



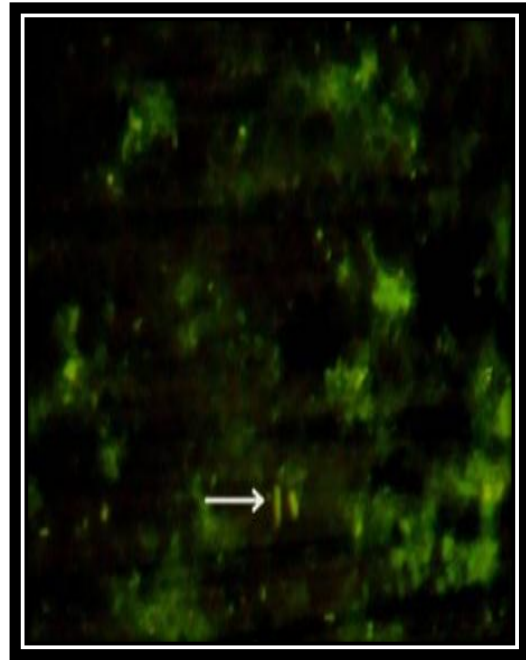
**Fig. 47** - Histopathology of necrotizing granulomatous lymphadenitis suggestive of tuberculosis in inguinal LN (H&E stain, 100x)



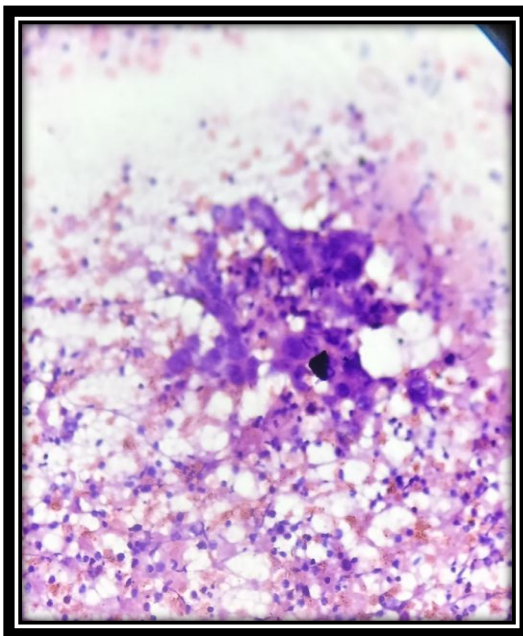
**Fig. 48** - Histopathology of necrotizing granulomatous lymphadenitis suggestive of tuberculosis in inguinal LN (H&E stain, 400x)



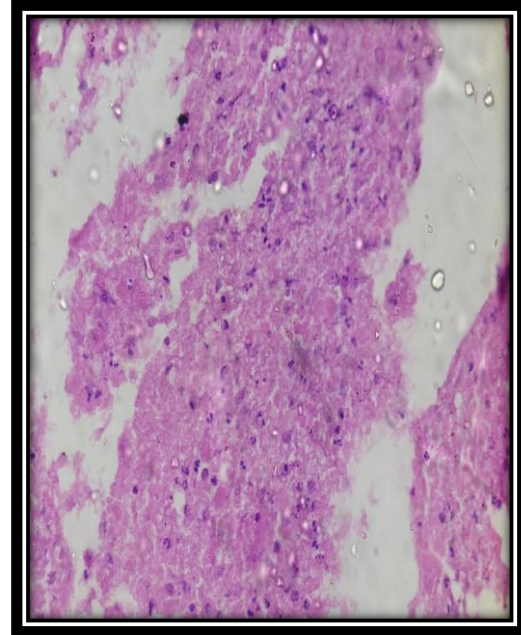
**Fig. 49** – Photomicrograph showing AFB in inguinal LN (Ziehl Neelsen stain,1000x).



**Fig. 50** – Photomicrograph showing AFB in inguinal LN under fluorescence microscope (Auramine O stain, 200x).



**Fig. 51** - Cytology of mets SCC in cervical LN. (Geimsa stain, 400x)



**Fig.52** – Histopathology of acute suppurative lesion – Cell block (H&E stain, 400x)

## DISCUSSION

FNAC has become an essential part of the initial diagnosis and management of patients with metastatic lymphadenopathy due to quick availability of results and its simplicity.

Also utilization of FNAC can avoid the need for excisional biopsy in maximum cases which certainly allows rapid onset of management and treatment of the patient.<sup>42</sup>

FNA cytology not only helps in diagnosing metastatic malignancies but also points towards a possible occult primary site in case of secondary with unknown primary.<sup>16</sup>

In the present study we included 81 clinically suspected cases of metastatic lymph nodes. Out of which 72 cases were reported as metastatic lymph nodes on cytology which amounts to 88.9%.

In the present study age group of the patients ranged from 25 years to 85 years with maximum number of cases in the range of 46-65 years amounting to 56.8%. This finding is correlating to studies conducted by Chakravarty-Vartak US *et al*<sup>4</sup>, Rai NN *et al*<sup>5</sup>, Meena P *et al*<sup>3</sup> and Mehdi G *et al*<sup>76</sup>. In their study age range was 45-54 years, 41-60 years, 51-60 years and 40-69 years respectively.

Median age was 60 yrs in the present study which is similar to study done by Chakravarty-Vartak US *et al*<sup>4</sup> and Ghartimagar D *et al*<sup>77</sup>. In their study also median age was 55.8 years and 60.4 years respectively.

The gender preponderance was found to be skewed towards male having M: F ratio of 2.2: 1 which is similar to numerous studies conducted by authors like Mehdi G *et al*<sup>76</sup> (3.1:1), Mustafa Z *et al*<sup>78</sup> (1.08:1), Meena P *et al*<sup>3</sup> (2.6:1). These authors mentioned

that consumption of smoking, alcohol, tobacco and betel nut chewing is more prevalent in the male population as compared to females leading to oral cavity and upper respiratory malignancy and similar explanation holds true in our study. Study conducted by Ghartimagar D *et al*<sup>77</sup> showed gender preponderance to be inclined towards female having M:F ratio to be 1:1.25. These authors mentioned that this difference can be attributed to various geographic, demographic and lifestyle factors.

In the present study most common lymph node metastasis was observed in cervical lymph node amounting to 40.4% followed by submandibular and axillary lymph node both amounting to 15.5% each. In other studies conducted by various authors cervical lymph node was the most common site of metastatic malignancy varying from 48% to 70%.<sup>3,5,76-78</sup>

However in a study conducted by Chakravarty-Vartak US *et al*<sup>4</sup> submandibular lymph node was the most common site of metastatic lymphadenopathy amounting to 33.6% followed by cervical lymph node (31.7%).

Metastatic squamous cell carcinoma was the commonest cytological diagnosis amounting to 53.1% followed by metastatic infiltrating ductal carcinoma amounting to 14.8% in the present study. In a study done by Rai NN *et al*<sup>5</sup>, Mustafa Z *et al*<sup>78</sup>, Mehdi G *et al*<sup>76</sup>, Meena P *et al*<sup>3</sup> also squamous cell carcinoma was the commonest cytological diagnosis amounting to 45.08%, 51.9%, 53.4% and 76% respectively.

In the present study out of 81 cases diagnosis of primary was possible in 42 cases. Commonest site of primary observed was oral cavity followed by breast. Study conducted by Chakravarty-Vartak US *et al*<sup>4</sup> observed that oral cavity was the most common primary site in their study also amounting to 23.07% (24 out of 104 cases) of cases.

Study undertaken by Mehdi G *et al*<sup>76</sup> observed that the most common primary site was head and neck amounting to 54.2%. Study conducted by Meena P *et al*<sup>3</sup> found aerodigestive tract to be the most common primary site amounting to 60% of cases.

Most common cytological diagnosis in submandibular lymph nodes was given as Mets SCC arising maximally from oral cavity which was in agreement with study conducted by Chakravarty-Vartak US *et al*<sup>4</sup> amounting to 77% arising predominantly from oral cavity.

Axillary lymph node was the second most common site of metastasis in the present study and all cases metastasised from breast were infiltrating ductal carcinoma except one case of invasive lobular carcinoma. Breast carcinoma was the commonest primary site in case of axillary lymph nodes metastasis. Similar findings were observed in studies undertaken by other authors such as Mehdi G *et al*<sup>76</sup>, Patel MM *et al*<sup>74</sup>. In their study axillary lymph nodes metastasis was observed in 13.1% and 8.29% respectively.

**TABLE 16: DISTRIBUTION OF ANATOMICAL SITES OF LYMPH NODES**

<b>Anatomical sites of lymph node</b>	<b>Present study</b>	<b>Chakravarty-Vartak US <i>et al</i><sup>4</sup></b>	<b>Rai NN <i>et al</i><sup>5</sup></b>	<b>Mehdi G <i>et al</i><sup>76</sup></b>	<b>Ghartimagar D <i>et al</i><sup>77</sup></b>
<b>Cervical</b>	40.4%	31.7%	57.0 %	69.2%	48%
<b>Submandibular</b>	15.5%	33.6%	9.7%		
<b>Axillary</b>	15.5%	1.9%	6.7 %	13.1%	12%
<b>Inguinal</b>	11.9%	7.6%	6.4 %	4.8%	7%
<b>Supraclavicular</b>	11.9%	12.5%	12.1 %	10.4%	32%
<b>Submental</b>	2.4%	1.9%	0.7 %		
<b>Posterior auricular</b>	1.2%		0.7 %		
<b>Jugulodiagastric</b>	1.2%		3.7 %		

**TABLE 17: CYTOLOGICAL DIAGNOSIS IN VARIOUS STUDIES**

<b>Cytological diagnosis</b>	<b>Present study</b>	<b>Chakravarty-Vartak US <i>et al</i><sup>4</sup></b>	<b>Rai NN <i>et al</i><sup>5</sup></b>	<b>Mehdi G <i>et al</i><sup>76</sup></b>	<b>Meena P <i>et al</i><sup>3</sup></b>	<b>Gupta A<sup>79</sup></b>	<b>Patel MM <i>et al</i><sup>74</sup></b>
Mets SCC	53.1%	66.34%	45.08%	53.4%	76%	65%	75.15%
Mets IDC/Invasive lobular Ca	14.8%	3.84%	7.46%		10%		8.29%
Mets poorly diff Ca	9.8%	17.30%	3.05%	13.8%	06%	19%	7.64%
Mets adeno Ca	3.8%	5.7%	19.32%	26.7%	05%	12%	1.91%
Mets Adenosquamous Ca	3.8%						
Mets nasopharyngeal Ca	1.2%		0.34%			3%	
Mets follicular Ca	1.2%						
Mets malignant melanoma	1.2%	0.96%	0.34%	0.61%	01%		1.91%

Out of 72 cases of metastatic lymphadenopathy diagnosed on cytology, primary site was suggested in 42 (amounting to 58%) cases by correlating with clinical features. In remaining 30 cases that is 42% primary site was not known. Our findings were in accordance with finding of Mehdi G *et al*<sup>76</sup> where in primary site was suggested in 54.9% of cases. Study conducted by Meena P *et al*<sup>3</sup> suggested primary site in 84% of the cases and this significant discrepancy can be attributed to variation in size and age of study group.

Histopathology correlation was done in 37 cases out of total 81 cases. Cytological diagnosis was correlating in 81% of the cases and was discordant in 19% of cases. Similar correlation was seen in study conducted by Mustafa Z *et al*<sup>78</sup> on a sample size of 54 cases showing concordance on histopathology in 96.23% of cases.

In one case on radiological investigations differential diagnosis of rectal mass/ retroperitoneal mass was given. This case was clinically suspected as metastatic inguinal lymphnode with suspected primary in rectum. On cytology it was reported as metastatic adenocarcinoma which showed features of sarcoma on histopathology. Further IHC study – pancytokeratin was done which was negative. Hence this case was concluded as sarcoma of inguinal region. Further follow was not possible as the patient was lost for follow up. More detailed history of the patient along with relevant investigations could have helped in reaching the correct diagnosis in this case.

One case of suspected SCC of hypopharynx metastatising to cervical lymph node on cytology was reported as metastatic SCC but on histopathology turned out to be acute suppurative lesion. This could be attributed to wrong site of biopsy or sampling from necrotic or inflammatory region.

One case of Mets adenocarcinoma of left supraclavicular lymph node on cytology was reported as Mets SCC on histopathology.

One case suspected as metastasis to left inguinal lymph node was reported as reactive lymphadenitis on cytology and necrotising granulomatous lymphadenitis suggestive of tuberculosis on histopathology. This could be attributed to chances of missing poorly formed granulomas on cytology. This emphasizes thorough examination of all the slides in doubtful cases supplemented with repeat FNAC if required for coming on to an accurate diagnosis.

Similar explanation was mentioned in a study done by Mustafa Z *et al*<sup>78</sup> where in they reported a case of metastatic carcinoma as reactive lymphadenitis.

Three cases reported as poorly diff Ca on cytology were diagnosed as SCC in 2 cases and adenocarcinoma in one case on histopathology.

In a study done by Mustafa Z *et al*<sup>78</sup> also one case was misdiagnosed as metastatic poorly differentiated carcinoma. Later on after performing histopathology and IHC, it turned out to be a malignant lymphoma. This discrepancy can be attributed to poor differentiation of malignant cells which always poses difficulty in being recognized as having an epithelial origin or not.

Similar explanation holds true in present study also. On cell block of these two cases few dyskeratotic cells and occasional keratin pearls were noted. Hence these two cases were concluded as metastatic SCC. In one case mucin material and glandular pattern was observed and based on these findings this case as concluded as metastatic adenocarcinoma.

Sensitivity in the present study was 100% which is similar to study undertaken by Mehdi G *et al*<sup>76</sup> (100%) and these authors mentioned that this may be due to samples selected for the study. In their study they included all cases which were positive for malignancy on cytology and correlated with histopathology. In our study, we have included all cases that were clinically suspected as metastatic lymph node which were further evaluated on cytology and further correlated with histopathology. Hence, sensitivity was 100%.

Specificity in the present study is 50%. In a study done by Mustafa Z *et al*<sup>78</sup> specificity is 93.75%. This could be attributed to the variation in sample size being very less (54) in their study.

Positive predictive value, negative predictive value and accuracy were calculated to be 97.22%, 100% and 97.30% respectively which is in accordance with other workers such as Mustafa Z *et al*<sup>78</sup> and Mehdi G *et al*<sup>76</sup>.

## CONCLUSION

FNAC is an easy, time saving, safe and cost effective diagnostic procedure. It is helpful in detecting secondaries where primary tumour is known as well as for detection of primary in malignancies of unknown origin. It is convenient for both patient and physician in the management and follow up of metastatic lymphadenopathies. It is extremely useful in the early diagnosis of metastatic lymphadenopathy in a resource challenged setting.

Even though FNAC proves to be an excellent diagnostic tool, cytology slides should always be meticulously examined by a trained cytopathologist to avoid any chance of misdiagnosis. Special attention to various morphologic changes may help in arriving to an accurate diagnosis. Repeat FNAC can easily be performed where the initial diagnosis is doubtful and it should always be supplemented with other clinical details and relevant laboratory investigations.<sup>78</sup>

It is therefore concluded that FNAC is a useful diagnostic aid for diagnosing cases of metastatic lymphadenopathy with special reference to detecting primary site.

### **Limitations of the study –**

In our study histopathology correlation was not available in all cases. In some cases it also became difficult to keep a track of patients as they were lost for follow up. In such situations we could not eventually discover the unknown primary sites.

### **Recommendation -**

Hence, complete clinical reevaluation and additional investigations with diagnostic modalities such as CT, MRI, IHC studies will help in prompt and accurate management of the patients presenting with metastatic lymphadenopathy.

## SUMMARY

A prospective study was done on clinically suspected cases of metastatic lymph nodes to evaluate utility of fine needle aspiration cytology in diagnosing clinically suspected cases of metastatic lymph nodes with special reference to primary site. Clinically suspected cases of metastasis to lymph nodes that were referred for FNAC to the Cytology section in the Department of Pathology, B.L.D.E (Deemed to be University) Shri B. M. Patil Medical College, Hospital and Research Centre, Vijayapur were undertaken during the study period of 1st September 2016 –31<sup>st</sup> July 2018

The salient features observed in this study were:–

The study was conducted on 81 clinically suspected cases of metastatic lymph nodes.

The age group of the patients ranged from 25 years to 85 years with maximum number of cases in the range of 46-65 years amounting to 56.8%

The gender preponderance was found to be skewed towards male having M: F ratio of 2.2: 1. Median age was 60 yrs.

In the present study most common lymph node metastasis was observed in cervical lymph node.

Out of 81 clinically suspected cases of metastatic lymphadenopathy in 72 cases diagnosis of metastatic lymphadenopathy was given on cytology. Metastatic squamous cell carcinoma was the commonest cytological diagnosis

Out of 72 cases of metastatic lymphadenopathy diagnosed on cytology, primary site was suggested in 42 (amounting to 58%).

Commonest primary site of malignancy was found to be oral cavity.

Histopathology correlation was done in 37 cases out of total 81 cases. Cytological diagnosis was correlating in 81% of the cases and was discordant in 19% of cases.

It is therefore concluded that FNAC is a safe and efficacious diagnostic tool for diagnosing cases of metastatic lymphadenopathy with special reference to detecting primary site.

## BIBLIOGRAPHY

1. Koss L, Melamed M. Koss' diagnostic cytology and its histopathologic bases. 5<sup>th</sup> ed. Philadelphia: Lippincott Williams & Wilkins; 2006.
2. Bibbo M, Wilbur DC. Comprehensive cytopathology. 3rd ed. China: Saunders Elsevier; 2008.
3. Meena P, Mishra RT. A study of metastatic lesions of lymph nodes by fine needle aspiration cytology. International Journal of Research in Medical Sciences 2017;5(10):4523-6.
4. Chakravarty-Vartak US, Vartak SS, Nichat PB. Metastatic Lymphadenopathy by Fine-needle Aspiration Cytology. International journal of scientific study 2016;4(3):192-6.
5. Rai NN, Patangia P, Meena SP. Role of fine needle aspiration cytology in diagnosis of metastatic lymphadenopathy. J Evid Based Med Healthc 2016; 3(18): 738-741
6. Patel PK, Prasad S, Biswas NK. Analysis of FNAC of Palpable Superficial Lymph Nodes: Our Experience over Three-Year Period. Journal of Dental and Medical Sciences 2016;15(4):20-2.
7. Gayathri MN, Chaurasia S, Bharathi M, Shashidhar HB. Pattern of lymphadenopathy in fine needle aspiration cytology: a retrospective study. International Journal of Research in Medical Sciences 2015;3(6):1416-9.
8. Reddy DL, Venter WD, Pather S. Patterns of lymph node pathology; fine needle aspiration biopsy as an evaluation tool for lymphadenopathy: a retrospective descriptive study conducted at the largest hospital in Africa. PLOS One 2015;10(6):1-10.

9. Sharma P, Rana S, Gill MK, Singh P, Satarkar RN, Kalhan S. Spectrum of lymph node lesions on cytology in rural Haryana: a retrospective analysis. *International Journal of research in Medical sciences* 2015;3(5):1125-30.
10. Mitra P, Bharti R, Pandey MK. Role of fine needle aspiration cytology in head and neck lesions of paediatric age group. *Journal of clinical and diagnostic research* 2013;7(6):1055-8.
11. I Bagwan, S Kane, R Chinoy. Cytologic Evaluation of the Enlarged Neck Node: FNAC Utility in Metastatic Neck Disease. *The Internet Journal of Pathology* 2006;6(2):1-7.
12. Shah PC, Patel CB, Bhagat V, Modi H. Evaluation of peripheral lymphadenopathy by fine needle aspiration cytology: a one year study at tertiary centre *Int J Res Med Sci* 2016;4(1):120-5.
13. Dukare SR, Jadhav DS, Gaikwad AL, Ranka SN, Kale PB, D'costa G. Fine needle aspiration cytology of cervical lymphadenopathy-a study of 510 cases. *Asian J Sci Technol* 2014;5(9):537-40.
14. Chandra K, Kumar P, Pandey S. Cytomorphological evaluation of lymphadenopathy on fine needle aspiration cytology-a hospital based retrospective study. *J of Evolution of Med and Dent Sci* 2014;3(51):11929-38.
15. Valiya LG, Padhariya BB, Baxi SN. Spectrum of FNAC in Palpable Head and Neck Lesions in a Tertiary Care Hospital in Western India- A 2 Years Study. *Journal of Dental and Medical Sciences* 2016;15(6):14-19.
16. Pandey P, Dixit A, Mahajan NC. The diagnostic value of FNAC in assessment of superficial palpable lymph nodes: a study of 395 cases. *Al Ameen J Med Sci* 2013;6(4):320-7.

17. Shilpa G, Nataraju G. Pattern of Lymph Node Diseases in a Tertiary Level Referral Center: a cytological study of 943 cases. *Int J Biol Med Res* 2013;4(3):3448-52.
18. Kochhar A, Duggal G, Singh K, Kochhar S. Spectrum of cytological findings in patients with lymphadenopathy in rural population of South Haryana, India—Experience in a tertiary care hospital. *Internet J pathol* 2012;13(2):1-6
19. Alam K, Maheshwari V, Haider N, Siddiqui F, Jain A, Khan A. Fine needle aspiration cytology (FNAC), a handy tool for metastatic lymphadenopathy. *The Internet Journal of Pathology* 2009;10:1-7.
20. Sharma R, Mathur DR. Fine needle aspiration cytology (FNAC) of palpable lesions of head and neck region. *Int J Cur Res Rev* 2012;4(22):74.
21. Qadri SK, Hamdani NH, Shah P, Lone MI, Baba KM. Profile of lymphadenopathy in Kashmir valley: a cytological study. *Asian Pacific Journal of Cancer Prevention* 2012;13(8):3621-5.
22. Shrivastav A, Shah HA, Agarwal NM, Santwani PM, Srivastava G. Evaluation of peripheral lymphadenopathy by fine needle aspiration cytology: A three year study at tertiary center. *Journal of Dr. NTR University of Health Sciences* 2016;3(2):86-91.
23. Alberto M, Marchevsky, Gupta R, Balzer B. Diagnosis of metastatic neoplasms. *Arch Pathol Lab Med* 2010; 134: 194-206.
24. Attaullah M, Shah W, Pervez SN, Khan S, Jehan S, Rahim S. Cytomorphological pattern of superficial lymphadenopathy. *Gomal Journal of Medical Sciences* 2014;12(4):197-200.
25. Mangal N, Sharma VK, Verma N, Agarwal AK, Sharma SP, Aneja S.

- Ultrasound guided fine needle aspiration cytology in the diagnosis of retroperitoneal masses: A study of 85 cases. *Journal of Cytology* 2009;26(3):97-101.
26. Adoga AA, Silas OA, Nimkur TL. Open cervical lymph node biopsy for head and neck cancers: any benefit? *Head & neck oncology* 2009;1(1):9.
27. Pambuccian SE, Bardales R H. Introduction. In: Rosenthal DL. *Lymph Node Cytopathology*. London: Springer 2011;1-8.
28. Berg J.W. The aspiration biopsy smear. In: Koss L. *Koss' diagnostic cytology and its histopathologic bases*. 1<sup>st</sup> ed. Philadelphia: Lippincott Williams & Wilkins; 1961: p311-21.
29. Greig E.D.W, A.C.H Gray. Note on lymphatic glands in sleeping sickness. *Lancet* 1921; 1570-71
30. Guthrie CG. Gland puncture as a diagnostic measure. *Bull Johns Hopkins Hospital* 1921;32(266):9.
31. Pavlovsky. A Lymph node puncture, your contribution to the diagnostic clinicianurgery of ganglionic disease. *Lopez Bues Aiers* 1934.
32. Zajicek J. Aspiration biopsy cytology. *Lymphology* 1977;10(2):94-101.
33. Pandit AA, Candes FP, Khubchandani SR. Fine needle aspiration cytology of lymph nodes. *Journal of postgraduate medicine* 1987;33(3):134-6.
34. Bazemore AW, Smucker DR. Lymphadenopathy and malignancy. *American family physician* 2002;66(11):2103-10.
35. Rottey S, Petrovic M, Bauters W, Mervillie K, Vanherreweghe E, Bonte KA *et al*. Evaluation of metastatic lymph nodes in head and neck cancer: a comparative study between palpation, ultrasonography, ultrasound-guided

- fine needle aspiration cytology and computed tomography. *Acta Clinica Belgica* 2006;61(5):236-41.
36. Amedee RG, Dhurandhar NR. Fine-needle aspiration biopsy. *The Laryngoscope* 2001;111(9):1551-7.
37. Orell SR, Sterrette GF, Whitaker D. Fine needle aspiration cytology. 4<sup>th</sup> edition. New Delhi: Churchill Livingstone; 2005. p.83-124.
38. Dey P. Diagnostic cytology. 1<sup>st</sup> ed. New Delhi: Jaypee the Health Science Publishers (P) Ltd.; 2015.
39. Cibas ES, Ducatman BS. Cytology: Diagnostic Principles and Clinical Correlates. 3rd ed. China: Saunders Elsevier; 2009.
40. Al Alwan NA, Al hashimi AS, Salman MM, Al Attar EA. Fine needle aspiration cytology versus histopathology in diagnosing lymph node lesions. *Eastern Mediterranean Health journal* 1996;2(2):320-325.
41. Badge SA, Ovhal AG, Azad K, Meshram AT. Study of fine-needle aspiration cytology of lymph node in rural area of Bastar District, Chhattisgarh. *Medical Journal of Dr. DY Patil University* 2017;10:143-8.
42. Hafez NH, Tahoun NS. Reliability of fine needle aspiration cytology (FNAC) as a diagnostic tool in cases of cervical lymphadenopathy. *Journal of the Egyptian National Cancer Institute* 2011;23(3):105-14.
43. Prasad RA, Garg SK, Mukerji PK, Agarwal PK. Role of fine needle aspiration cytology in the diagnosis of lymphadenopathy. *The Indian journal of chest diseases & allied sciences* 1993;35(1):27-9.
44. Wilkinson A R , Mohaore S D, Maimoon S A. FNAC in the diagnosis of lymph node malignancies: A simple and sensitive tool. *Indian J Med Paediatr Oncol* 2012;33(1):21–24.

45. Fletcher D. M. C. Lymphoproliferative disorders. In: Diagnostic Histopathology of Tumors. 4ed. Philadelphia: Elsevier; 2013.p236-37.
46. Cousar JB, Macon WR, McCurley, Swerdlow SH. Lymph nodes. In: Mills SE, Carter D. Sternberg's diagnostic surgical pathology. 5<sup>th</sup> ed. Philadelphia: Lippincott Williams & Wilkins; 2010: p681- 752
47. Vasilj A, Kojić Katović S. Fine-Needle Aspiration Cytology of Head and Neck Lymph Nodes in a Ten-Year Period-Single Center Experience. Acta clinica Croatica 2015;54(3):315-8.
48. Anila KR, Nayak N, George PS, Jayasree K. Utility of fine needle aspiration cytology in evaluation of lymphadenopathy-An audit from a Cancer Centre in South India. Gulf J Oncolog 2015;1(19):50-6.
49. Konar K, Ghosh S, Ghosh T, Bhattacharya S, Sanyal S. Pitfalls in the cytodiagnosis of metastatic squamous cell carcinoma in the head and neck: A retrospective study. Journal of Cytology 2008;25(4):119-122.
50. Prasad S, Mohan N. Efficacy of aspiration cytology in suspected metastatic neck lymph nodes. Int J Med Sci Public Health 2014;3(1):46-48.
51. Ramzy I. Clinical and cytopathology and aspiration biopsy, fundamental principles and practice. USA, Appleton and Lange 1990;481-525.
52. Miliauskas J. lymph nodes. In: Orell SR, Sterrette GF, Whitaker D. Fine needle aspiration cytology of lymph node aspirate.5<sup>th</sup> edition. New Delhi: Churchill Livingstone 2011; 83-124.
53. Frable WJ. Fine needle aspiration biopsy techniques. In Bibbo M, ed.Comprehensive cytopathology, 2nd edn. Philadelphia: W.B. Saunders Company: 1997; 623-624.

54. Gray W, Skoog L, Lowhagen T, Tani E. Diagnostic cytopathology of lymph nodes. 2<sup>nd</sup> ed. Edinburgh: Churchill Livingstone; 2002. p. 481-24.
55. Rosai. J. Lymph nodes. In: Rosai and Ackerman's Surgical pathology. 9<sup>th</sup> ed. Missouri: Elsevier; 2004: p1877-1940.
56. Taylor RC, Shi SR, Barr NJ & Wu N. Techniques of Immunohistochemistry: Principles, Pitfalls & Standardization. In: Dabbs DJ eds. Diagnostic Immunohistochemistry. 2<sup>nd</sup> ed. China: Churchill, livingstone/Elsevier; 2006. p1-37.
57. Kumar V, Abbas AK, Aster JC. Robbins and Cotran Pathologic Basis of Disease. 9th ed. Philadelphia: Elsevier; 2015.
58. Shakeel MK, Daniel MJ, Srinivasan SV, Koliyan R, Kumar JV. Comparative analysis of detecting cervical lymph node metastasis with fine needle aspiration cytology. Journal of natural science, biology, and medicine 2015;6(1):7-9.
59. Konar K, Ghosh S, Ghosh T, Bhattacharya S, Sanyal S. Pitfalls in the cytodiagnosis of metastatic squamous cell carcinoma in the head and neck: A retrospective study. Journal of Cytology 2008;25(4):119-122.
60. Rathod GB, Parmar P. Fine needle aspiration cytology of swellings of head and neck region. Indian J Med Sci 2012 Mar 1;66(3-4):49-54.
61. Rathore H, Jethani N, Pachori G, Bansod P, Kalpana R. Cytomorphology of head and neck lesions: A study in tertiary care hospital. Panacea Journal of Medical Sciences 2015;5(3):145-9.
62. Fernandes H, D'souza CR, Thejaswini BN. The role of fine needle aspiration cytology in palpable head and neck masses. Journal of clinical and diagnostic research 2009;3(5):1719-25.


63. Arakeri S. Prospective Study of Fine Needle Aspiration Cytology of Lymph Nodes of The Head And Neck Region over a 2 Year Period with Histopathological Correlation Indian journal of research 2014;3(2):229-231.
64. Ciatto S, Brancato B, Risso G, Ambrogetti D, Bulgaresi P, Maddau C, Turco P, Houssami N. Accuracy of fine needle aspiration cytology (FNAC) of axillary lymph nodes as a triage test in breast cancer staging. Breast cancer research and treatment 2007;103(1):85-91.
65. Ahmed Z, Kurshid A, Quereshi A, Idress R, Asghar N, Kayani N. Breast Carcinoma grading, estimation of tumour size, axillary lymph node status, staging and Nottingham Prognostic Index scoring on mastectomy specimens. Indian Journal of Pathology and Microbiology 2009;52(4):477-81.
66. Mitra S, Ray S, Mitra PK. Fine needle aspiration cytology of supraclavicular lymph nodes: Our experience over a three-year period. Journal of Cytology 2011; 28(3):108-110.
67. Vanisri HR, Nandini NM, Sunila R. Fine-needle aspiration cytology findings in human immunodeficiency virus lymphadenopathy. Indian Journal of Pathology and Microbiology 2008;51(4):481-484
68. Steel B L, Schwartz M R, Ramzy I. Fine needle aspiration biopsy in the diagnosis of lymphadenopathy in 1103 patients. Role, limitations and analysis of diagnostic pitfalls. Acta Cytol 1995;39:76-81.
69. Rathod KM, Shah SA. A study of metastatic lesion of lymph node by fine needle aspiration cytology. Natl J Community Med 2012;3(4):708-10.

70. Khuraijam SD, Sarkar R, Haldar B, Rasaily N, Khuraijam S, Debnath K. Aspiration cytology of metastatic neck node: A 5-year study. *Journal of Medical Society* 2016;29(3):160-3.
71. Ioachim HL, Medderios LJ. *Lymph node pathology*. 4<sup>th</sup> ed. Philadelphia: Lippincott Williams & Wilkins; 2009. p.590-659.
72. Arunalatha SA. Metastatic malignancies presenting as nodal enlargement. *Stanley Medical Journal* 2015;2(1):19-22.
73. Mohanty R, Wilkinson A. Utility of fine needle aspiration cytology of lymph nodes. *Journal of Dental and Medical Sciences* 2013;8(5):13-8.
74. Patel MM, Italiya SL, Dhandha ZB, Dudhat RB, Kaptan KR, Shah MB *et al.* Study of metastasis in lymph node by fine needle aspiration cytology: our institutional experience. *International Journal of Research in Medical Sciences* 2013;1(4):451-4.
75. Agarwal D, Bansal P, Rani B, Sharma S, Chawla S, Bharat V *et al.* Evaluation of etiology of lymphadenopathy in different age groups using fine needle aspiration cytology: A retrospective study. *The Internet J Pathol* 2010;10(2):1-6.
76. Mehdi G, Singh AK, Hasan M, Ansari HA, Rehman S, Mirza S, Sherwani RK. Cytological evaluation of enlarged lymph nodes in metastatic disease: A hospital-based assessment. *Clinical Cancer Investigation Journal* 2015;4(2):152-7.
77. Ghartimagar D, Ghosh A, Ranabhat S, Shrestha MK, Narasimhan R, Talwar OP. Utility of fine needle aspiration cytology in metastatic lymph nodes. *Journal of Pathology of Nepal* 2011;1(2):92-5.

78. Mustafa Z, Baloch FA, Khalid A. Diagnostic accuracy of fine needle aspiration cytology (FNAC) in metastatic lymphadenopathy. *Int J Pathol* 2015;13(1):7-13.
79. Gupta A. Fine Needle Aspiration Cytology of Metastatic Neck Lymph Nodes: A review of 100 cases. *National Journal of Integrated Research in Medicine* 2013;4(5):76-80.

## ANNEXURE – I

### ETHICAL CLEARANCE CERTIFICATE



B.L.D.E. UNIVERSITY'S  
SHRI.B.M.PATIL MEDICAL COLLEGE, BIJAPUR-586 103  
INSTITUTIONAL ETHICAL COMMITTEE

#### **INSTITUTIONAL ETHICAL CLEARANCE CERTIFICATE**

The Ethical Committee of this college met on 04/10/2016 at 3-00pm to scrutinize the Synopsis of Postgraduate Students of this college from Ethical Clearance point of view. After scrutiny the following original/corrected & revised version synopsis of the Thesis has been accorded Ethical Clearance.

Title "Utility of fine needle aspiration cytology in diagnosis of clinically suspected cases of metastatic lymph nodes"

Name of P.G. student Shikha sharma  
dept of pathology

Name of Guide/Co-investigator Dr Sureshna Arakeri  
Professor in pathology

DR. TEJASWINI VALLABHA  
CHAIRMAN  
INSTITUTIONAL ETHICAL COMMITTEE  
BLDEU'S, SHRI.B.M.PATIL  
MEDICAL COLLEGE, BIJAPUR.

Following documents were placed before E.C. for Scrutinization

- 1) Copy of Synopsis/Research project.
- 2) Copy of informed consent form
- 3) Any other relevant documents.

## ANNEXURE II

### **B.L.D.E.U's SHRI B.M. PATIL MEDICAL COLLEGE, HOSPITAL AND RESEARCH CENTER, VIJAYAPUR - 586103**

#### **RESEARCH INFORMED CONSENT FORM**

I, the undersigned, \_\_\_\_\_, S/O D/O W/O \_\_\_\_\_, aged \_\_\_\_\_ years, ordinarily resident of \_\_\_\_\_ do hereby state/declare that Dr. \_\_\_\_\_ of \_\_\_\_\_ Hospital has examined me thoroughly on \_\_\_\_\_ at \_\_\_\_\_ (place) and it has been explained to me in my own language that I am suffering from \_\_\_\_\_ disease (condition) and this disease/condition mimic following diseases. Further Doctor informed me that he/she is conducting dissertation/research titled \_\_\_\_\_ under the guidance of Dr. \_\_\_\_\_ requesting my participation in the study. Apart from routine treatment procedure, the pre-operative, operative, post-operative and follow-up observations will be utilized for the study as reference data.

Doctor has also informed me that during conduct of this procedure like adverse results may be encountered. Among the above complications most of them are treatable but are not anticipated hence there is chance of aggravation of my condition and in rare circumstances it may prove fatal in spite of anticipated diagnosis and best treatment made available. Further Doctor has informed me that my participation in this study help in evaluation of the results of the study which is useful reference to treatment of other similar cases in near future, and also, I may be benefited in getting relieved of suffering or cure of the disease I am suffering.

The Doctor has also informed me that information given by me, observations made/ photographs/ video graphs taken upon me by the investigator will be kept secret and not assessed by the person other than me or my legal hirer except for academic purposes.

The Doctor did inform me that though my participation is purely voluntary, based on information given by me, I can ask any clarification during the course of treatment / study related to diagnosis, procedure of treatment, result of treatment or prognosis. At the same time, I have been informed that I can withdraw from my participation in this study at any time if I want or the investigator can terminate me from the study at any time from the study but not the procedure of treatment and follow-up unless I request to be discharged.

After understanding the nature of dissertation or research, diagnosis made, mode of treatment, I the undersigned Shri/Smt \_\_\_\_\_ under my full conscious state of mind agree to participate in the said research/dissertation.

Signature of patient:

Signature of doctor:

Witness: 1.

2.

Date:

Place

## **ANNEXURE-III**

### **PROFORMA**

#### **Demographic Details:**

1. NAME:
2. AGE:
3. SEX: M/F
4. OCCUPATION:
5. RESIDENCE:
6. OPD / IPD no.:
7. Lab no./ Ward no.:

#### **Chief complaints:**

#### **History of presenting illness:**

#### **Past history:**

#### **Personal history :**

#### **Treatment history**

#### **Family history:**

#### **General physical examination:**

Built	:	Icterus	:
Pallor	:	Cyanosis:	
Clubbing	:	Edema	:
Lymphadenopathy	:	Generalised / Local	

#### **Vitals:-**

Pulse :	RR:
Temp :	Weight :
BP :	

**Examination of metastatic lymph node:**

Inspection :

Number:

Site:

Size:

Other Findings:

**Systemic examination:**

1. Cardiovascular system
2. Respiratory system
3. Per abdomen Examination
4. Central Nervous System
5. Examination of Breast, Thyroid, Genitourinary System

**Clinical diagnosis:**

**Investigation:**

Hematological investigation:

Biochemical Investigation:

Radiological Investigation:

**Cytology:**

Site of lymph node FNAC :

Adequacy:

Cytomorphological features:

**Impression on cytology:**

Histological Diagnosis (Wherever histopathology sample is available):

Special Investigations (Wherever required):

Cytochemical Staining:

Immunohistochemistry:

Tumour marker assay:

## KEY TO MASTER CHART

Abbreviation	Full form
NO	Number
OP	Outpatient
IP	Inpatient
F	FNAC
Dept	Department
LN	Lymph Node
HPR	Histopathology Report
Y	Years
LAB	Laboratory
ENT	Ear Nose Throat
Surg	Surgery
R	Right
L	Left
C/O	Comprised Of
S/O	Suggestive Of
Mets	Metastasis
SCC	Squamous Cell Carcinoma
cm	Centimeter
IDC	Invasive Ductal Carcinoma
IHC	Immunohistochemistry
Diff	Differentiated
Ca	Carcinoma
Med	Medicine

Ortho	Orthopedics
Dermat	Dermatology
ZN	Zeihl Neelsen
AR	Auramine Rhodamine
NHL	Non Hodgkins Lymphoma
DLBCL	Diffuse Large B Cell Lymphoma
TB	Tuberculosis
FNAC	Fine Needle Aspiration Cytology
K/c/o	Known case of
USGF	Ultrasound guided fine needle aspiration cytology